

tent on the other parts of her body. There were no blisters or ulcers on her skin. The patient was diabetic and had hypertension and she used Aptin® (alprenolol) and Euglucon® (glibenclamid) for medication. After stopping the Euglucon® therapy the lesions disappeared almost completely in 6 weeks and after re-exposure to the same drug, purpura reappeared slowly to its full extent in 6 weeks. After renewed withdrawal of the drug, symptoms disappeared slowly.

The biopsies showed perivasculitis of the upper dermis. The infiltrate consisted predominantly of lymphocytes and to some extent of histiocytes and polymorphonuclear cells; in some areas basal cells of epidermis were degenerated. A direct immunofluorescence (with purified antisera to IgG, IgM, IgA, and C₃) revealed pure linear IgA along the basement membrane zone in both lesional and healthy skin in non-sunexposed areas. This finding was seen similarly after the disappearance of purpura for 6 months. The duodenal biopsy specimen did not show any immunoglobulins. Moreover, the iodine patch test and Trafuril® test made on her arms proved negative. To exclude the possibility of immune-complex vasculitis, histamine was injected into unaffected skin and 10 minutes later a skin biopsy was taken. There were not detectable immunoglobulins in dermal vessels. This method has previously been used to detect early events of immune complex vasculitis (3, 4, 10, 11). Furthermore there were no immune complexes detectable in her peripheral blood.

DISCUSSION

Clinically and histologically the present case resembles an extensive purpura pigmentosa chronica. This seems to be aggravated by an antidiabetic drug, glibenclamid (Euglucon®).

The finding of IgA in the present case along the basement membrane, but not in dermal vessels, is interesting. Besides dermatitis herpetiformis and linear IgA dermatitis there are findings of IgA depositions on the basement membrane in bullous pemphigoid-like diseases (5). In one study, antibody of the IgA class was highly specific for the patient's own skin and it was debated that IgA might play an indirect pathogenic role causing induction of the alternate complement activation pathway (6). Both granular IgA deposits along the basement membrane (2) and band-like linear IgA deposits of the adnexal structures (8) can be detected in normal patients, especially on sun-exposed areas. There were no detectable immune complexes containing IgA circulating in the blood of this patient. The role of persistent linear IgA deposits along the basement membrane zone in non-sun-exposed skin in this patient suffering from purpura remains open and merits further study.

REFERENCES

1. Baart de la Faille-Kuyper, E. H., Kater, L., Kooiker, C. J. & Dorhaut Mees, E. J.: IgA deposits in cutaneous blood-vessel walls and mesangium in Henoch-Schönlein syndrome. *Lancet* *i*: 892, 1973.
2. Blenkinsopp, W. K., Clayton, R. J. & Haffenden, G. P.: Immunoglobulin and complement in normal skin. *J Clin Pathol* *31*: 1143, 1978.
3. Braverman, I. M. & Yen, A.: Demonstration of immune complexes in spontaneous and histamine-induced lesions and in normal skin of patients with leukocytoclastic angitis. *J Invest Dermatol* *64*: 105, 1975.
4. Grover, R. G., Sams, W. M., Jr, Thorne, G. & Glaman, H. N.: Immune complex deposition in leukocytoclastic vasculitis. *J Invest Dermatol* *84*: 393, 1976.
5. Honeyman, J. F., Honeyman, A. R., De la Parra, M. A., Pinto, A. & Eguiguren, G. J.: Polymorphic pemphigoid. *Arch Dermatol* *115*: 423, 1979.
6. van Joost, Th., Faber, W. R., Westerhof, W. & de Mari, F.: Linear dermo-epidermal IgA depositions in bullous pemphigoid. *Acta Dermatovener (Stockholm)* *59*: 463, 1979.
7. Levinsky, R. J. & Barratt, T. M.: IgA immune complexes in Henoch-Schönlein purpura. *Lancet* *ii*: 1100, 1979.
8. Nieboer, C.: Immunofluorescence patterns in sun-exposed and not-sun-exposed skin of healthy individuals. *Acta Dermatovener (Stockholm)* *61*: 471, 1981.
9. Niemi, K. M. & Kangas, K.: Non-thrombocytopenic purpuras. *Acta Dermatovener (Stockholm)* *58*: 337, 1978.
10. Sams, W. M., Jr, Thorne, E. G. & Small, P.: Leukocytoclastic vasculitis. *Arch Dermatol* *112*: 219, 1976.
11. Wolff, H. H., Maciejewski, W., Scherer, R. & Braun-Falco, O.: Immunoelectronmicroscopic examination of early lesions in histamine induced immune complex vasculitis in man. *Br J Dermatol* *99*: 13, 1978.

Nail Bed Immunofluorescence in Pemphigus vulgaris

R. A. Fulton, I. Campbell,¹ D. Carlyle and
N. B. Simpson

*Department of Dermatology, The Royal Infirmary,
Glasgow G4 0SF and ¹Department of Dermatology,
University of Glasgow, Glasgow-Scotland*

Received July 10, 1982

Abstract. A 65-year-old man developed simultaneously pemphigus vulgaris and onychomadesis of his thumb nails. Nail bed biopsy demonstrated supra-basilar acantholysis and intercellular epidermal deposition of IgG and C₃.

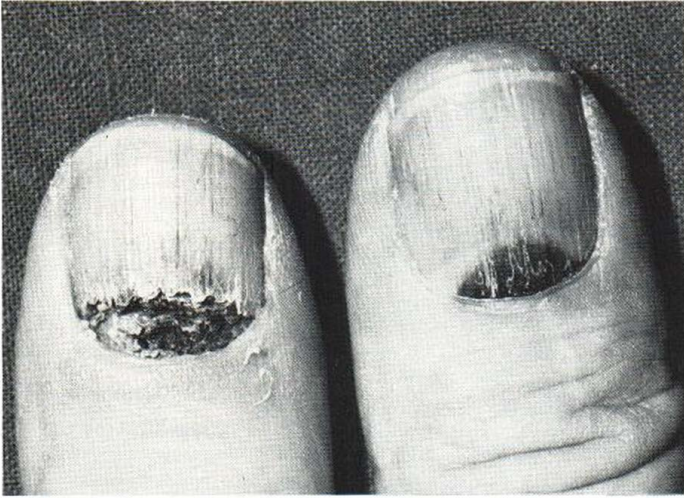

Fig. 1. Lesions of the left and right thumb.

Specific involvement of the nail bed or matrix in pemphigus vulgaris is not a well recognized feature of this disease. We report a patient with pemphigus vulgaris who presented with typical oral and cutaneous lesions. He developed spontaneous shedding of a thumb nail which extended progressively from the posterior nail fold (onychomadesis).

We present the histological and immunological findings, which suggest that this process was due to involvement of the nail bed by pemphigus.

CASE REPORT

A 65-year-old man of Italian descent presented with a 12-week history of painful oral ulceration and crusted lesions on his anterior chest and axillae. At the same time he noticed dark blue discoloration under the proximal ends of both thumb nails, but he did not recall any trauma. On examination, there was extensive severe oral ulceration involving tongue, gingivae, palate and buccal mucosae with crusted lesions on the chest and vegetative lesions in both axillae. There was loss of the proximal nail plate of the left thumb and probable haematoma formation under the proximal nail plate of the right thumb (Fig. 1). The periungual tissues were normal, with no clinical evidence of pemphigus on the fingers or toes.

Biopsy of the oral, chest and axillary lesions showed

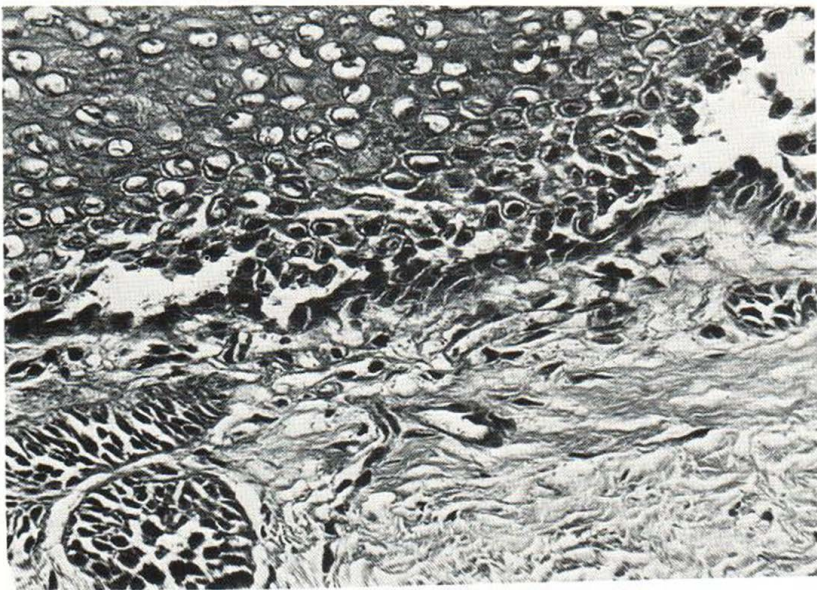


Fig. 2. Intra-epidermal bulla with suprabasal acantholytic cells.

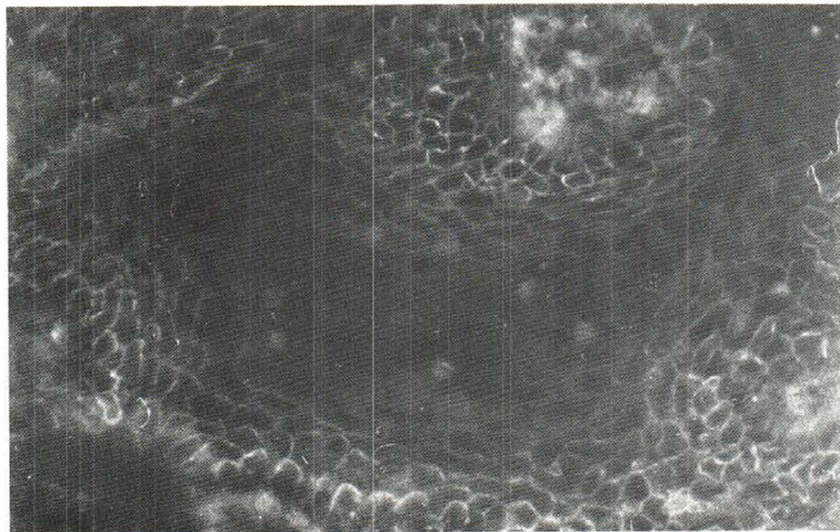


Fig. 3. Direct immunofluorescence showing distinct deposition of epidermal, intercellular IgG and C₃.

suprabasilar acantholysis. Direct immunofluorescence showed clear intercellular epidermal staining with IgG and C₃ at all sites. Circulating intercellular antibody was present to a titre of 1 in 160.

Longitudinal biopsy of the left thumb nail was carried out to include the proximal half of the nail bed, the posterior nail fold and matrix. At the same time, skin for comparison was biopsied from clinically normal skin over the dorsal proximal phalanx of the same thumb. In the nail bed there was an intra-epidermal bulla with suprabasal acantholytic cells (Fig. 2). Direct immunofluorescence showed distinct deposition of epidermal, intercellular IgG and C₃ (Fig. 3). The non-lesional skin from the same finger did not show any histological abnormality and there was no demonstrable deposition of immunoglobulins or C₃.

COMMENT

Nail involvement is rarely mentioned in clinical descriptions of pemphigus vulgaris. Pardo-Castello (3) described several changes, including onychomadesis. Parameswara & Naik (2) reported a patient with widespread onychomadesis appearing shortly after the onset of cutaneous and oral pemphigus vulgaris. These authors suggested that nail separation may have been due to bullous lesions in the nail matrix as part of the disease process, though they did not confirm this by histological examination. Bauml & Robinson (1) described a patient who had been treated with corticosteroids for pemphigus vulgaris for at least 13 years. He then developed separation of the nail plate of a great toe and histology showed intra-epidermal acantholysis of the nail bed. Our patient developed ony-

chomadesis at the same time as his cutaneous and oral lesions.

We have shown that the nail bed was involved in an acantholytic process. In addition, we have demonstrated epidermal intercellular deposition of IgG and C₃ in the nail bed, which we believe is the first report of the characteristic immunofluorescence findings in pemphigus at this site. This immunofluorescence pattern is a very reliable diagnostic test for pemphigus vulgaris and the intercellular antibodies are involved in the production of acantholysis. The absence of immunofluorescence in the adjacent non-lesional skin suggests that IgG and C₃ were deposited specifically in the affected nail bed although we are aware that clinically normal skin in pemphigus may show intercellular deposition of immunoglobulin. Our findings suggest that onychomadesis in pemphigus is due to direct involvement of the nail bed by the disease process.

ACKNOWLEDGEMENTS

We are grateful to Dr C. Scully for referring the patient and to Professor Rona MacKie and Dr A. McQueen for reporting the histology and immunofluorescence.

REFERENCES

1. Bauml, A. & Robinson, M.: Nail bed involvement in pemphigus vulgaris. *Arch Dermatol* 107: 751, 1973.
2. Parameswara, Y. & Naik, R.: Onychomadesis associated with pemphigus vulgaris. *Arch Dermatol* 117: 759, 1981.
3. Pardo-Castello, V.: *Diseases of the Nails*, 3rd ed., 177 pp. Charles C. Thomas, Springfield, Ill., USA, 1960.