

LINEAR IgA DERMATOSIS: A STUDY OF TEN ADULT PATIENTS*

H. Mobacken,¹ W. Kastrup,¹ K. Ljunghall,³ H. Löfberg,⁴
L.-Å. Nilsson,² Å. Svensson⁵ and U. Tjernlund⁴

¹Department of Dermatology, and ²Department of Clinical Immunology, Institute of Medical Microbiology, University of Göteborg, and Departments of Dermatology at ³Uppsala University, Uppsala, ⁴General Hospital, Malmö and ⁵Central Hospital, Kristianstad, Sweden

Abstract. Ten adult patients with homogeneous-linear deposition of IgA along the basement membrane zone have been studied. The direct immunofluorescence IgA pattern was stable, and there was no deposition of IgG or IgM. The clinical presentations were heterogeneous and resembled dermatitis herpetiformis (DH) (3 cases) or bullous pemphigoid (5 cases). Two patients had widespread gyrate blistering lesions of acute onset. Pruritus was constantly present. The course of the disease was chronic except for one patient who had a spontaneous remission after 5 years. The histology was indistinguishable from "classical" DH with granular IgA in dermal papillae. The patients studied in the present investigation did not show the high incidence of atrophic intestinal villi found in "classical" DH. Five of 9 cases carried the haplotype HLA-A1, B8, DR3. In spite of a close similarity between linear IgA dermatosis and DH, differences exist which indicate discrepancies in etiopathogenesis.

Key words: Dermatitis herpetiformis; Pemphigoid Linear IgA; Immunofluorescence; Coeliac disease; Tissue typing

Over the last few years the demonstration of granular IgA deposits in the papillary tips of normal or perilesional skin has become almost generally accepted as the most reliable single criterion for dermatitis herpetiformis (DH) (6, 11). DH patients also often have a concomitant gluten-sensitive enteropathy (GSE) and an increased incidence of the haplotype HLA-B8, DR3 (11). However, a minority of patients, with prevalences ranging from 0 to 26% of all DH patients (mean 15%) exhibit a band-like pattern of IgA along the basement membrane zone (BMZ) (2, 8, 11, 21). The nature of the disease characterized by linear IgA deposition is still unclear.

Firstly, the clinical presentation and response to dapsone has been reported by Chorzelski et al. (4) to differ in the two groups, whereas Lawley et al. (13) did not find any difference. Secondly, GSE has been found to be absent or rare in patients with linear IgA pattern (4, 13). Thirdly, the incidence of

the haplotype HLA-B8, DR3 may differ in the two groups (11, 13). It has therefore been suggested that these patients represent a distinct entity, or are more closely related to DH or bullous pemphigoid (BP) (4, 9, 10, 13, 17). The nosological speculations are reflected in the different names (e.g. Linear IgA bullous dermatosis, Mixed or Intermediate form of DH and BP) attributed to the condition. Small series of patients and differences in the interpretation of the immunological findings may explain some of the conflicting opinions.

The purpose of the present study was to report the clinical, histopathological and laboratory findings in 10 adult patients with homogeneous-linear deposition of IgA at the BMZ.

PATIENTS AND METHODS

Patients

The patient material was collected from the departments of dermatology at Sahlgren's Hospital in Gothenburg, the University Hospital in Uppsala, the General Hospital in Malmö and the Central Hospital in Kristianstad. In these hospitals biopsies for direct immunofluorescence (IF) are taken routinely from normal and perilesional skin in all patients with a clinically suspected bullous dermatosis. The criteria for inclusion in this study were: 1) clinical lesions of a blistering disorder, 2) adult onset of the disease, 3) homogeneous (not granular or fibrillar) linear deposition of IgA along the BMZ in normal or perilesional skin on two or more occasions.

Clinical pictures

The clinical characteristics were registered and histopathological slides were evaluated.

Gastro-intestinal tract

Gastric acid secretion was investigated by a pentagastrin test (19). Small bowel mucosal biopsies were taken either endoscopically from the second part of the duodenum or as a capsule biopsy from the duodenojejunal junction (7). Serum gluten antibodies were assayed by a diffusion-in-

* Read at the annual meeting of the Swedish Dermatological Association, Kristianstad, May 1981.

Table 1.

Patient	Sex	Age at onset	Clinical picture	Pos. direct IF (IgA) periles. skin	normal skin	HLA	Gluten-sensit. enteropathy	Treatment	Associated diseases
S. O.	M	27	BP-like	2/4	0/5	A2, 28; B12, 18; DR2	No	Dapsone (slow effect)	Atopic eczema + rhinitis allerg. + urolithiasis
H. S.	M	71	BP-like	1/1	1/5	A3, 9, B5, w35; Cw4; DR1, 2	NS	Dapsone	Ulcer duodeni + essent. hypertonia
M. W.	F	44	BP-like	1/2	2/5	A1, 2; B8, 18; DR3	No	Dapsone (slow effect)	0
A. A.	F	74	BP-like	2/2	1/1	A25, 29; B12, 18; Cw6; DR1, 2	No	Dapsone + azathioprin	Mammary carcinoma + gastric lymphoma
M. P.	M	57	BP-like	4/4	3/3	A1, 25; B8; DR3	No	Dapsone + prednisolone	Gastric hypochlorhydria
N. P.	M	34	DH-like	0/2	3/6	NS	NS	Dapsone (slow effect)	Deceased (cerebral thrombosis)
L. E.	M	25	DH-like	NS	4/4	A1; B8; DR3	Yes	Dapsone initially, now GFD	Ulcerating proctocolitis
G. C.	M	75	DH-like	4/4	4/4	A1, 2; B8, 40; Cw3; DR3, 4	No	Dapsone	Polycythemia
R. J.	M	34	Acute gyrate blisters	2/2	5/5	A1, 26; B7, 8; DR2, 3	No	Dapsone	Ethylismus chron.
M. H-J.	F	30	Acute gyrate blisters	2/3	3/3	Aw24, 11; B7, w39; DR2	No	Unsatisfactory dapsone response	Atopic dermatitis

NS = not studied.

gel enzyme-linked immunoassay with gliadin as antigen (20). Serum gastrin was analysed by a radioimmunoassay (19).

Tissue typing

HLA-ABC typing was performed *ad modum* Kissmeyer-Nielsen & Kjerbye, with highly selected antisera (12). HLA-DR typing was performed using the NIH technique with at least two antisera defining HLA-DR1, 2, 3, 4 and 7.

Direct immunofluorescence

Skin biopsies from normal skin and skin lesions were quick-frozen in isopentane at -70°C or preserved in a transport medium as described by Michel (14) one day before freezing. Cryostat sections were incubated with fluorescein-labelled antibodies (rabbit anti-human IgG, IgA, IgM and C3, from DAKO Immunoglobulins Ltd, Denmark) diluted to a protein concentration of 0.2 mg ml^{-1} . The F/P ratio of all conjugates was 2.3. The test was performed according to the principles described by Beutner et al. (1).

Indirect immunofluorescence

Sera were tested on cryostat sections of monkey oesophagus for detecting circulating antibodies against the

BMZ, and of rat liver for detecting anti-nuclear antibodies (1). In addition, sera from 4 patients were tested on normal human skin.

RESULTS

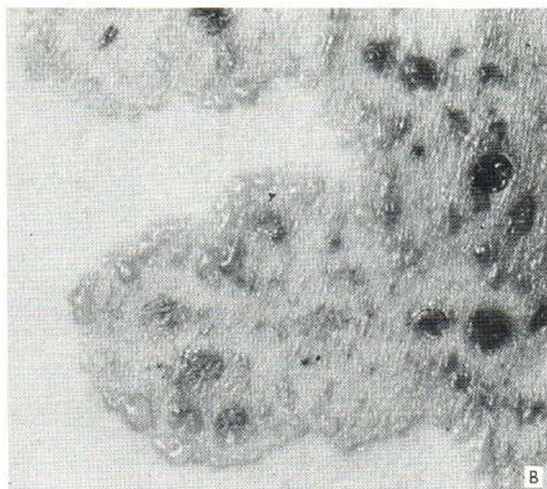
Patients

Ten patients (7 males) satisfied the inclusion criteria (Table 1). Their mean age at onset was 46 years (range 25–75), and the mean time of observation was 10 years (range 3 months – 30 years).

Previous and concomitant disorders. One 75-year-old male remembered having had transient blisters at about 15 years of age. None of the other patients admitted preceding blistering diseases. Two patients had atopic diseases (atopic dermatitis; allergic rhinitis + atopic dermatitis). Two patients had been treated for neoplastic disorders (polycythemia rubra vera; mammary carcinoma and a malignant gastric lymphoma of histiocytic type). One man had coeliac disease in combination with ulcerative colitis. One man died after a cerebral

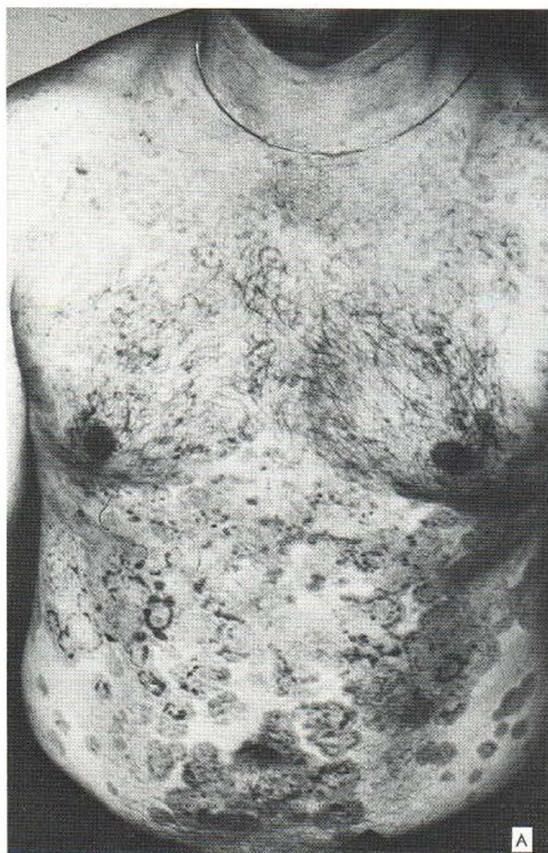

Fig. 1. Case R. J. (A) Acute, widespread gyrate itching eruption, mainly on the trunk. (B) Close-up photograph of peripheral blisters.



thrombosis during the observation period of this study.

Clinical picture. All patients had itching lesions. The lesions had a morphology and distribution characteristic of DH in 3 cases. One of these patients demonstrated urticarial lesions. Five patients had localized or disseminated vesicles and bullae reminiscent of BP (face + neck, 2; face + oral and genital mucosal membranes, 1; legs, 1; disseminated, large BP-like bullae, 1). Two patients suffered from suddenly developing, large, annular, red, confluent lesions mainly on the trunk with peripheral blisters (Fig. 1). Oral lesions occurred in 2 cases. Scarring was never observed.

Histopathology. At least two skin biopsies from each patient were examined. Subepidermal blisters and neutrophilic papillary microabscesses were found in one or more specimens from all the patients. The number of eosinophils in the upper der-

mis varied intra- and inter-individually. Histopathologically the patients with homogeneous-linear deposition of IgA did not differ from those with granular, papillary deposition ("classical" DH).

Immunofluorescence. A band-like, homogeneous-linear deposition of IgA along the BMZ was found in at least two biopsies from each patient (Fig. 2). The results of all biopsies are presented in Table II. Biopsies of perilesional skin were more frequently positive than those of normal skin. IgG and IgM were never found, nor was there a granular-linear (non-continuous) pattern of IgA along the BMZ or in the papillary tips. Serum antibodies to the BMZ were not found in 9 patients studied, and anti-nuclear antibodies were not found in 8 investigated patients.

Response to dapsone. Seven patients responded with clinical improvement to dapsone, whereas 3 did not. Onset of relief was slow, however, in 3 of the 7 cases. One patient experienced recurrences of new, itching vesicles in spite of 200 mg dapsone daily. One patient required a combination of dapsone and prednisolone and one required dapsone and azathioprin in order to control the lesions (Table 1).

Upper gastro-intestinal tract. Six patients were studied with the pentagastrin test. A reduced secretion of gastric hydrochloric acid was found in one patient with a maximal output of 0.8 mmol/h. This patient also had an increased serum concentration of 240 ng gastrin/l (normal value <160).

Intestinal biopsies were obtained in 8 cases. A

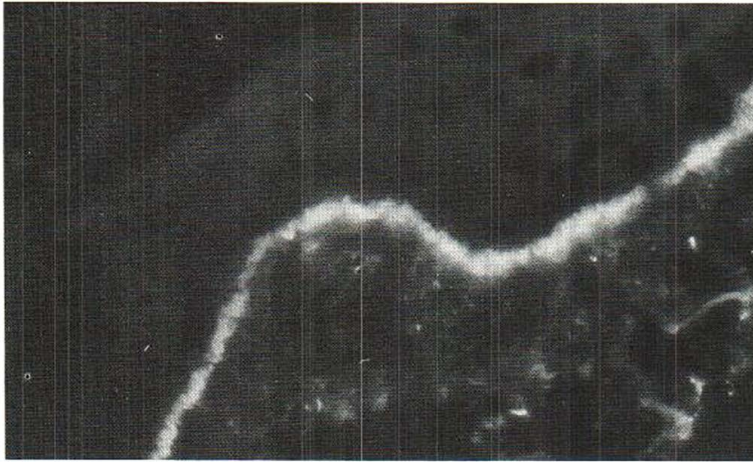


Fig. 2. Direct immunofluorescence staining of a skin biopsy demonstrating a homogeneous-linear deposition of IgA along the basement membrane zone.

subtotal villous atrophy was found in one man. The other 7 patients investigated had normal villi visualized under the dissection microscope as well as in fixed and stained specimens. When gluten-free diet (GFD) was introduced the mucosa of the man with subtotal villous atrophy reverted to normal, but the atrophic villi re-appeared when an ordinary diet was re-instituted. He is now on a chronic GFD and has been able to discontinue dapsone treatment. This was the only patient who demonstrated antibodies against gluten (in a low IgG titre).

Tissue typing. The haplotype HLA-A1, B8, DR3 occurred in 5 of 9 patients studied (Table I).

Prognosis. A spontaneous remission, which occurred 5 years after the onset of the skin symptoms, was seen only in one of the 10 patients.

Prevalence. At the four participating centres, serving about one million of people, all patients with bullous diseases were studied with direct IF. The prevalence of patients with a homogeneous-linear deposition of IgA expressed as a ratio of all patients with "classical" DH was 5% (10/217).

DISCUSSION

Clinical, histological and recently immunological studies have permitted the separation of most bullous disorders into distinct disease entities. However, the precise classification of dermatoses with clinical characteristics of both DH and BP is made difficult by the confusing terminology of the immunopathological findings. Besides the continuous, homogeneous-linear pattern of IgA, "linear IgA" is

sometimes used in a widened concept to denote also a discontinuous, granular, or fibrillar deposition of IgA along the BMZ (Fig. 3). A distinction between these two patterns has not regularly been made, which may explain some of the conflicting results reported.

In an unpublished investigation we re-biopsied 3 patients (not included in this report) with a clinical picture characteristic of DH but with a granular-linear pattern of IgA along the BMZ (Fig. 3). When 2-3 new biopsies were examined the conventional papillary pattern of "classical" DH with concentration of granular IgA to the dermal papillary tips could be demonstrated in all patients. Therefore, the widened concept of "Linear IgA" must be called in question and it is proposed that only patients with a homogeneous-linear pattern of IgA be called "Linear IgA". This pattern may also occur infrequently in BP and cicatricial pemphigoid, but then concurrently with IgG (3).

We selected for the present study only patients

Table II. Immunofluorescence findings in repeated skin biopsies during the observation period of 10 patients with homogeneous-linear deposition of IgA along the basal membrane zone

	Peri-lesional skin	Normal skin
No. of biopsies	24	41
Basal membrane zone		
Homogeneous IgA	18 (75%)	26 (63%)
C3	9 (38%)	3 (7%)

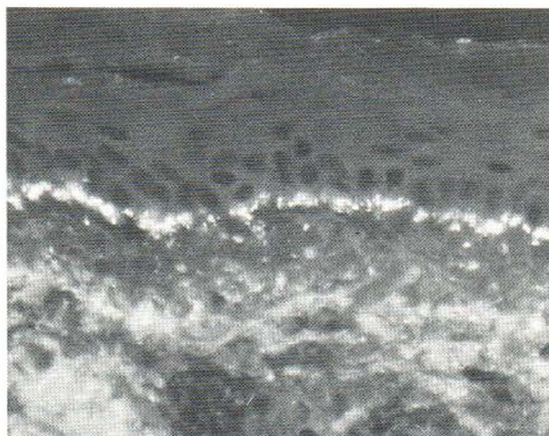


Fig. 3. Granular-linear pattern of IgA at the dermo-epidermal junction.

with homogeneous-linear deposition of IgA along the BMZ. This pattern of deposition and type of immunoglobulin turned out to be remarkably stable. Approximately six biopsies were taken from each patient during $\frac{1}{2}$ –5 years, but in none of these was either a granular-linear pattern of IgA or a papillary one seen. In addition IgA was the only class of immunoglobulin found in positive biopsies. Circulating antibodies against the BMZ were not found. However, normal human skin was used as substrate in only 4 of the patients. By using this substrate, circulating BMZ antibodies of IgA class have earlier been reported in 3 of 7 cases with linear IgA deposits (15, 23).

Clinically, our 10 patients constituted a heterogeneous group. An appearance consistent with DH was seen in 3 and with BP in 5 patients (Table I+III). Widespread gyrate and rosette-like blistering lesions occurred in 2 cases. The BP-like patients differed from the others by having linear IgA deposits less frequently in normal than in perilesional skin (χ^2 , $p < 0.05$). It was unlikely, however, that they had a genuine BP, since IgG could never be detected in spite of several biopsies over a long time, and none of them had circulating IgG autoantibodies to the BMZ.

Neither the histopathological findings nor tissue typing permitted any discrimination between the 10 patients with homogeneous-linear IgA pattern and patients with "classical" DH. The occurrence of HLA-B8, DR3 (55%) was intermediate between that of healthy controls (20–30%) and of "classical" DH (70–85%) (11, 16). The number of cases was

small, however, and no conclusions can be drawn.

Abnormal small intestinal villi were found in only 1 of 8 patients, in whom an unequivocal diagnosis of GSE was established, on the basis of 3 intestinal biopsies. The prevalence of partial and subtotal villous atrophy is statistically significantly lower (Fisher's exact test, $p < 0.01$) than we have found earlier in a larger series of patients with "classical" DH (31/48) (7). This might be of practical importance for the therapeutical approach, arguing against a GFD in patients with the homogeneous-linear IgA pattern. It cannot be excluded, however, that the other patients have minimal mucosal involvement, e.g. overt only after several biopsies or after massive gluten provocation. It should also be noted that GFD has been shown to cause clearing of the skin symptoms in some patients with "classical" DH but with a normal (single) intestinal biopsy (18). This question will have to be settled by dietary trials.

The prevalence of antrum-sparing atrophic gastritis is increased in patients with "classical" DH (19). Its probable occurrence in one elderly man in this study might be a chance association, because of the paucity of studied patients.

Ultrastructurally, patients with "Linear IgA dermatosis" have been reported to demonstrate immunoreactants in lamina lucida or on the anchoring fibrils when examined with immunoelectron microscopic technique (5, 22). No such investigations were performed in this study, however.

To summarize, the patients with the homogeneous-linear IgA pattern differ from "classical" DH by having a heterogeneous clinical picture and usu-

Table III. Clinical and laboratory features of 10 patients with linear IgA dermatosis (positive/studied)

	Bullous pemphigoid-like	D. herpetiformis-like	Acute type
♂/♀	3/2	3/0	1/1
Mean age (y.)	55	45	32
Linear IgA (pos/total biopsies)			
Perilesionally	10/13	4/6	4/5
Normal skin	7/19	11/14	8/8
HLA-A1, B8, DR3	1/5	2/2	1/2
Glutensensitive enteropathy	0/4	1/2	0/2
Delayed or insufficient response to dapsone	4/5	1/3	1/2

ally normal findings in the small bowel biopsy. The exact relationship to DH and BP remains unclear. Until more is known, we suggest that the term Linear IgA dermatosis should be retained for this group of patients, rather than coining new names.

ACKNOWLEDGEMENT

The histological slides were re-examined by H. Gisslén, M.D., Dept of Dermatology, Västra Frölunda Hospital, Göteborg. Tissue typing was performed by L. Sandberg, M.D., the Tissue Typing Laboratory, Sahlgren's Hospital, and J. Säfwenberg, M.D., University of Uppsala, Uppsala.

ADDENDUM IN PROOF

A multi-centre study of Linear IgA disease in adults was recently published by J. N. Leonard et al. (*Br J Dermatol* 107: 301, 1982).

REFERENCES

1. Beutner, E. H., Chorzelski, T. P. & Bean, S. F. (eds): *Immunopathology of the Skin*, 2nd ed. Wiley, New York, Chichester, Brisbane, Toronto, 1979.
2. Chorzelski, T. P., Beutner, E. H., Jablonska, S., Blaszczyk, M. & Triftshauser, C.: Immunofluorescence studies in the diagnosis of dermatitis herpetiformis and its differentiation from bullous pemphigoid. *J Invest Dermatol* 56: 373, 1971.
3. Chorzelski, T. P., Jablonska, S. & Beutner, E. H.: Pemphigoid. *In Immunopathology of the Skin*, (ed. E. H. Beutner, T. P. Chorzelski & S. F. Bean), 2nd ed., p. 243. Wiley, New York, Chichester, Brisbane, Toronto, 1979.
4. — Adult form of linear IgA bullous dermatosis. *In Immunopathology of the Skin*, 2nd ed., p. 316. Wiley, New York, Chichester, Brisbane, Toronto, 1979.
5. Dabrowski, J., Chorzelski, T. P., Jablonska, S., Krainska, T. & Jarzabek-Chorzelska, M.: Immunoelectron microscopic studies in IgA linear dermatosis. *Arch Dermatol Res* 265: 289, 1979.
6. Fry, L. & Seah, P. P.: Dermatitis herpetiformis: an evaluation of diagnostic criteria. *Br J Dermatol* 90: 137, 1974.
7. Gillberg, R., Kastrup, W., Mobacken, H., Stockbrügger, R. & Åhrén, C.: Endoscopic duodenal biopsy compared to biopsy with the Watson capsule from the upper jejunum in patients with dermatitis herpetiformis. *Scand J Gastroenterol* 17: 305, 1982.
8. Holubar, K., Doralt, M. & Eggert, G.: Immunofluorescence patterns in dermatitis herpetiformis. Investigations on skin and intestinal mucosa. *Br J Dermatol* 85: 505, 1971.
9. Honeyman, J. F., Honeyman, A. R., De la Parra, M. A., Pinto, A. & Eguiguren, G. J.: Polymorphic pemphigoid. *Arch Dermatol* 115: 423, 1979.

10. Jablonska, S., Chorzelski, T. P., Beutner, E., Maciejowska, E. & Rzeska, G.: Dermatitis herpetiformis and bullous pemphigoid. Intermediate and mixed forms. *Arch Dermatol* 112: 45, 1976.
11. Katz, S. I.: Dermatitis herpetiformis. *In Immunodermatology* (ed. R. Good & B. Safai), p. 377. Plenum Medical Books, New York and London, 1981.
12. Kissmeyer-Nielsen, F. & Kjerbye, K. E.: Lymphocytotoxic microtechnique. Purification of lymphocytes by flotation. *In Histocompatibility Testing*, p. 381. Munksgaard, Copenhagen, 1967.
13. Lawley, T. J., Strober, W., Yaoita, H. & Katz, S. I.: Small intestinal biopsies and HLA types in dermatitis herpetiformis patients with granular and linear IgA skin deposits. *J Invest Dermatol* 74: 9, 1980.
14. Michel, B., Milner, Y. & David K.: Preservation of tissue-fixed immunoglobulins in skin biopsies of patients with lupus erythematosus and bullous diseases—preliminary report. *J Invest Dermatol* 59: 449, 1972.
15. Pehamberger, H., Konrad, K. & Holubar, K.: Circulating IgA anti-basement membrane antibodies in linear dermatitis herpetiformis (Dühring): immunofluorescence and immunoelectronmicroscopic studies. *J Invest Dermatol* 69: 490, 1977.
16. Pehamberger, H., Holubar, K. & Mayr, W. R.: HLA-DR3 in dermatitis herpetiformis. *Br J Dermatol* 104: 321, 1981.
17. Provost, T. T., Maize, J. C., Ahmed, A. R., Strauss, J. S. & Dobson, R. L.: Unusual subepidermal bullous diseases with immunologic features of bullous pemphigoid. *Arch Dermatol* 115: 156, 1979.
18. Reunala, T., Blomqvist, K., Tarpila, S., Halme, H. & Kangas, K.: Gluten-free diet in dermatitis herpetiformis. I. Clinical response of skin lesions in 81 patients. *Br J Dermatol* 97: 473, 1977.
19. Stockbrügger, R., Anderson, H., Gillberg, R., Kastrup, W., Lundqvist, G. & Mobacken, H.: Auto-immune atrophic gastritis in patients with dermatitis herpetiformis. *Acta Dermatovener (Stockholm)* 56: 111, 1976.
20. Kilander, A. F., Dotevall, G., Fällström, S. P., Gillberg, R. E., Nilsson, L.-Å. & Tarkowski, A.: Evaluation of gliadin antibodies for detection of coeliac disease. *Scand J Gastroenterol*. In press.
21. Van der Meer, J. B.: Granular deposits of immunoglobulins in the skin of patients with dermatitis herpetiformis. An immunofluorescent study. *Br J Dermatol* 81: 493, 1969.
22. Yaoita, H. & Katz, S. I.: Immunoelectronmicroscopic localization of IgA in skin of patients with dermatitis herpetiformis. *J Invest Dermatol* 67: 502, 1976.
23. — Circulating IgA anti-basement membrane zone antibodies in dermatitis herpetiformis. *J Invest Dermatol* 69: 558, 1977.

Received June 8, 1982

H. Mobacken, M.D.
Department of Dermatology
Sahlgren's Hospital
S-413 45 Gothenburg
Sweden