

principal metabolite. Excretion is predominantly via the kidney where 50% of a daily dose is recovered as arabinosylhypoxanthine and 2% as adenine arabinoside. It penetrates the blood-brain barrier to give a CSF/plasma ratio of approximately 1:3 (1).

Adenine arabinoside must be given intravenously in isotonic glucose, which must be buffered beforehand with sodium phosphate to increase the pH of the solution to more than 4.5. The drug has a low solubility and the solution must therefore be kept in a 37°C water bath until it is clear, usually for one hour. It is stable at room temperature for at least 24 hours. To avoid non-solubilized microcrystals of the drug to enter the blood a 0.3 µm filter is mounted at the infusion-set.

We observed no side effects from the treatment.

#### Laboratory findings

Standard laboratory investigations gave normal results. Immunological studies showed a herpes virus titre of 120 (5th day of disease) which increased to 480 (15th day of disease). The total amount of IgE was increased (more than 1000 IU/ml). The percentage of T lymphocytes in blood was within normal limits and the *in vitro* reactivity of lymphocytes following stimulation with various mitogens (PHA, Con A, PWM, PPD) was normal. The patient's serum did not contain factors which could suppress the *in vitro* reactivity of normal lymphocytes.

#### DISCUSSION

Until now the only possible treatment for KVE has been supportive, with management of secondary bacterial infection and maintenance of fluid and electrolyte balance. Several new anti-viral drugs may be of beneficial use in KVE in order to shorten this often severe and distressful disease and to prevent a fatal outcome. Adenine arabinoside has been effective in herpes simplex encephalitis (4). In herpes encephalitis it is of the greatest importance that treatment is started as early as possible (4).

Our patient experienced an uneventful recovery from her KVE. Fever, malaise and psychological disturbances, which were not due to encephalitis, but regarded as symptoms of a reactive psychosis, subsided within 2 days of initiating the therapy. However, her skin lesions of KVE persisted for 14 days (see figures).

In order to evaluate the possible effects of the treatment, we have retrospectively recorded the duration of disease in 8 patients with KVE, who were admitted to our department. We found a mean age of 24 years. The period from the first recorded vesicular eruption until clearing of the skin was 14 days (range 10–19 days). Thus, we have no clear indication that the specific anti-viral treatment shortened the duration of disease in our patient. It is

impossible to say whether her fairly rapid general improvement could have been attributable to adenine arabinoside and transfer factor.

However, we would like to draw the attention of dermatologists to the possible benefits of specific anti-viral treatment in patients suffering from severe KVE. The drug must be given as early as possible, maybe even on mere suspicion of KVE.

#### ACKNOWLEDGEMENT

We wish to thank Mrs Margareta Sommer for her skilful secretarial assistance.

#### REFERENCES

1. Hirsch, M. S. & Swartz, M. N.: Antiviral agents. *N Engl J Med* 302: 903, 1980.
2. Shannon, W. M.: Adenine arabinoside: Antiviral activity *in vitro*. In *Adenine Arabinoside: An Antiviral Agent* (ed. D. Pavan-Langston, R. A. Cuchanan & C. A. Alford, Jr), pp. 1–43. Raven Press, New York, 1975.
3. Thestrup-Pedersen, K., Grunnet, E. & Zachariae, H.: Transfer factor therapy in mycosis fungoides: A double-blind study. *Acta Dermatovener (Stockholm)* 62: 47, 1982.
4. Whitley, R. J. et al.: Adenine arabinoside therapy of biopsy-proved herpes simplex encephalitis. *N Engl J Med* 297: 289, 1977.

### Ketoconazole in a Case of Chronic Mucocutaneous Candidiasis

Hugh Zachariae, Grete Laurberg and Kristian Thestrup-Pedersen

Department of Dermatology, University of Aarhus, Marselisborg Hospital, DK-8000 Aarhus C, Denmark

Received April 10, 1981

**Abstract.** An 8-year-old girl with chronic mucocutaneous candidiasis was treated with Ketoconazole 100 mg daily for 6 weeks. Oral thrush disappeared after a week, while cutaneous lesions cleared within a month. Her nail dystrophy disappeared during the following months. Repeated cultures were negative for *Candida albicans*. The patient has remained in remission for an 8-month period. Our findings thus support previous reports indicating that Ketoconazole is an effective agent against this disease.

**Key words:** *Candida albicans*; Chronic mucocutaneous candidiasis; Ketoconazole

Chronic mucocutaneous candidiasis (CMC) is a fairly rare condition, usually starting in infancy or early childhood with persistent candida infection of mouth, skin and nails refractory to conventional topical therapy and commonly associated with impaired cell-mediated immunity (7). Treatment has depended upon intensive chemotherapy together with attempts to restore T-cell function, i.e. by the use of transfer factor (4, 8). The chemotherapy normally used has been intravenous amphotericin B (5), which unfortunately is highly nephrotoxic.

Ketoconazole is a new imidazole derivative with broad *in vitro* antifungal activity (2). It has been found successful as well as safe in a number of clinical trials on various mycological disorders (1). Ketoconazole has also recently been tried with good results in a number of cases of CMC (3, 6). We report here another case of CMC successfully treated with Ketoconazole.

### CASE REPORT

An 8-year-old girl had had symptoms of mild CMC since infancy. There was no family history of skin diseases. She had responded poorly to conventional topical anti-fungal therapy or had relapsed immediately after treatment was stopped. On April 28, 1980, she was seen in our out-patient clinic, complaining of persistent oral thrush, chronic angular cheilitis, various persistent skin lesions (candidiasis) and chronic paronychia with nail dystrophy. She also suffered from mild anorexia, with difficulty in swallowing large food morsels. There were occasional spells of fever.

*Candida albicans* was cultured from her mouth, skin and nails. Immunological investigations showed a negative skin reactivity following testing with tuberculin and *C. albicans* extract. Her lymphocytes showed very weak *in vitro* reactivity in a lymphocyte transformation test following stimulation with *C. albicans*, whereas their mitogen reactivity was normal.

On June 16, 1980, she began receiving 100 mg of Ketoconazole daily *per os*. The thrush cleared within a week. By one month all skin lesions had cleared with the exception of the distal parts of individual nails, which later became normal. *Candida albicans* could no longer be cultured on repeated examination. Treatment was stopped after 6 weeks. We observed no side effects. The patient gained 1 kg in weight during the treatment. Until April 1981 she has remained in complete remission.

### COMMENT

CMC is usually very difficult to treat, irrespective of which subgroup of the disease the patient belongs to (7). Our patient fits best into the pattern of the familial autosomal recessive type of CMC. This

usually starts in the first decade of life, with persistent oral and nail plate lesions. General health is usually good, with no endocrine defects. A variety of defects of cell-mediated immunity have been demonstrated in some patients, while others appear to have a normal immune function as judged by currently available techniques. For these patients intravenous amphotericin B, which hitherto has been the only chemotherapeutic having adequate success, seems rather a hazard. The use of Ketoconazole therefore seems a great advance.

In our case, as well as in other reported cases of CMC (3, 6), Ketoconazole proved successful without the use of any immunotherapy. Adverse reactions to Ketoconazole seem to be few. Hepatitis in one patient (6) and transient decreases of serum cholesterol (3) and elevated SGPT-transaminases (E. Svejgaard, personal communication) have been observed. Laboratory tests including the tests mentioned above proved normal in our patient.

Current experience of other investigators (3, 6), together with an appreciation of the lack of immune resistance in patients with CMC, makes it likely that long-term or repeated treatments with Ketoconazole will be necessary. Our patient has now been in remission for 8 months following discontinuation of therapy.

### ACKNOWLEDGEMENT

The immunological studies in this patient could not have been performed without a grant from the Danish Medical Research Council (512-20063). We thank Ms Lene Lyck Poulsen for her secretarial assistance.

### REFERENCES

1. Bruggmans, J., Scheijngrou, H., van Cutsem, J., van den Bossche, H., Baisier, A. & Hörig, C.: Oral long-term treatment of onychomycosis with Ketoconazole. *Mykosen* 23 (8): 405-15, 1980.
2. Dixon, D., Shadomy, S., Shadomy, H., Espinel-Ingroff, A. & Kerkering, T. M.: Comparison of the *in vitro* antifungal activities of miconazole and a new imidazole, R. 41,400. *J Infect Dis* 138: 245-48, 1978.
3. Graybill, J., Hondon, J., Kniker, W. & Levine, H.: Ketoconazole treatment of chronic mucocutaneous candidiasis. *Arch Dermatol* 116: 1137-41, 1980.
4. Kirkpatrick, C. H. & Smith, T. K.: Chronic mucocutaneous candidiasis: Immunologic and antibiotic therapy. *Ann Int Med* 80: 310-20, 1974.
5. Montez, L. F., Cooper, M. D., Bradford, L. G., Lauderdale, R. O. & Taylor, C. D.: Prolonged oral treatment of chronic mucocutaneous candidiasis with amphotericin B. *Arch Dermatol* 107: 45-56, 1971.

6. Petersen, E. A., Alling, D. W. & Kirkpatrick, C. H.: Treatment of chronic mucocutaneous candidiasis with Ketoconazole. *Ann Int Med* 93: 791-95, 1980.
7. Roberts, S. & MacKenzie, D.: Mycology. In *Textbook of Dermatology* (ed. A. Rook, D. Wilkinson & F. Ebling). Blackwell Scientific Publications, Oxford, 1979.
8. Valdimarsson, H., Wood, C. B. S., Hobbs, J. R. & Holt, P. J. L.: Immunological features in a case of chronic granulomatous candidiasis and its treatment with transfer factor. *Clin Exp Immunol* 11: 151-63, 1972.

## Retinoid Acid in the Treatment of Hyperkeratosis lenticularis perstans Flegel

Helmut Lindemayr and Wolfgang Jurecka

Department of Dermatology II,  
University of Vienna, Vienna, Austria

Received March 16, 1981

**Abstract.** Successful treatment with oral retinoid acid (Ro 10-9359) in a case of Hyperkeratosis lenticularis perstans Flegel is reported. Membrane coating granules (Odland bodies) could be demonstrated in all sections of lesional epidermis.

**Key words:** Hyperkeratosis lenticularis perstans Flegel; Keratinization disorder; Odland bodies; Oral retinoid acid treatment

Hyperkeratosis lenticularis perstans (HLP), first described in 1958 by Flegel (1), is probably an autosomal dominant keratinization disorder. It occurs as small foci on the skin, preferring the distal parts of the lower extremities. The lesions persist indefinitely.

Cases of HLP not only aroused interest because of their rarity—up to 1980 only about 40 cases of HLP have been published—but also because of a unique process of keratinization occurring in the absence of membrane-coating granules (MCG, Odland bodies) as postulated by Frenk & Tapernoux (2).

So far, fluoro-uracil (9) and dermabrasion have been found to be helpful in treating HLP. For the first time, clinical effectiveness of a systemic retinoid

acid treatment (Ro 10-9359, all-trans-9-(4-methoxy-2,3,6-trimethylphenyl)-3-7-dimethyl-2,4,6,8-nona-tetraenoate, Roche) is reported.

### CASE REPORT

Three years ago, a 71-year-old Austrian housewife observed the appearance of asymptomatic, horny papules on the dorsa of her feet. Within a few weeks new similar lesions were detected on the whole circumference of the lower legs and, less distinctly, on the thighs and on upper arms.

The patient was in fairly good health and had an uneventful personal history. Her parents, her six brothers and sisters and her son were reported to be free of similar lesions.

Examination of the affected skin revealed small reddish-brown horny papules, 1-5 mm in diameter, which could easily be removed in one piece, leaving a brilliant epidermis, with punctiform bleeding areas accentuating a psoriasiform aspect (Fig. 1). No inflammatory halo could be found around the numerous non-follicular hyperkeratoses. On palms and soles no pinpoint-sized depressions interrupting the papillary lines (as described by Kocsard, 9) were seen. Hair, nails and mucous membranes were normal.

Previous therapeutic trials with locally applied retinoid acid and urea had failed. Initial systemic treatment consisted of aromatic retinoid (Ro 10-9359) with a daily dose of 1 mg/kg/day. This dosage was reduced to 0.6 mg/kg/day after 10 days. Because of side effects such as headaches, and burning palms and soles, retinoid therapy had to be terminated after 6 weeks, when skin lesions had improved markedly. Within a 7-week period without treatment, the condition recurred, and a second series of treatment with oral aromatic retinoid was therefore tried. Further improvement of the hyperkeratoses could subsequently be observed.

Skin biopsies for light microscopy of two lesions of the lower leg were performed before retinoid treatment was started. In all sections the hyperkeratosis was mainly of

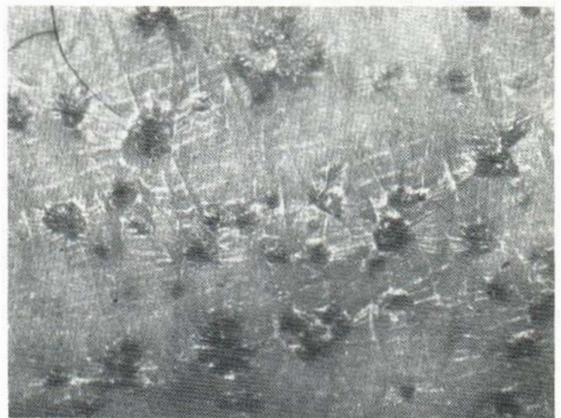


Fig. 1. Hyperkeratosis lenticularis perstans Flegel.