

including potent allergens which can be the cause of asthma or rhinitis in bakers (1, 3).

The patient developed contact urticaria after exposure to bran bath, which means that allergens from the bran were able to penetrate the skin easily. The positive transfer test is proof of the role of homocytotropic antibodies in this case. According to the history, contact with wheat elicited itching.

Reaction to the ingestion of wheat was a further possibility in this infant. Although no definite history of exacerbation was found after eating bread, we tried a gluten-free diet. During this period the infant's atopic dermatitis was essentially improved and when wheat products were reintroduced in the diet, a subsequent exacerbation was registered. These observations strongly suggest that wheat as a food allergen also elicits an allergic reaction (of the immediate type) in the patient. However, it was difficult to decide whether the repeated bran baths (given since the patient was 8 months old) or possible ingestion (active or by lactation) of wheat was the primary sensitizer.

Furthermore it should be remembered that a certain degree of caution is recommended with regard to the application of bran baths over longer periods of time to children who have multiple food allergies.

REFERENCES

1. Baldo, B. A. & Wrigly, W.: IgE antibodies to wheat flour components. *Clin Allergy* 8: 109, 1978.
2. Frostad, A. B., Bolle, R., Grimmer, Ø. & Aas, K.: A well characterized, purified allergen preparation from Timothy pollen. II. Allergenic *in vivo* and *in vitro* properties. *Int Arch Allergy Appl Immunol* 55: 35, 1977.
3. Hendrick, D. J., Davies, R. J. & Pepys, J.: Baker's asthma. *Clin Allergy* 6: 241, 1976.
4. Hjørt, N. & Roed-Pettersen, J.: Occupational protein contact dermatitis in food handlers. *Contact Dermatitis* 2: 28, 1976.

Lymphocytoma Cutis: A Pseudomalignancy Treated with Penicillin

B. Lasthein Andersen,¹ F. Brandrup¹
and J. Petri²

¹Department of Dermatology and
²Department of Pathology, The Finsen Institute,
Copenhagen, Denmark

Received April 13, 1981

Abstract. Two patients with severe cutaneous lymphoplasia provoked by traumas from rose twigs are presented. In both cases the histopathological changes were primarily interpreted as being malignant. Both, however, were treated successfully with penicillin.

Key words: Lymphocytoma cutis; Traumatically provoked cutaneous lymphoplasia; Penicillin treatment

Lymphocytoma cutis is an uncommon skin tumour with unknown aetiology and varying clinical and histopathological features (1). Actinic injury, tick-born virus, insect bites and trauma have been incriminated as aetiological factors (1).

Some cases of lymphocytoma cutis can be recognized histologically as unequivocally benign reactive lesions, whereas others—due to considerable density of the infiltrates, presence of atypical mononuclear cells and some mitotic activity—can mimic malignant lymphoreticular tumefactions of the skin to an extent that makes distinction between benign and malignant lesions extremely difficult or even impossible (3, 4, 5).

We present two cases where a severe cutaneous lymphoplasia was attributed to traumas from rose twigs. The histological changes were primarily interpreted as being malignant. Both cases were treated successfully with penicillin.

CASE REPORTS

Case 1

An 80-year-old man was referred to the dermatological department because of a cutaneous infiltrate of the skin.

In November 1975 he was injured on his chin by a rose twig. One month later an inflammatory intumescence appeared. The intumescence varied somewhat in size, but was steadily progressing.

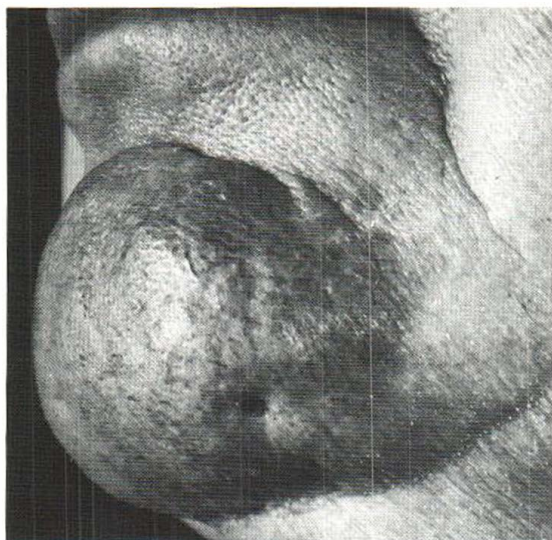


Fig. 1. Case 1 before treatment. The tumour measures 6×5 cm.

Excision biopsy taken at another dermatological department in March 1976 showed a lymphoreticular infiltrate arousing suspicion of a malignant lymphoreticular disease. Due to the lack of systemic symptoms, no treatment was given, and due to a misunderstanding the patient was not followed up until he was referred to the Finsen Institute in April 1980. At this time the patient presented a solid 6×5 cm large, purple tumour reaching the mandible without being fixed thereto (Fig. 1). There was no invasion in the oral cavity and no sign of disseminated malignant lymphoma; leukaemia, tuberculosis and syphilis could be excluded.

Histopathology. A punch biopsy taken at the initial visit showed a dense but rather patchy lymphocytic infiltrate which filled the dermis from epidermis to subcutis (Fig. 2). The infiltrate consisted of mature lymphocytes and a few histiocytes. Mitotic figures were not present. In some areas infiltration of lymphocytes in single file between the collagen bundles was seen, but no infiltration of appendages and blood vessels was found.

Treatment. Fenoxymethylpenicillin (Vepicombin®) 500 000 IU orally three times a day for 4 weeks reduced the tumour to 3×3 cm (Fig. 3). The treatment was continued for a further 3 weeks at which time the tumour had disappeared, leaving only a slight hypertrophic scar in the primary excision biopsy cicatrix.

Case 2

A 72-year-old woman reported to the dermatological department because of lymphoma malignum cutis.

In February 1978 the patient developed a swelling of the second right finger interstice, in which area she claimed that she had been injured by a rose thorn. The swelling increased, and in May 1978 she was operated on at an orthopedic department because on clinical suspicion of a ganglion. Histopathological examination of the tissue showed massive infiltration of lymphocytic cells.

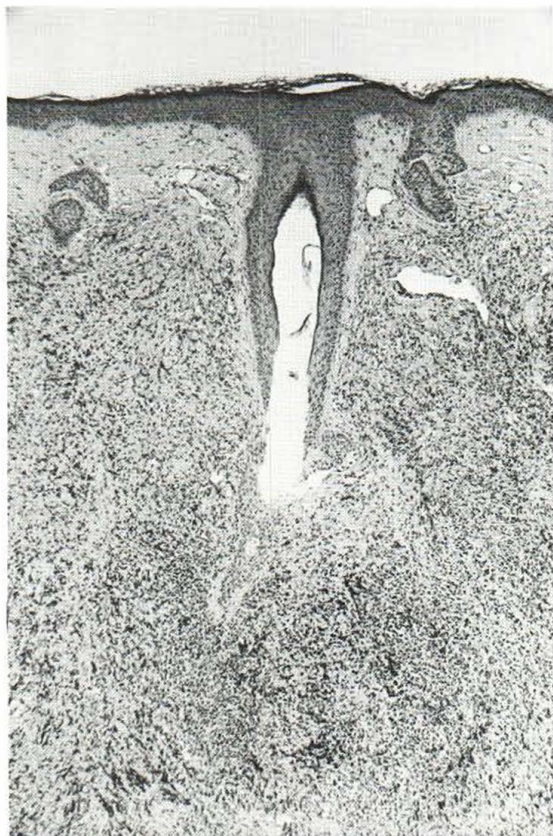


Fig. 2. Case 1. Section of skin biopsy from the chin showing a rather dense, diffuse infiltrate consisting mainly of well-differentiated lymphocytes. The infiltrate spares the papillary dermis. There is no reactive hyperplasia of the epidermis. (H & E, ×35.)

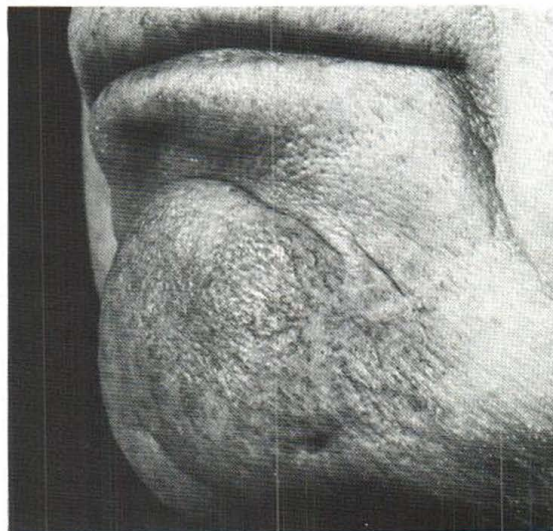


Fig. 3. Case 1 after treatment with penicillin during 4 weeks.

During the following months the patient developed a gradually increasing, purple infiltrate on the dorsal side of the right hand extending to the dorsal and proximal part of the 2nd and 3rd finger. In April 1979 excision biopsy was made at the orthopedic department. The histopathological changes were interpreted as the cutaneous manifestation of a malignant lymphoma or chronic lymphatic leukaemia, and the patient was referred to the haematological department. Examination showed no signs of disseminated malignant lymphoma, leukaemia, tuberculosis or syphilis. Radiation treatment with two series of 10 GY each failed to reduce the size of the tumour and the patient was referred to the dermatological department.

Dermatological examination now showed a massive, purple swelling of the dorsal part of the right hand extending to the dorsum of the 1st, 2nd and 3rd finger.

Revision of histopathology

In the excised tissue taken at the operations a massive, diffuse lymphocytic infiltrate in the dermis and subcutis was present. The lymphocytes were well differentiated and not arranged in follicular structures. Mitotic figures were not present. Peripheral nerves present in the tissue were not infiltrated by the lymphocytes. In some areas a marked proliferation of capillary vessels was seen intermixed with the massive infiltrate. Neither epidermis nor appendages were present in the tissue specimens.

Treatment

Fenozymethylpenicillin (Vepicombin®) 500 000 IU orally four times a day for 2 weeks reduced the size of the tumour after a few days' treatment. After termination of treatment only atrophy remained on the affected sites of the right hand, resembling the senile atrophy of the dorsal part of the left hand.

DISCUSSION

The two cases presented here were both clinically and histopathologically lymphocytoma cutis, but the difficulties in differentiating this condition from a malignant lymphoma are illustrated by the fact that the lymphocytic infiltration was initially stated to be malignant. In both cases trauma seemed to be the trigger factor, even if insect bites cannot be excluded with certainty.

In our cases an attempt was made to classify the lymphocytic infiltrate according to From (5). In case 2 no epidermal structures were present in the tissue specimens and a classification can thus only be made with some uncertainty, but type 5 (dense non-follicular lymphocytic infiltrate) seems the most likely. In case 1 the infiltrate was classified as a clear-cut type 5.

Lymphocytoma cutis is not a manifestation of any systemic disorder and the prognosis is judged

to be favourable, as stated by several authors (3, 4, 6) who found that all patients with lymphocytoma cutis had a benign course ending in cure, either as a result of treatment or as a spontaneous remission.

Bianchi (2) and others (4, 6) found that some cases of lymphocytoma cutis could be cured with penicillin, which our two cases demonstrate in a convincing way.

REFERENCES

1. Beare, J. M. & Cunliffe, W. J.: Benign lymphoplasias of the skin. *In* Textbook of Dermatology (ed. A. Rook, D. S. Wilkinson & F. J. G. Ebling), 3rd ed., chapter 46, p. 1529. Blackwell Scientific Publications, Oxford, 1979.
2. Bianchi, G. E.: Die Penicillinbehandlung der Lymphocytome. *Dermatologica* 100: 270, 1950.
3. Bäfverstedt, B.: Lymphadenosis benigna cutis, its nature, course and prognosis. *Acta Dermatovener (Stockholm)* 40: 10, 1960.
4. Bäfverstedt, B.: Lymphadenosis benigna cutis. *Acta Dermatovener (Stockholm)* 48: 1, 1968.
5. From, L.: Lymphocytic infiltrates. *In* Dermatology in General Medicine (ed. Th. B. Fitzpatrick et al), 2nd ed., chapter 75, p. 680. McGraw-Hill Book Company, New York, 1979.
6. Mach, K. W. & Wilgram, G. E.: Characteristic histopathology of cutaneous lymphoplasia (lymphocytoma). *Arch Dermatol* 94: 26, 1966.

Treatment of Kaposi's Varicelliform Eruption with Adenine Arabinoside (Vira-A) and Transfer Factor

Peter Bjerring, Kristian Thestrup-Pedersen and
Hugh Zachariae

*Department of Dermatology, University of Aarhus,
Marselisborg Hospital, DK-8000 Aarhus C., Denmark*

Received March 28, 1981

Abstract. Kaposi's varicelliform eruptions, or Eczema herpeticum, are the result of a herpes virus infection. This paper reports on a patient who was treated with parenteral infusion of a new anti-viral drug, adenine arabinoside (Vira-A), and transfer factor in an attempt to halt the spread and alleviate the severity of the disease. It is our