

4. Lidén, S., Beckman, B., Cedergren, B., Groth, O., Göransen, K. & Wählby, L.: Lack of association between allergic contact dermatitis and HLA antigen of the A and B series. *Acta Dermatovener (Stockholm)* 61: 155, 1980.
5. Magnusson, B. & Kligman, A. M.: The identification of contact allergens by animal assay. The guinea pig maximisation test. *J. Invest Dermatol* 52: 268, 1969.
6. Malten, K. E., Nater, J. P. & van Ketel, W. G.: Patch Testing Guidelines. Dekker en van de Vegt, Nijmegen, 1976.
7. Menne, T.: Relationship between cobalt and nickel sensitization in female. *Contact Dermatitis* 6: 337, 1980.
8. Müller, R. & Breucker, G.: Kobalt als arbeitsbedingtes Ekzematogen und als Koppelungsallergen mit Chrom und Nickel. *Dermatol Wochenschr (Leipzig)* 154: 277, 1968.
9. Rystedt, I.: Evaluation and relevance of isolated test reaction to cobalt. *Contact Dermatitis* 5: 223, 1979.
10. Silvennoinen-Kassinen, S., Honen, I., Tülikainen, A. & Karvonen, J.: No significant association between HLA and nickel contact sensitivity. *Tissue Antigens* 14: 459, 1979.
11. Van den Berg, J. J. & Epstein, W. L.: Experimental nickel contact sensitization in man. *J Invest Dermatol* 44: 413, 1963.
12. Wahlberg, J. E. & Boman, A.: Sensitization and testing of guinea pigs with cobalt chloride. *Contact Dermatitis* 4: 128, 1978.
13. Wilkinson, D. S., Fregert, S., Magnusson, B. et al.: Terminology of contact dermatitis. *Acta Dermatovener (Stockholm)* 50: 287, 1970.

## Transient Lymphomatoid Papulosis in Mycosis fungoides

A. Aronsson, N. Jonsson and E. Tegner

Departments of Dermatology and Pathology,  
University of Lund, Lund, Sweden

Received March 4, 1982

**Abstract.** During PUVA treatment a 66-year-old woman with mycosis fungoides in stage III suddenly developed widespread papulonodular lesions of alarming clinical and histological appearance. There was rapid spontaneous and complete regression of the eruptions, which was probably an expression of transient lymphomatoid papulosis in connection with MF.

**Key words:** Mycosis fungoides; Lymphomatoid papulosis; PUVA treatment

Photochemotherapy with psoralens and ultraviolet-A (PUVA) generally has a beneficial effect

on mycosis fungoides (MF) in the plaque stage (5). However, a few cases of internal dissemination during successful external treatment have been described (4, 8). Spreading of skin tumours during PUVA treatment of MF in both plaque and tumour stages has also been observed (10). We report a woman with MF who during a short series of PUVA treatments developed acute, papulonodular lesions with a malignant clinical and histological picture.

### CASE REPORT

The patient was a 66-year-old woman who had had widespread, slowly progressing skin lesions for about 30 years, and who had experienced accentuated itching for the last few years. She complained of gradually increasing discomfort, with discoloration, dryness, and irritation of the skin, and was admitted to the Department of Dermatology. On admission she had no constitutional symptoms. The skin showed poikiloderma with reticulate hyperpigmentation. Brownish plaques with scaling were present, especially on the trunk and legs, some with prominent infiltration and a tendency to tumour formation. Freely mobile lymph nodes were palpated in axillae and groins. Treatment with potent topical corticosteroids gave good symptomatic relief, and some regression of both skin lesions and lymph nodes occurred. After three treatment sessions with PUVA (total 1.5 J/cm<sup>2</sup>) multiple symmetrical purplish papulonodules suddenly developed, mostly on the trunk, but some also on the extremities (Fig. 1).

During the ensuing week fulminating lesions continued to appear. The patient remained in good general condition. 10 days after the appearance of the initial lesions, spontaneous regression occurred. The papules became haemorrhagic, crusted, and fell off. Some lesions literally melted down, and some were infected with *Staph. aureus*. This process lasted for one week, after which the skin was completely free from lesions.

Histopathological examination of an infiltrated plaque showed a parakeratotic stratum corneum with clusters of leukocytes. Subepidermally there was a dense infiltrate of lymphoid cells with some atypical cells, and small collections of atypical cells were found in the lower and middle epidermis. The findings were consistent with MF. Histopathological examination of a fresh violaceous papule (Fig. 2) showed ulceration with dense infiltration in the dermis by irregular polymorphic cells having hyperchromatic nuclei, sometimes with a prominent nucleolus. The findings indicated malignant lymphoma, probably immunoblastic sarcoma. Another punch biopsy was taken from a resolving lesion: lymphocytic vasculitis was predominant, with numerous erythrocytes in the dermis. Infiltrates of irregular lymphoid cells were still present around the vessels, although the changes were now less

**Note:** The patient is included in the current investigation by the Scandinavian Mycosis Fungoides Study Group.

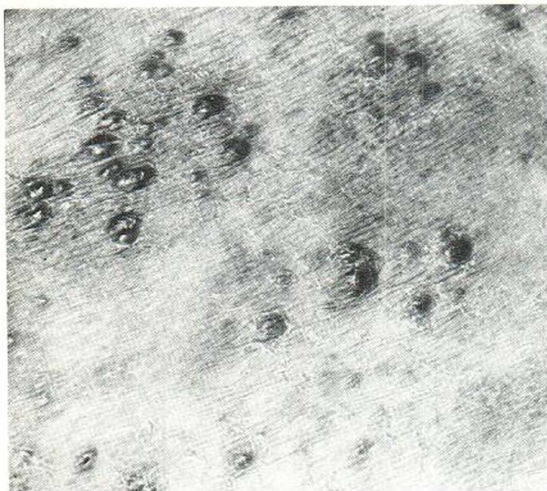


Fig. 1. Close-up of multiple papulonodules at the start of the eruption.

pronounced. Some of the cells were pyknotic. Frequent mitoses could still be seen.

Laboratory investigations showed a normal erythrocyte sedimentation rate, normal blood values, normal serum proteins, normal liver function tests, and normal bone marrow. Chest X-ray and scintigraphy of liver and spleen were normal. The patient showed no response to dinitrochlorobenzene (DNCB) challenge.

### DISCUSSION

Initially the MF seemed to have become transformed into a non-epidermotropic, high-grade malignant lymphoma. Papular eruptions in MF are said to signify a poor prognosis, associated with rapid extracutaneous dissemination and brief survival (3). In the present case however, the rapid evolution of alarming lesions followed by spontaneous resolution was rather suggestive of lymphomatoid papulosis.

Lymphomatoid papulosis, characterized as a separate entity by Macaulay (7), is a histologically malignant but clinically benign condition. It has been included among the T-cell (pseudo) lymphomas (2, 6), perhaps kept in check by immunological mechanisms (9). A few cases have been reported in which the course was chronic and terminated in overt malignant lymphoma (1, 11), the lymphomatoid papulosis having usually persisted for many years before turning malignant. A few reports of lymphomatoid papulosis occurring in MF and parapsoriasis have been published, however (6).

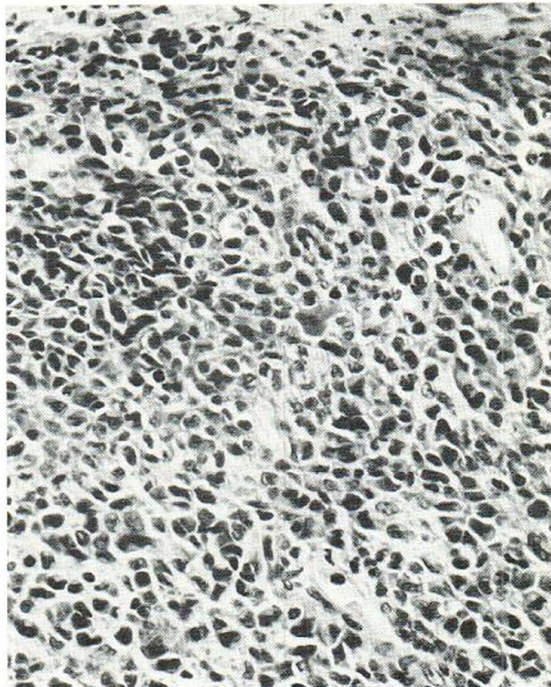


Fig. 2. Skin from a papule showing dense lymphoid-cell infiltration with highly polymorphic nuclei below the ulcerated surface (haematoxylin-eosin,  $\times 320$ ).

In our patient the MF had been evolving very slowly, and was of long standing. The rapidly vanishing eruptions developed with the initiation of PUVA treatment, but the significance of this remains obscure. It is difficult to see how the few sessions of PUVA could have provoked this reaction. Cytostatic chemotherapy was being considered when the lesions started to disappear. We report this case because of the rapid spontaneous resolution of the eruptions.

### REFERENCES

1. Brehmer-Andersson, E.: Mycosis fungoides and its relation to Sézary's syndrome, lymphomatoid papulosis, and primary cutaneous Hodgkin's disease. *Acta Dermatovener (Stockholm)* 56, Suppl. 75, 1976.
2. Burg, G., Hoffmann-Fezer, G., Nikolowski, J., Schmoeckel, C., Braun-Falco, O. & Stünkel, K.: Lymphomatoid papulosis: A cutaneous T-cell pseudolymphoma. *Acta Dermatovener (Stockholm)* 61: 491, 1981.
3. Edelson, R. L.: Cutaneous T-cell lymphoma. *J Dermatol Surg Oncol* 6: 358, 1980.
4. Fischer, T., v. Vloten, W. A. & Volden, G.: Internal dissemination of mycosis fungoides despite suc-



- cessful local therapy. *Acta Dermatovenere (Stockholm)* 58: 88, 1978.
5. Gilchrist, B. A., Parrish, J. A., Tanenbaum, L., Haynes, H. A. & Fitzpatrick, T. B.: Oral methoxsalen photochemotherapy of mycosis fungoides. *Cancer* 38: 683, 1976.
  6. Lutzner, M., Edelson, R., Schein, P., Green, I., Kirkpatrick, C. & Ahmed, A.: Cutaneous T-cell lymphomas: The Sézary syndrome, mycosis fungoides and related disorders. *Ann Intern Med* 83: 534, 1975.
  7. Macaulay, W. L.: Lymphomatoid papulosis. *Int J Dermatol* 17: 204, 1978.
  8. Molin, L., Skögh, M. & Volden, G.: Letter to the Editor: Successful PUVA treatment in the tumour stage of mycosis fungoides associated with the appearance of lesions in organs other than the skin. *Acta Dermatovenere (Stockholm)* 58: 189, 1978.
  9. Thomsen, K., Hjort, G. & Svendsen, D.: Lymphomatoid papulosis. *Dermatologica* 144: 65, 1972.
  10. Tourbier, H. & Schultz-Ehrenburg, U.: Etagenwechsel bei Mykosis fungoides unter systemischer PUVA-Therapie. *Z Hautkr* 56: 923, 1981.
  11. Weinman, V. F. & Ackerman, A. B.: Lymphomatoid papulosis. A critical review and new findings. *Am J Dermatopathol* 3: 129, 1981.

## Actinic Granulomas and Relapsing Polychondritis

G. E. Pierard, A. Henrijean, J. M. Foidart  
and Ch. M. Lapiere

*Department of Dermatology, Hôpital de Bavière,  
University of Liège, B-4020 Liège, Belgium*

Received March 9, 1982

**Abstract.** A patient developed concomitantly chondritis of the two auricles, diffuse cutaneous vasculitis and actinic granulomas. Alterations in skin and cartilage were prominent in the elastic tissue. Anticollagen type II antibodies were absent from the serum and there was no deposit of immunoreactants in cartilages. In this form of relapsing polychondritis, the pathomechanism resembles that of diffuse actinic arteritis as proposed by O'Brien. It is concluded that relapsing polychondritis may represent a heterogeneous syndrome with regard to its pathogenesis.

**Key words:** Elastic fibres; Collagen type II; Elastolysis

Immunologic abnormalities are important in the pathogenesis of relapsing polychondritis. Cell-mediated responses to cartilage proteoglycans were reported to be active at the time of disease activity

(2, 6). Recent developments in immunopathology have also demonstrated the existence of circulating antibodies to type II collagen and of circulating immune complexes during the acute phase of general involvement (1). In vivo deposits of immunoglobulins and complement in cartilage were sporadically observed.

These results do not prove that some of the described immunological alterations are responsible for the initiation of the disease. They could be related phenomena participating in the generalization of the disease. They could represent a consequence rather than the cause of the initial alteration at one site in the body.

We report here the clinical and histological presentation of a patient who experienced an acute chondritis of both ears in association with actinic granulomas (3, 4, 5) and discrete vasculitis.

### CASE REPORT

A 57-year-old man was referred to us for treatment of a widespread erythematous dermatitis associated with papular lesions on the arms and with an inflammatory edema of both ear pinnae. No previous similar dermatitis was reported by the patient, except for edema of the ears. Cartilages other than those of the ears were apparently uninvolved.

Pertinent laboratory data included the following: normal blood cells counts and ESR, fibrinogen slightly increased: 5 to 7 g/l ( $N: 4$ ),  $\alpha_2$ -globulin over 10.5% ( $N: 9.5\%$ ), C1q-binding activity 9.4% ( $N: 5.6 \pm 3.8\%$ ). Joints were found normal at X-ray examination.

After 3 weeks of topical corticotherapy, papular lesions resolved leaving atrophic macules, and inflammation of the ears faded, though leaving a permanent alteration of the aspect of the pinna.

We studied by optical microscopy five biopsies taken from the ears, face, arms, and buttock. Antibodies to type II collagen were searched by direct and indirect immunofluorescence using the technique of Foidart et al. (1).

### RESULTS

A lesion biopsied on the buttock corresponded to a sample of the diffuse erythematous dermatitis. The lesions were interpreted as a lymphocytic vasculitis.

Lesions collected on the arm and on the face corresponded to isolated erythematous papules. Histologically, tiny granulomas were organized around vessels localized inside a thick band of actinic elastosis. Small mononuclear cells and multinucleated giant cells predominated in the infiltrate