

cells and double-labelled cells was calculated. The quotient "single-labelled ^{14}C -cells + double-labelled cells/single-labelled ^3H -cells" allows an estimation of the duration of the S-phase.

The statistical analysis of results obtained from animals investigated at various times was made with the Kruskal-Wallis test. The required level of significance was $\alpha=0.05$.

RESULTS

The results are presented in Fig. 1. The following conclusions are of importance:

1. The various parameters show parallel fluctuations during the day in the epidermis and in the sebaceous glands.

2. With regard to the mitosis index (Colcemid method), the sum of labelled cells (corresponding to the [^3H]thymidine labelling index in single labelling [^3H]thymidine autoradiography), and the quotient "single labelled ^{14}C - and double-labelled cells/single-labelled ^3H -cells" (corresponding to the duration of the S-phase) a clear diurnal dependency with a minimum in the night is seen in the epidermis and the sebaceous glands. The differences found at various times of the day using the Colcemid method were statistically significant ($\alpha=0.05$ in the sebaceous glands, as well as in the epidermis).

3. The analysis of single-labelled ^3H -cells (=number of cells which leave the S-phase in one hour) did not reveal any clear diurnal variation.

DISCUSSION

Human sebaceous gland secretion is known to be dependent on circadian rhythms (1). However, since sebaceous gland secretion is dependent on a variety of parameters, these investigations do not allow of the assumption that all cell kinetic parameters in the sebaceous gland are subject to circadian rhythms. Investigations by Hamilton (2) in the mouse indicate that such diurnal dependency could exist. Here the [^3H]thymidine labelling index in the sebaceous gland was compared in the morning and at night. The values were strikingly lower during the night. Measurements of the [^3H]thymidine labelling index in the Swiss-albino mouse by Laurence et al. (3) make it clear that large diurnal variations exist, without however demonstrating a definite minimum or maximum. It is interesting that both Hamilton (2) and Laurence et al. (3) found a parallel diurnal effect on the [^3H]thymidine labelling index in the epidermis and the sebaceous gland.

The present results supply for the first time statistical evidence that with the Colcemid method the measured values in the sebaceous glands are subject to diurnal variation. In this regard it is also probable that the number of all labelled cells and the quotient "single-labelled ^{14}C -cells + double-labelled cells/single-labelled ^3H -cells" (corresponding to the duration of the S-phase) are subject to circadian rhythms. The present results impressively support the observation of Hamilton (2) and Laurence et al. (3) that the epidermis and the sebaceous glands show a parallel diurnal variation.

ACKNOWLEDGEMENT

This study was supported by the Deutsche Forschungsgemeinschaft (Grant G1 91/4) and is dedicated to Prof. Dr H. C. Friederich, Marburg/Lahn, on the occasion of his 60th birthday.

REFERENCES

- Burton, J. L., Cunliffe, W. J. & Shuster, S.: Circadian rhythm in sebum excretion. *Br J Dermatol* 82: 497-501, 1970.
- Hamilton, E.: Cell kinetics in the sebaceous glands of the mouse. I. The glands in resting skin. *Cell Tissue Kinet* 7: 389-398, 1974.
- Laurence, E. B., Spargo, D. J. & Thornley, A. L.: Cell proliferation kinetics of epidermis and sebaceous glands in relation to chalone action. *Cell Tissue Kinet* 12: 615-633, 1979.
- Plewig, G. & Luderschmidt, C.: Hamster ear model for sebaceous glands. *J Invest Dermatol* 68: 171-175, 1977.
- Schaaf, F.: Probleme dermatologischer Grundlagenforschung. Hüthig, Heidelberg 1969.

Immunofluorescence Studies on Complement Components in Lichen amyloidosis

Shigenori Sudo, Ryoichi Igarashi and Masaaki Morohashi

Department of Dermatology, Toyama Medical and Pharmaceutical University, Toyama, Japan

Received October 28, 1981

Abstract. Immunofluorescence studies were carried out in 7 cases of lichen amyloidosis, chiefly to detect deposition of complement components in the cutaneous lesions. Examination of skin biopsy specimens revealed deposition of C1q, C3, C9 and IgM in all the patients studied. Comple-

ment and immunoglobulin levels by assays of simultaneously obtained serum samples were found to be almost within the normal limits.

Key words: Lichen amyloidosis; Complement components; Immunofluorescence study

Previous immunofluorescence (IF) studies in primary cutaneous amyloidosis have demonstrated the deposition of such immunoglobulins as IgM, IgG and IgA in cutaneous lesions (3, 5). The deposition of C3 in the affected skin of patients with cutaneous amyloidosis has also been described, but reports of other complement components in affected skin are few as yet. This investigation was undertaken primarily to detect the complements in biopsy specimens from 7 patients with lichen amyloidosis by IF techniques. Evidence has been obtained of deposition of various other complement components in the lesions in addition to C3.

MATERIALS AND METHODS

Seven patients with lichen amyloidosis were investigated, 3 males and 4 females, whose ages ranged from 34 to 63 years. The time from the onset of illness till the biopsy ranged from 1 to a few years, and lesions were localized over the upper back extending to the nape in 4 cases and over the flexor aspects of the forearms in 3 cases. In each case, the biopsy specimen obtained was divided for light and electron microscopic examination. For light microscopy, the tissue was fixed in a 10% formalin solution, while a part of the specimen was preserved without fixation in a deep-freeze at -80°C for preparation of frozen sections. Tissue for electron microscopy was placed in 3% glutaraldehyde in 0.1 M cacodylate buffer for pre-fixation.

Light and electron microscopic examination

Paraffin wax sections of the formalin-fixed tissue specimens were stained with hematoxylin and eosin (H&E), periodic acid-Schiff (PAS), Congo red and thioflavine T. The procedure of electron microscopic tissue preparation for observation has been described elsewhere (4).

IF technique

Frozen sections were examined by direct IF for detection of complement components (Clq, C3, C4 and C5) and immunoglobulins (IgG, IgM and IgA) and by indirect IF for C9. The procedure employed was essentially the same as that described in the previous reports (1, 2). Fluorescein isothiocyanate-labelled sera were obtained from DAKO-immunoglobulins, Denmark (IgG, IgM and IgA), Behringwerke, West Germany (Clq, C3 and goat anti-rabbit IgG) and Medical Biological Laboratory, Japan (C4 and C5). The unlabelled rabbit anti-human C9 serum was obtained from DAKO-immunoglobulins. The specificity of each labelled serum was ascertained by the blocking test and Ouchterlony double immunodiffusion.

Quantitation of circulating complements and immunoglobulins

The serum levels of Clq, C4 and C9 were determined by single radial immunodiffusion technique and those of C3, IgG, IgM and IgA were determined by laser nephelometry.

RESULTS

Light and electron microscopic findings

In every case, there was microscopic evidence of masses, consisting of acidophilic material in H&E-stained sections, in the papillary layers. The substance was PAS-positive, stained reddish with Congo red, and gave off greenish fluorescence when observed with thioflavine T stain. Electron microscopically, a cotton wool-like accumulation of characteristic fibrils about 85 \AA in diameter was demonstrated in the stratum papillae. These findings established the substance as being amyloid.

IF findings

Deposition of the complement components Clq, C3 and C9 was found in the areas coinciding with amyloid deposition in the papillary layers in all cases studied. Fig. 1 shows deposition of Clq. C4 and C5 were also demonstrated in 2 cases. IF was most pronounced for Clq among complement components, except for C9 which was detected by the indirect method.

Deposition of IgM, with prominent fluorescence, was observed in the areas coinciding with amyloid deposition in the papillary layers in all cases studied (Fig. 2). IgG was demonstrated in 3 cases and IgA in 4 cases. These results are summarized in Table I.

Serum complements and immunoglobulins level

Assays were performed on sera from 6 of 7 patients, and revealed values almost within the normal limits for all these parameters.

DISCUSSION

The mechanisms of amyloid formation in primary cutaneous amyloidosis are scarcely known. A possible involvement of an immunologic mechanism in the pathogenesis of this disease, can nevertheless, not be ruled out. Most IF studies in primary cutaneous amyloidosis have been concerned with the behavior of immunoglobulins and have demonstrated with high frequencies (3) the deposition of IgM in the affected skin. Deposition of IgA and IgG has

Table 1. *Summary of IF findings*

Pat.	Age	Sex	Complement					Immunoglobulin		
			Clq	C 3	C 4	C 5	C 9	IgM	IgG	IgA
1	39	O ₂	#	+	+	+	#	#	+	-
2	63	O ₂	+	+	±	±	#	#	+	+
3	34	O ₂	+	+	-	-	+	+	-	-
4	38	O ₂	#	+	+	±	+	#	-	+
5	35	O ₂	+	+	-	-	+	+	±	+
6	40	O ₂	#	+	-	+	+	+	-	±
7	61	O ₂	#	#	-	-	#	#	+	+

also been shown, with lower frequencies. While C3 deposition in the cutaneous lesions of amyloidosis has been described (3, 5), there is no report as yet of the detection of any other complement components.

An attempt was made in this study, therefore, to detect complement components in the lesions of 7 patients with lichen amyloidosis by IF techniques. Our results provide evidence of deposition of Clq, C3 and C9 in all of 7 patients, with demonstration of a less conspicuous deposition of other complement components as well. As for the significance of these immunoglobulins and complement deposition, MacDonald et al. (3) postulated that the amyloid fibrils may act as a filamentous sponge which traps immunoglobulins and complements, particularly the particles of large molecular size such as IgM and readily-formed polymers of IgA. Furthermore, in the present study a prominent IF was observed for Clq, the highest molecular weight among the complement components. However,

there exists a possibility, of the complements in the lesion being not merely adsorbed onto amyloid fibrils but bound to immunoglobulins. The finding of deposition of Clq, an early component of complement, would suggest a possibility that complement activation along the classical pathway may take place by some cause, leading to local immunological change which in turn may play some role in the formation of amyloid.

To our knowledge, no report has been published of serum immunological abnormality in primary cutaneous amyloidosis. The findings of our serum investigation also showed an almost normal level of immunoglobulins and complements. This suggests that immunological disorder may be not so severe as to affect the serum level. Moreover, earlier serum investigation offers the possibility of detecting certain immunological abnormalities, since all our patients were examined at least one year after they had had lesions.

Further studies are under way to elucidate the

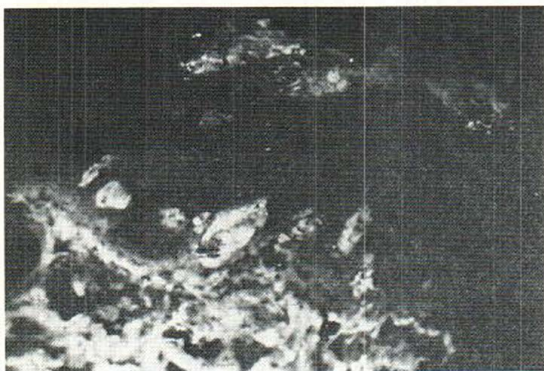


Fig. 1. Direct IF staining of Clq, showing positive fluorescence at the sites of amyloid deposition in the dermal papillae (Pat. 1, X100).

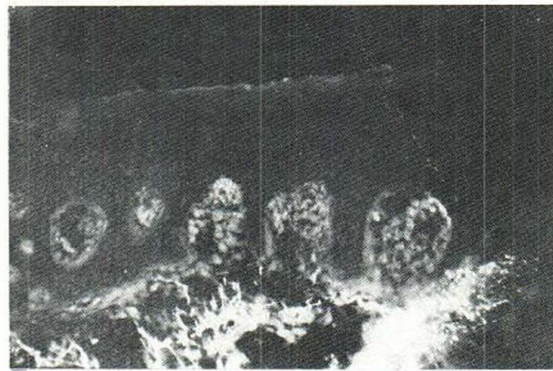


Fig. 2. Direct IF staining of IgM, showing positive fluorescence at the sites of amyloid deposition in the dermal papillae (Pat. 1, X100).

significance of the complement deposits demonstrated in the areas of amyloid fibrils of cutaneous lesions.

REFERENCES

1. Igarashi, R., Takeuchi, S. & Sato, Y.: Immunofluorescence studies of complement C3 in the hair follicles of normal scalp and scalp affected by alopecia areata. *Acta Dermatovener (Stockholm)* 60: 33, 1980.
2. Igarashi, R., Morohashi, M., Takeuchi, S. & Sato, Y.: Immunofluorescence studies on complement components in the hair follicles of normal scalp and of scalp affected by alopecia areata. *Acta Dermatovener (Stockholm)* 61: 131, 1981.
3. MacDonald, D. M., Black, M. M. & Ramnarian, N.: Immunofluorescence studies in primary localized cutaneous amyloidosis. *Br J Dermatol* 96: 635, 1977.
4. Morohashi, M. & Hashimoto, K.: Unusual studies in the epidermal Langerhans cells of normal human skin. *Acta Dermatovener (Stockholm)* 61: 195, 1981.
5. Vasily, D. B., Bhatia, S. G. & Uhlin, S. R.: Familial primary cutaneous amyloidosis. Clinical, genetic and immunofluorescence studies. *Arch Dermatol* 114: 1173, 1978.

Lymphocytotoxic Autoantibodies in Pemphigus and Systemic Lupus erythematosus

Fukumi Furukawa, Sadao Imamura, Shunji Inoue,¹
Haruyoshi Yoshida² and Yoshihiro Hamashima¹

¹Departments of Dermatology, Pathology, and ²Internal
Medicine, Faculty of Medicine, Kyoto University,
Sakyo, Kyoto 606, Japan

Received March 25, 1982

Abstract. Lymphocytotoxic autoantibody (LCTA) was studied in 9 patients with active pemphigus and 19 patients with active systemic lupus erythematosus (SLE). All patients with SLE showed high titres of LCTA but only one patient with pemphigus had LCTA. In this paper we discuss the immunological significance of LCTA and the difference in the incidence of LCTA between pemphigus and SLE. In addition we present the clinical features of the case with LCTA-positive pemphigus and suggests that the presence of LCTA is due to the common viral infection.

Key words: Lymphocytotoxic autoantibody; Pemphigus; Systemic Lupus erythematosus

In 1970 Terasaki et al. (10) reported the presence of lymphocytotoxic autoantibody (LCTA) in the

serum of patients with systemic lupus erythematosus (SLE). Stastny & Ziff (9) demonstrated that LCTA was correlated with the degree of clinical activity and suggested that LCTA might offer an explanation for the lymphopenia so commonly found in SLE patients. T cell specificity of LCTA in SLE was demonstrated (5) and Koike et al. (4) reported that LCTA had the analogy of natural thymocytotoxic autoantibodies appearing in New Zealand mice (8) and suggested, furthermore, that LCTA in patients with SLE is responsible for the selective loss of certain functional T cell subsets including suppressor T cells which are closely related to autoantibody production and play a significant role in the pathogenesis of SLE. Disturbance of suppressor T cells was also reported in pemphigus (2) and we therefore made a preliminary study of LCTA in pemphigus in order to elucidate the etiological analogy between SLE and pemphigus.

MATERIALS AND METHODS

Patients and sera

Sera from patients with SLE who satisfied the diagnostic criteria of the American Rheumatism Association for SLE (1) were collected. Sera from 9 patients with pemphigus, whose diagnosis was established by typical clinical features, histological and immunopathological findings and the presence of circulating IgG or polyvalent Ig antibodies against intercellular substances, were also collected. The numbers of patients with pemphigus vulgaris and foliaceus were 7 and 2, respectively. These patients were all in the active stage. All sera obtained were stored at -80°C until use.

Cells

Peripheral blood lymphocytes (PBL) were isolated from 5 normal volunteers with differing HLA by Ficoll-Paque (Pharmacia, Sweden) gradient.

Cytotoxic test

The test for lymphocytotoxic autoantibody was performed by the modified method of Shirai and Mellors (8). Briefly, a mixture of 0.025 ml of PBL suspension (6×10^5 /ml) in RPMI medium supplemented with 2% fetal calf serum and 0.05 ml patient serum in serial dilutions was incubated at 4°C for 30 minutes. Then the mixture was incubated again with 0.05 ml rabbit serum at concentration of 1:2 as a complement source. This rabbit serum was previously selected individually for low cytotoxicity for human PBL. The trypan blue dye exclusion method was employed to determine the dead cells and alive cells. Any serum that killed more than 20% of the cells in the test was graded positive, because the sera taken from 20 normal controls killed less than 20% of the cells. The cytotoxic titre of the serum tested was tabulated as the reciprocal of the serum dilution that produced more than