

## SUBPOPULATIONS OF MONONUCLEAR CELLS IN LESIONS OF PSORIASIS, LICHEN PLANUS AND DISCOID LUPUS ERYTHEMATOSUS STUDIED USING MONOCLONAL ANTIBODIES

Jens Roar Bjerke

*Department of Dermatology and Broegelmann Research Laboratory for Microbiology,  
University of Bergen, Norway*

**Abstract.** Mononuclear cells in skin lesions were characterized using an indirect immunofluorescence test with monoclonal antibodies. Most cells in the dermal infiltrates were stained with OKT3 (pan T cell) antibodies and with OKT4 (helper/inducer T cell) antibodies. Fewer cells were stained with OKT8 (suppressor/cytotoxic T cell) antibodies. Results obtained using a double marking technique with monoclonal antibodies and a hetero-anti-T lymphocyte serum showed that suppressor/cytotoxic cells comprised 15-25% of the T lymphocytes in lesions of psoriasis and discoid lupus erythematosus (DLE), and 25-35% in lesions of lichen planus. OKM1 (monocyte) antibodies stained few of the infiltrating cells in sections of the various skin lesions. The highest numbers of OKM1<sup>+</sup> cells were found in sections of lesional skin from patients with erythrodermic and pustular psoriasis. Some T lymphocytes were also demonstrated in the epidermis in the various skin lesions. The highest numbers were found in the psoriatic lesions. The epidermal T lymphocytes were mainly suppressor/cytotoxic cells, and may be involved in a cell-mediated immune reaction of importance in the pathogenesis of these dermatoses.

**Key words:** Psoriasis; Lichen planus; Discoid lupus erythematosus; Mononuclear cells; Monoclonal antibodies; Double marking

We have previously shown that the dermal mononuclear cell infiltrates in lesions of psoriasis (3, 5), lichen planus (4) and discoid lupus erythematosus (DLE) (6) consist of T lymphocytes and macrophages. Only small numbers of B lymphocytes have been detected (4, 5, 6). Monoclonal antibodies against T lymphocyte subpopulations are now commercially available. Monoclonal antibodies termed OKT4 react with T lymphocytes which have helper and inducer activity (20), and OKT8 antibodies react with T lymphocytes which have suppressor or cytotoxic activity (20). Also monoclonal antibodies against all peripheral T lymphocytes (OKT3) (20) and antibodies against monocytes (OKM1) (8) are available. Monoclonal anti-

bodies have recently been used for the characterization of mononuclear cells in cutaneous lymphomas (14), pseudolymphomas (9) and lesions of lichen planus (2).

In this study an indirect immunofluorescence test has been used with the monoclonal antibodies OKT3, OKT4, OKT8 and OKM1 to further characterize the mononuclear cell infiltrates in lesions of psoriasis, lichen planus and DLE. A combined technique with the monoclonal antibodies and a hetero-antiserum for double marking of T lymphocytes has also been applied.

### MATERIALS AND METHODS

#### *Patients and tissues*

Sixteen patients were included in the study. Four patients had stationary lesions of psoriasis vulgaris, 3 patients had active psoriatic lesions, 1 patient had psoriatic erythroderma, 2 patients had generalized pustular psoriasis, 3 patients had lichen planus and 3 patients had DLE. Skin biopsies, approximately 10×15 mm, were taken from fully developed lesions. The lesions chosen for biopsy had not received any local treatment for at least 2 weeks. In some cases, 4 mm punch biopsies were also taken from unaffected skin. Specimens of normal spleen, liver and kidney were obtained from the Department of Surgery.

The specimens were quick-frozen in isopentane precooled with liquid nitrogen, and sectioned 4 μm thick on a cryostat. The sections were stored at -20°C until used.

#### *Immunoglobulins*

The monoclonal antibodies OKT3, OKT4, OKT8 and OKM1 were purchased from Ortho Pharmaceutical Corporation, Raritan, N.J., USA. These antibodies are produced in a murine system. The antibodies have been fully characterized (8, 20), and their specificity is stated by the manufacturer: OKT3 react with all T lymphocytes in peripheral blood. OKT4 react with helper/inducer T lymphocytes and OKT8 with suppressor/cytotoxic T lymphocytes, approximately 65% and 35% of the T lymphocytes in peripheral blood, respectively. OKM1 react with 78% of adherent mononuclear cells and 18% of non-adherent mononuclear cells (null cells).

Table 1. Reactivity of monoclonal antibodies with mononuclear cells in sections of lesional skin from patients with psoriasis, lichen planus and discoid lupus erythematosus

Diagnosis	No. of patients	Monoclonal antibodies							
		OKT3		OKT4		OKT8		OKM1	
		D <sup>a</sup>	E <sup>b</sup>	D	E	D	E	D	E
Psoriasis vulgaris	4	5+ <sup>c</sup>	1+	4+	±	2+	1+	1+	-
Exudative psoriasis	3	4+	1+	4+	±	2+	1+	1+	-
Psoriasis erythroderma	1	4+	1+	4+	-	2+	1+	2+	±
Psoriasis pustulosa	2	4+	1+	4+	±	2+	1+	2+	±
Lichen planus	3	5+	±	4+	±	3+	±	1+	-
Discoid LE	3	5+	±	4+	-	2+	±	±	-

<sup>a</sup> D = dermal cells.

<sup>b</sup> E = epidermal cells.

<sup>c</sup> = percentage of cells stained: 5+ =>K75%, 4+ =51-75%, 3+ =26-50%, 2+ =6-25%, 1+ =1-5%, ± =<1%, - = no reaction.

#### Immunoglobulin preparations

Antiserum against human T lymphocyte antigens (HuT1.A) was raised by immunizing rabbits with human thymocytes (19). Rabbit IgG antibodies were isolated from the antiserum by ion exchange chromatography with DEAE-cellulose (Whatman DE-52) equilibrated with 0.015 M phosphate buffer, pH 7.6, followed by gel filtration on a Sephadex G-200 column. F (ab')<sub>2</sub> fragments were prepared according to the methods described by Stewart et al. (22). The IgG F (ab')<sub>2</sub> preparation of the anti-T lymphocyte serum was rendered specific as described elsewhere (19).

Fluorescein isothiocyanate (FITC)-conjugated swine anti-mouse IgG was purchased from Nordic Immunological Laboratories, Tilburg, Holland (code no. 12-380, protein concentration 10 mg/ml, molar F/P ratio between 1 and 4), and tetramethylrhodamine isothiocyanate (TRITC)-conjugated swine anti-rabbit IgG from DAKO-immunoglobulins A/S, Copenhagen, Denmark (code no. Z-109, rhodamine/protein extinction ratio, E<sub>531</sub> nm/E<sub>278</sub> nm, is 0.40±0.05). Before use, the preparations were centrifuged at 100 000 × g for 1 hour to remove aggregates. Pooled native human IgG (Fraction II, 16.5% solution) was purchased from AB Kabi, Stockholm, Sweden. Aggregation was performed by heating the human IgG preparation in a water bath at 63°C for 15 min. The swine anti-mouse IgG gave one precipitation line in double diffusion in agar against human serum. Before use, this IgG preparation was therefore absorbed with glutaraldehyde insolubilized human serum proteins prepared as described by Avrameas & Ternynck (1). Swine anti-rabbit IgG did not react with human serum proteins. There was no cross-reactivity between the other antibody preparations used, as demonstrated by double diffusion in agar.

#### Immunofluorescence technique

Cryostat sections were incubated at room temperature for 30 min with the monoclonal antibodies diluted in phosphate-buffered saline, pH 7.2 (PBS), and then washed for 30 min in PBS at room temperature. The OKT3 and OKT4

antibodies used were diluted 1:8, OKT8 and OKM1 1:32. In some experiments the monoclonal antibodies were diluted in PBS containing 4 mg/ml heat-aggregated human IgG. The sections were then incubated with FITC-conjugated swine anti-mouse IgG diluted 1:40 in PBS, washed and mounted in PBS-glycerol. The preparations were examined in a Zeiss fluorescence microscope with an Osram HBO-200 mercury lamp.

Double staining was performed by first incubating the sections with the IgG F (ab')<sub>2</sub> preparation (10 mg/ml) of anti-T lymphocyte serum (diluted 1:4 in PBS), followed by incubation with OKT8 antibodies (diluted 1:4). The sections were washed in PBS, and incubated with a mixture of the TRITC-conjugated swine anti-rabbit IgG (final dilution 1:40) and the FITC-conjugated swine anti-mouse IgG (final dilution 1:40). Finally, the sections were washed in PBS and mounted in PBS-glycerol.

The proportions of stained cells in double-stained preparations were evaluated on colour slides, obtained by photographing the preparations for green and red fluorescence on Ektachrome 400 daylight film with a Zeiss 40/1.0 immersion objective.

Controls were incubated with PBS instead of monoclonal antibodies or anti-T lymphocyte serum.

## RESULTS

The OKT3 antibodies stained the majority of the inflammatory mononuclear cells in sections from the various skin lesions (Table 1) (Fig. 1). Among the various types of psoriatic lesions, the highest proportion of OKT3<sup>+</sup> cells was found in stationary lesions of psoriasis vulgaris. In addition, both OKT4 and OKT8 antibodies stained mononuclear cells in the skin sections (Table 1). Some OKT4<sup>+</sup> and OKT8<sup>+</sup> lymphocytes could also be detected in the dermis in sections of unaffected skin. All the mono-

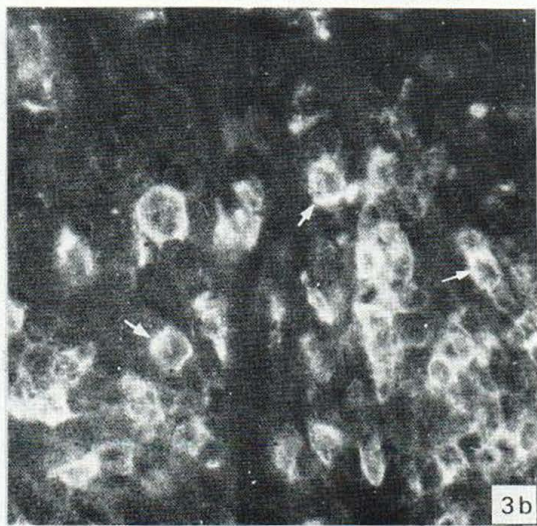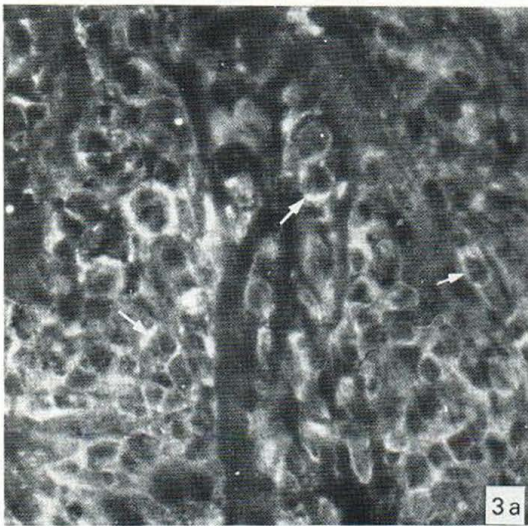
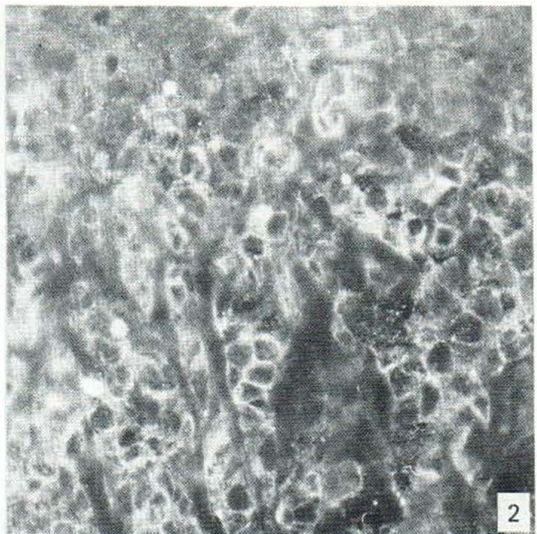
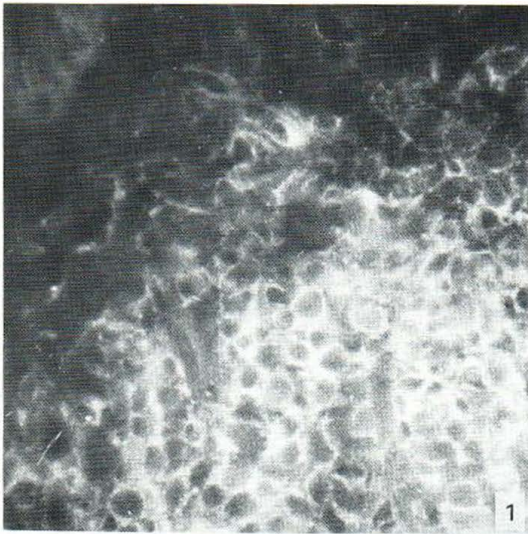


Fig. 1. Section of a stationary lesion of psoriasis vulgaris incubated with OKT3 antibodies. Most of the mononuclear cells show membrane staining.  $\times 350$ .

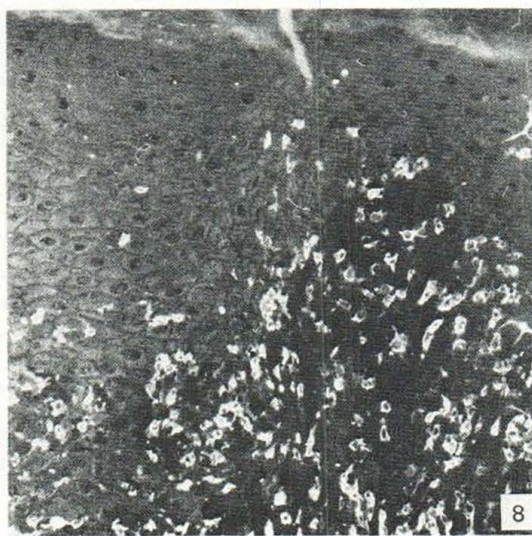
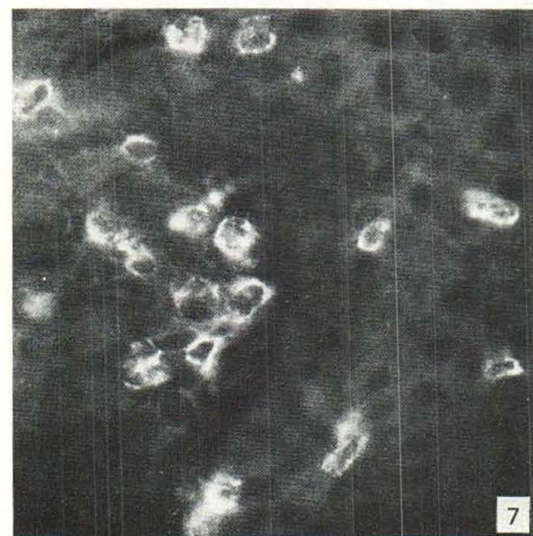
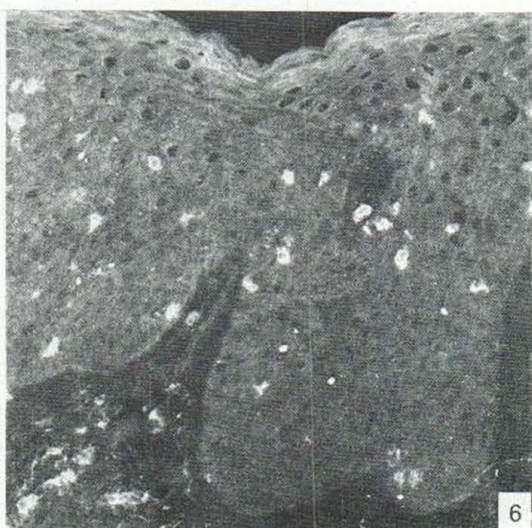
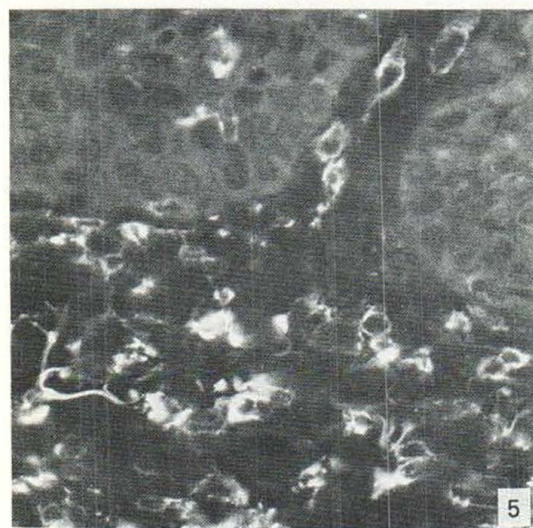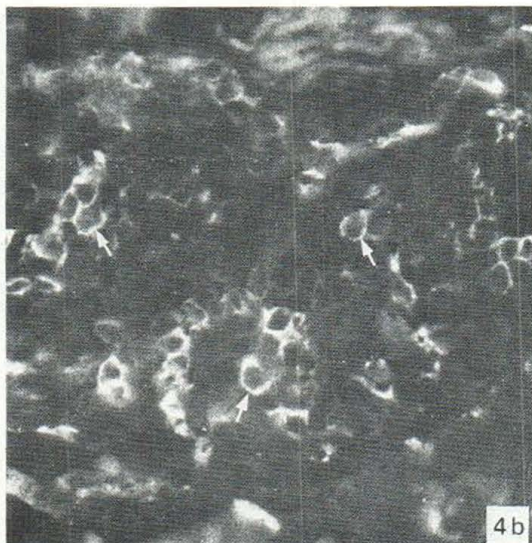
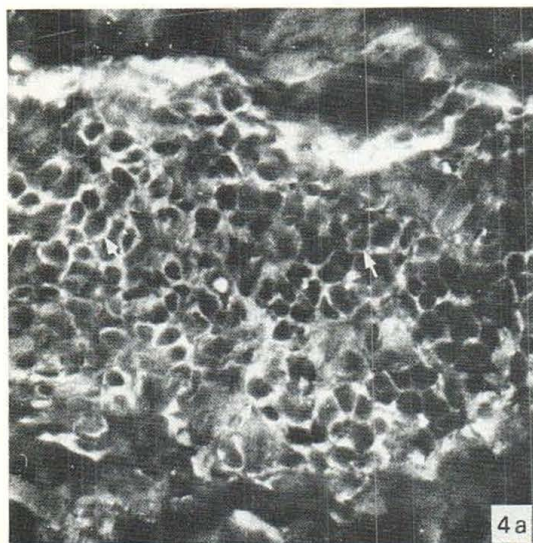
Fig. 2. Section of a lichen planus lesion incubated with OKT4 antibodies. A large proportion of the mononuclear cells are stained.  $\times 350$ .

Fig. 3a-b. Section of a lichen planus lesion (same as in Fig. 2) stained with IgG F (ab')<sub>2</sub> preparation of anti-T lymphocyte serum (a, red fluorescence) and with OKT8 antibodies (b, green fluorescence). Examples of identical cells indicated by arrows. Many of the T lymphocytes are OKT8<sup>+</sup>.  $\times 350$ .

clonal anti-T lymphocyte antibodies gave a rim-like membrane fluorescence to the cells. The OKT4 antibodies gave the weakest staining (Fig. 2) and OKT8 the strongest (Fig. 3). This is consistent with the data reported by Janossy et al. (17), studying mononuclear cells in normal lymphoid and jejunal tissues. The weak staining obtained with OKT4 made these antibodies unsuitable for double-staining experiments.

In sections of spleen, OKT3<sup>+</sup> as well as OKT4<sup>+</sup> and OKT8<sup>+</sup> cells were observed mainly in the periarteriolar sheaths of the white pulp. By examining adjacent sections of spleen, about twice as many OKT4<sup>+</sup> as OKT8<sup>+</sup> cells were found. The monoclonal antibodies did not stain any cells in tissue sections of liver or kidney.

In sections of the various psoriatic lesions, the highest proportions of OKT4<sup>+</sup> cells were found in



the perivascular infiltrates in the reticular dermis, and the lowest in the papillary dermis. Using double-staining, it was found that the overall proportion of HuTLA<sup>+</sup>/OKT8<sup>+</sup> cells in the psoriatic lesions was 15–25% (Fig. 4). Sections from different forms of psoriatic lesions all showed a similar distribution of HuTLA<sup>+</sup>/OKT8<sup>+</sup> lymphocytes in the dermis.

The band-like infiltrates of mononuclear cells in the dermis in lichen planus lesions also contained more OKT4<sup>+</sup> than OKT8<sup>+</sup> cells. Results obtained when adjacent sections were examined indicated that there were approximately twice as many OKT4<sup>+</sup> as OKT8<sup>+</sup> cells. The results obtained using double staining showed that 25–35% of the HuTLA<sup>+</sup> cells were OKT8<sup>+</sup> (Fig. 3).

In DLE lesions, large clusters of mononuclear cells are present in the reticular dermis, particularly surrounding hair follicles. The majority of these mononuclear cells was OKT4<sup>+</sup>. Double-stained preparations showed that 15–25% of the HuTLA<sup>+</sup> cells were OKT8<sup>+</sup>.

The OKM1 antibodies stained the highest numbers of cells in lesions of pustular and erythrodermic psoriasis (Table 1) (Fig. 5). In these lesions OKM1 and OKT8 both stained about the same numbers of cells in the dermis. Fewer OKM1<sup>+</sup> cells were detected in the lesions of exudative psoriasis, and very few in the stationary lesions of psoriasis vulgaris. There were also very few OKM1<sup>+</sup> cells in lesions of lichen planus and DLE. In the clinically most active lesions of psoriasis, some OKM1<sup>+</sup> cells were also present in the epidermis. OKM1 did not stain cells in either normal skin or in tissue sections

*Fig. 4 a–b.* Section of a stationary lesion of psoriasis vulgaris stained with IgG F(ab')<sub>2</sub> preparation of anti-T lymphocyte serum (*a*, red fluorescence) and with OKT8 antibodies (*b*, green fluorescence). Examples of identical cells indicated by arrows. A minority of the T lymphocytes are OKT8<sup>+</sup>. ×350.

*Fig. 5.* Section of a pustular psoriatic lesion incubated with OKM1 antibodies. Stained cells are seen in the dermis and a few also in the epidermis. ×350.

*Fig. 6.* Section of a lesion of psoriasis vulgaris incubated with OKT8 antibodies. OKT8<sup>+</sup> cells are distributed through the whole epidermis. ×140.

*Fig. 7.* Section of an exudative psoriatic lesion incubated with OKT8 antibodies. OKT8<sup>+</sup> cells are located in a dermal papillae and some also in the epidermis. ×350.

*Fig. 8.* Section of a lichen planus lesion (same as in Figs. 2–3) incubated with OKT8 antibodies. Many stained cells are seen in the dermis and some in the basal part of the epidermis. ×140.

of liver and kidney. OKM1 stained only a few cells in the red pulp areas in sections of spleen.

T lymphocytes could also be detected in the epidermis in sections from all the skin lesions studied (Table 1). A few epidermal T lymphocytes were usually also present in sections of unaffected skin. In double-stained preparations, 80–90% of epidermal HuTLA<sup>+</sup> cells were OKT8<sup>+</sup>. Sections of psoriatic lesions contained the highest numbers of epidermal T lymphocytes, distributed through the whole epidermis (Fig. 6), most abundant in the suprapapillary portions of the epidermis (Fig. 7). In lesions of lichen planus and DLE, the epidermal T lymphocytes were located mainly in the basal third of the epidermis (Fig. 8).

Sections incubated with PBS instead of monoclonal antibodies or anti-T lymphocyte serum, were not stained. Results of these control experiments showed that there was no cross-reactivity between the swine anti-mouse IgG and the anti-T lymphocyte serum, or between the swine anti-rabbit IgG and the murine monoclonal antibodies, as also indicated by results of double diffusion in agar. No inhibition of the staining was observed when the monoclonal antibodies were diluted in PBS with aggregated human IgG (4 mg/ml), indicating that the staining obtained could not have resulted from the binding of the monoclonal antibodies to receptors for the Fc-portion of IgG, previously shown to be present in sections of various skin lesions (7).

## DISCUSSION

The results obtained with OKT3 antibodies showed that T lymphocytes are the dominant mononuclear cells in lesions of psoriasis, lichen planus and DLE. Higher proportions of T lymphocytes were found in the stationary forms of psoriasis, compared with more clinically active psoriatic lesions. The results accord with our previous data obtained using hemadsorption of sheep erythrocytes to cryostat sections (4, 5, 6), an immunofluorescence test with a rabbit antiserum against T lymphocytes (3, 6) and staining for  $\alpha$ -naphthyl acetate esterase (ANAE) activity (3).

The results obtained with the monoclonal antibodies showed that both OKT4<sup>+</sup> cells (helper T lymphocytes) and OKT8<sup>+</sup> cells (suppressor/ cytotoxic T lymphocytes) are present in the dermal infiltrates in the skin lesions. In experiments with the double-staining technique the highest proportions

(25–35%) of suppressor/cytotoxic T lymphocytes (HuTLA<sup>+</sup>/OKT8<sup>+</sup>) were found in lesions of lichen planus and the lowest in lesions of psoriasis (15–25%) and DLE (15–25%). Accordingly, the majority of the T lymphocytes are helper cells (HuTLA<sup>+</sup>/OKT8<sup>-</sup>). When compared with the values in peripheral blood from normal controls (approximately 35% suppressor/cytotoxic cells) (20), there is a reduced number of suppressor/cytotoxic T lymphocytes in lesions of psoriasis and DLE. Low numbers of suppressor T lymphocytes in psoriatic lesions were also indicated by the results obtained using staining for ANAE activity (3).

However, the functional significance of these findings is unclear. It remains to be determined if a reduced number of suppressor cells implies a reduced suppressor function. The present results may also reflect 'normal' values concerning the distribution of suppressor/cytotoxic and helper cells in skin lesions. Nevertheless, Janossy et al. (16), performing *in situ* studies, reported that lymphocytic infiltrates in synovia from patients with rheumatoid arthritis consisted of a low percentage of OKT8<sup>+</sup> cells. The authors therefore hypothesized that an inappropriate T cell suppression might be a key factor in the development of rheumatoid arthritis. However, more studies about the tissue distribution of T lymphocyte subpopulations are necessary to determine the 'normal' overall ratio between suppressor/cytotoxic and helper cells in inflammatory lesions.

A reduced suppressor function has previously been postulated to be important in the pathogenesis of psoriasis (10, 13). However, conflicting reports on suppressor function of cells in peripheral blood from patients with psoriasis have been published. Sauder et al. (21) showed that mononuclear leukocytes pre-incubated with concanavalin A had a reduced capacity to suppress a one-way mixed lymphocyte culture. Other investigators (12, 15) have also reported a suppressor cell defect in psoriasis. On the other hand, De Pietro et al. (11), using OKT antibodies, found normal numbers of the various subpopulations of T lymphocytes in peripheral blood from patients with different types of psoriasis.

Intra-epidermal T lymphocytes in psoriatic lesions have previously been demonstrated (3). The present results showed that the majority of these T lymphocytes were OKT8<sup>+</sup> (suppressor/cytotoxic cells). In contrast to lesions of lichen planus and

DLE, the psoriatic epidermis contained OKT8<sup>+</sup> cells in all layers. Recently, it was found that the majority of these OKT8<sup>+</sup> cells express Ia-like antigens (data to be published). This raises the question of whether the epidermal suppressor/cytotoxic T lymphocytes in psoriatic lesions may represent a cellular reaction to stratum corneum antigens. Krogh & Tønder (18) demonstrated stratum corneum antibodies bound in the horny layer in psoriatic lesions as well as in the serum. They also showed that these antibodies could activate complement, indicating that a humoral immune reaction to stratum corneum antigens may be important in the pathogenesis of psoriasis. The demonstration of OKT8<sup>+</sup> T lymphocytes in the psoriatic epidermis may indicate that cellular immune reaction may also be of importance in psoriasis. However, normal skin contained some epidermal T lymphocytes that were preferentially OKT8<sup>+</sup>, and similar findings have been observed in normal gut epithelium (17). It therefore remains to be clarified whether the accumulation of OKT8<sup>+</sup> cells in the psoriatic epidermis reflects a cellular immune reaction, or a physiological affinity of the cells for epithelium.

Degeneration of basal keratinocytes is a common histopathological finding, both in lesions of lichen planus and DLE. In the present study of these dermatoses, T lymphocytes were found in the basal third of the epidermis, mainly as suppressor/cytotoxic cells. These cells might be involved in the destruction of the basal keratinocytes. In addition, the results obtained showed a dominance of helper T lymphocytes in the dermal infiltrates, giving further support to the hypothesis that cellular immunity is involved in the pathogenesis (4). Recently, Bhan et al. (2) reported that most T lymphocytes in the dermal infiltrates of lichen planus belong to the helper/inducer subpopulation.

The OKM1 antibodies do not seem to react with tissue macrophages, since the antibodies stained only a few cells in sections of spleen and none in liver, kidney and normal skin. This was further substantiated by the finding that, except in lesions of very active psoriasis, OKM1 only stained a few cells in sections of the various skin lesions. We have previously demonstrated the presence of many macrophages in lesions of lichen planus (4), DLE (6) and psoriasis (3, 5), with most macrophages appearing in clinically active psoriatic lesions. The present results imply either that many macrophages in skin lesions are not derived from the blood, or

that the monocytes lose the antigen reacting with OKM1 when differentiating in the tissue. Another possibility may be that recruitment of local macrophages in active inflammatory skin lesions differs from recruitment of local macrophages in chronic inflammatory skin lesions.

ACKNOWLEDGEMENTS

This work was supported in part by grants from the Norwegian Research Council for Science and the Humanities and the Norwegian Psoriasis Association.

Thanks are due to Mrs I. Grimelund and Mrs H. Evensen for skilful technical assistance.

REFERENCES

1. Avrameas, S. & Ternynck, T.: The cross-linking of proteins with glutaraldehyde and its use for the preparation of immunoadsorbents. *Immunochemistry* 6: 53, 1969.
2. Bhan, A. K., Harrist, T. J., Murphy, G. F. & Mihm, Jr, M. C.: T cell subsets and Langerhans cells in lichen planus: *in situ* characterization using monoclonal antibodies. *Br J Dermatol* 105: 617, 1981.
3. Bjerke, J. R.: *In situ* characterization and counting of mononuclear cells in lesions of different clinical forms of psoriasis. *Acta Dermatovener (Stockholm)* 62: 93, 1982.
4. Bjerke, J. R. & Krogh, H. K.: Identification of mononuclear cells *in situ* in skin lesions of lichen planus. *Br J Dermatol* 98: 605, 1978.
5. Bjerke, J. R., Krogh, H. K. & Matre, R.: Characterization of mononuclear cell infiltrates in psoriatic lesions. *J Invest Dermatol* 71: 340, 1978.
6. — *In situ* identification of mononuclear cells in cutaneous infiltrates in discoid lupus erythematosus, sarcoidosis and secondary syphilis. *Acta Dermatovener (Stockholm)* 61: 371, 1981.
7. — Factors mediating the binding of immune complexes to cryostat sections of psoriatic lesions. *Int Arch Allergy Appl Immunol* 68: 358, 1982.
8. Breard, J., Reinherz, E. L., Kung, P. C., Goldstein, G. & Schlossman, S. F.: A monoclonal antibody reactive with human peripheral blood monocytes. *J Immunol* 124: 1943, 1980.
9. Burg, G., Hoffmann-Fezer, G., Nikolowski, J., Schmoeckel, C., Braun-Falco, O. & Stünkel K.: Lymphomatoid papulosis: A cutaneous T-cell pseudolymphoma. *Acta Dermatovener (Stockholm)* 61: 491, 1981.
10. Cormane, R. H., Hunyadi, J. & Hamerlink, F.: The role of lymphoid cells and polymorphonuclear leukocytes in the pathogenesis of psoriasis. *In Psoriasis.*

Proceedings of the Second International Symposium (ed. E. M. Farber & A. J. Cox). p. 47. Yorke Medical Books, New York, 1976.

11. DePietro, W. P., Berger, C. L., Harber, L. C. & Edelson, R. L.: Normal numbers of phenotypic helper, suppressor, and total T cell populations in psoriasis vulgaris: Quantitation by monoclonal antibodies. *J Am Acad Dermatol* 5: 304, 1981.
12. Gladman, D. D., Keystone, E. C., Russel, M. L. & Schachter, R. K.: Impaired antigen-specific suppressor cell activity in psoriasis and psoriatic arthritis. *J Invest Dermatol* 77: 406, 1981.
13. Guilhou, J. J., Meynadier, J. & Clot, J.: New concepts in the pathogenesis of psoriasis. *Br J Dermatol* 98: 585, 1978.
14. Holden, C. A., Morgan, E. & MacDonald, D. M.: Categorization of T lymphocyte subsets in mycosis fungoides using monoclonal antisera on cutaneous tissue sections: the demonstration of a predominant helper cell population. *Br J Dermatol* 105: 12, 1981.
15. Hunyadi, J., Dobozy, A., Kenderessy, A. S. & Simon, N.: Suppressor function of peripheral blood mononuclear cells in patients with psoriasis vulgaris. *J Invest Dermatol* 75: 217, 1980.
16. Janosy, G., Duke, O., Poulter, L. W., Panayi, G., Bofill, M. & Goldstein, G.: Rheumatoid arthritis: A disease of T-lymphocyte/macrophage immunoregulation. *Lancet* ii: 839, 1981.
17. Janosy, G., Tidman, N., Selby, W. S., Thomas, J. A. & Granger, S.: Human T lymphocytes of inducer and suppressor type occupy different microenvironments. *Nature* 288: 81, 1980.
18. Krogh, H. K. & Tønder, O.: Stratum corneum antigens and antibodies. *In Immunopathology of the Skin* (ed. E. H. Beutner, T. P. Chorzelski & S. F. Bean), p. 413. John Wiley & Sons, New York, 1979.
19. Matre, R. & Tønder, O.: An improved method for the detection of human T lymphocytes in tissue sections. *J Immunol Methods* 38: 53, 1980.
20. Reinherz, E. L. & Schlossman, S. F.: The differentiation and function of human T lymphocytes. *Cell* 19: 821, 1980.
21. Sauder, D. N., Bailin, P. L., Sundeen, J. & Krakauer, R. S.: Suppressor cell function in psoriasis. *Arch Dermatol* 116: 51, 1980.
22. Stewart, G. A., Smith, A. K. & Stanworth, D. R.: Biological activities associated with the Fab<sub>b</sub> fragment of rabbit IgG. *Immunochemistry* 10: 755, 1973.

Received April 1, 1982

J. R. Bjerke, M.D.  
 Department of Dermatology  
 N-5016 Haukeland sykehus  
 Norway