

intervals, involving the lips, the hands and feet as well as the glans penis. Disease-free intervals were of short duration, lasting usually only a few weeks.

The severity of the skin and mucous membrane changes required hospitalization on various occasions. Onset of an attack was stereotypic: after a few days with a flu-like syndrome, blisters appeared on the mucous membranes, followed by typical target lesions on the hands and feet.

Exhaustive laboratory investigations during the attacks and in the symptom-free intervals disclosed no abnormalities apart from a slightly elevated ESR and a discrete leukocytosis with a relative lymphocytosis. All other investigations, such as attempted virus isolation from the lesions and complement fixation tests for numerous viral and bacterial antibodies were repeatedly negative or normal.

Over the last few years, a vast number of therapeutic measures had been employed with no or almost no effect. Treatment included administration of gamma-globulins, vaccination with polio and herpes virus, as well as immunostimulation with corynebacterium parvum, levamisol and others. More conventional therapy included systemic corticosteroids and adrenocorticotropine. No treatment altered the course of the disease or prevented recurrence.

In October 1981, during another attack, our patient was treated with thalidomide (Grünenthal, Stolberg, W-Germany), starting with 200 mg daily. Within a few days, skin and mucous membrane lesions healed and the dose was lowered to 100 mg. With this dose the patient has been completely free of disease since then, despite a flu-like syndrome in January 1982.

COMMENT

The treatment of erythema multiforme is unsatisfactory, especially in its recurrent forms. Corticosteroids may be necessary, although side effects of this therapy have to be weighed against its benefits (4).

Since its introduction to the therapy of leprosy reactions and despite its teratogenic properties (6), thalidomide has provoked renewed interest as an immunomodulating agent in recent years. It has been used with favourable results for the treatment of discoid lupus erythematosus (1) and various other dermatological disorders (5).

As shown in our case, it also appears to be effective in erythema multiforme, although our observation still requires confirmation by other cases treated with this substance.

In view of the potent teratogenic properties of thalidomide, precautions have to be taken to prevent pregnancy if women are being treated with the substance. Another serious side effect of thalidomide to be considered is the peripheral neuropathy seen in some cases (3). Therefore, neurological ex-

amination before and during therapy would seem to be advisable.

REFERENCES

1. Barba-Rubio, J. & Franco-Gonzalez, F.: Lupus eritematoso discoide y talidomida. *Dermatología Rev Mex* 19: 131, 1975.
2. Champion, R. H.: Erythema multiforme. In *Textbook of Dermatology* (ed. A. Rook) Part 1, p. 959, 1979.
3. Mellin, G. W. & Katzenstein, M.: The saga of thalidomide. Neuropathy to embryopathy, with case reports of congenital anomalies. *N Engl J Med* 267: 1184 and 1238, 1962.
4. Rasmussen, J. E.: Erythema multiforme in children. Response to treatment with systemic corticosteroids. *Br J Dermatol* 95: 181, 1976.
5. Samsøen, M., Grosshans, E. & Basset, A.: La thalidomide dans le traitement du lupus érythémateux chronique (L.E.C.). *Ann Dermatol Vénéreol* 107: 515, 1980.
6. Sheskin, J.: Thalidomide in the treatment of lepra reactions. *Clin Pharmacol Ther* 6: 303, 1965.

A Rosacea-like Eruption Induced by Tigason (Ro 10-9359) Treatment

Enrico Crivellato

*Department of Dermatology,
University of Trieste, I-34125 Trieste, Italy*

Received April 7, 1982

Abstract. A 67-year-old male patient, with a history of palmar psoriasis for 8 years, developed a rosacea-like eruption during Tigason (Ro-10-9359) treatment. Strict relationship between Tigason intake and skin symptoms was proved by double introduction of the drug and the patient's previous history. This retinoid side effect is very unusual and we are unable to give any explanation for it.

Key words: Rosacea-like eruption; Tigason (Ro-10-9359); Retinoid dermatitis

We were able to observe a rosacea-like eruption in a 67-year-old patient treated with Ro-10-9359 (Tigason, Hoffmann-La Roche) because of his palmar psoriasis.

The case reported here represents a very unusual side effect of retinoid management.




Fig. 1. Clinical picture.

CASE REPORT

A 67-year-old male out-patient, weighing 77 kg, and with a history of palmar psoriasis for 8 years, started on Tigason treatment.

He had formerly been managed with PUVA, Retinoid and PUVA (Re-PUVA) and topical salicylic ointments.

The Tigason schedule was as follows: the drug was initially administered in a dose of 75 mg/day. After 17 days of medication, palmar hyperkeratosis showed marked improvement and Tigason was reduced to 50 mg/day. Ten days later, Tigason was again reduced to a daily dose of 25 mg. A few days later, the patient developed an erythema accompanied by papulopustular crops, gradually extending over his forehead, cheeks, nose and chin. The pustules were particularly widely scattered on the forehead, in a follicular pattern. Telangiectasiae were also present (Fig. 1). The eruption on the face was accompanied by a painful sensation. Neither itching nor burning were reported by the patient.

Microscopic examination of a papular lesion revealed the following changes: a normal epidermis; dilated follicular ducts plugged by keratinous material; dilated blood vessels in the upper dermis; a thick polymorphous inflammatory infiltrate particularly localized around follicles and sebaceous glands; a marked basophilic degeneration of dermal collagen bundles (Fig. 2).

Tigason was immediately stopped and skin symptoms improved and disappeared within 3 weeks, without any topical or systemic therapy.

In agreement with the patient, Tigason was again ad-

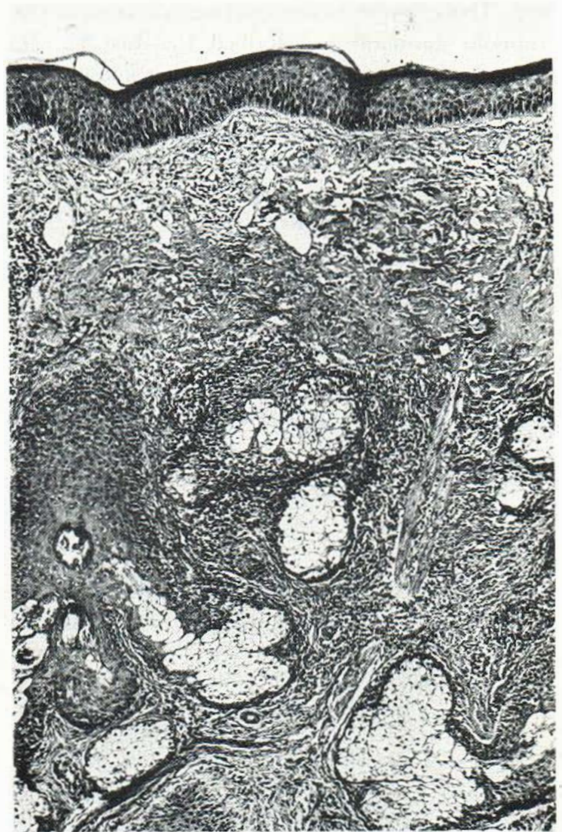

Fig. 2. Microscopic picture (HE, $\times 40$).

ministered in a daily dose of 50 mg. The same eruption reappeared immediately, but now the erythema was darker than previously. Tigason was stopped, but clearing was incomplete after 2 weeks of intermission. At this time the patient requested Tigason again due to a worsening of his palmar hyperkeratosis. The patient was given the drug 25 mg/day for one week. The erythema changed into a bluish shade; only a few new papules and pustules appeared. Tigason was definitively stopped and exanthema subsided gradually and disappeared completely within 3 weeks.

A careful anamnesis revealed that the patient had complained of the same eruption during previous Re-PUVA treatment. At that time skin symptoms were so mild that they passed unnoticed. They cleared spontaneously after Tigason was stopped.

DISCUSSION

The case of rosacea-like eruption reported here seems strictly dependent upon Tigason intake. A definite relationship between the drug and the skin eruption was proved by double introduction of the

drug. This exanthema does not seem related to the "retinoid dermatitis" described by Rüst (1, 2). There is no connection with any other known side effect of retinoids. We cannot give an explanation for the pathogenesis of the case reported here.

REFERENCES

1. Rüst, O., Ruffi, Th. & Forrer, J.: Erste Erfahrungen mit dem Vitamin-A-Säure-Derivat Ro-10-9359 bei Virusepitheliomen. *Schweiz Med Wochenschr* 109: 1914, 1979.
2. Rüst, O. & Ruffi, Th.: Nebenwirkungen des oralen Retinoids Ro-10-9359 in der nicht erkrankten Haut des Psoriatikers: die "Retinoid-Dermatitis". *Schweiz Med Wochenschr* 109: 1921, 1979.

Pemphigus erythematosus Induced by Thiopronine

Alberto Alinovi,¹ Donata Benoldi¹
and Paolo Manganelli²

¹Department of Dermatology, University of Parma, School of Medicine, and ²IInd Medical Division, "Ospedali Riuniti" of Parma, Parma, Italy

Received March 2, 1982

Abstract. A patient affected by rheumatoid arthritis developed pemphigus erythematosus after 14 months of treatment with thiopronine. The lesions healed spontaneously after 4 weeks' withdrawal of the drug. Whereas

the pemphigus erythematosus induced by D-penicillamine is a quite rare but well documented side effect, we believe our case to be the first one reported as being due to thiopronine. It is very interesting to note that the two drugs are very similar with regard to chemical structure, mechanism of action, therapeutic indications and also side effects.

Key words: Pemphigus erythematosus; Thiopronine; Drug reaction

D-penicillamine and other SH-SS drugs are being used increasingly in the management of rheumatoid arthritis. However, the clinical efficacy of agents such as D-penicillamine, thiopronine and pyrithioxine is often associated with several and relevant side effects (6, 7, 8, 1). As far as the cutaneous complications are concerned it has been noted that treatment with D-penicillamine can induce bullous lesions consistent with pemphigus vulgaris or pemphigus foliaceus and pemphigus erythematosus (10). On the other hand, a review of the pertinent literature has not revealed any case of pemphigus developing during treatment with thiopronine. We therefore deem it important to report a case of pemphigus erythematosus in a patient affected by rheumatoid arthritis as a result of a prolonged treatment with thiopronine.

CASE REPORT

M. M., a 66-year-old man, was found to be affected by serum-negative, polyarticular rheumatoid arthritis, second functional stage, in 1980. In August, 1980, treat-

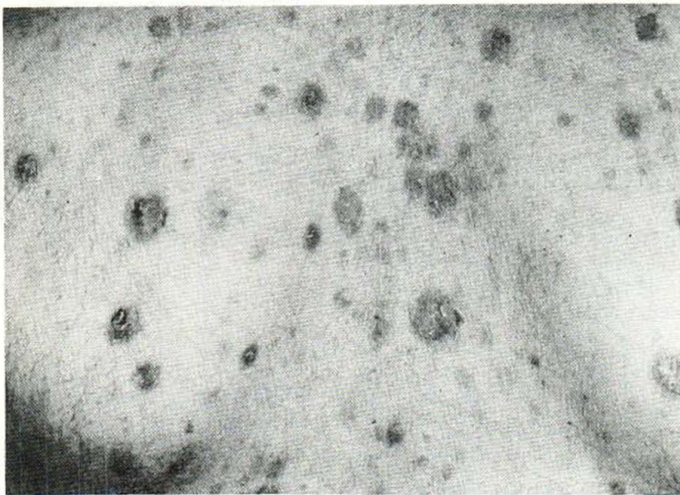


Fig. 1. Clinical picture.