

## DERMATITIS HERPETIFORMIS WITH LINEAR IgA DEPOSITION: ULTRASTRUCTURAL LOCALIZATION OF *IN VIVO* BOUND IgA

Yuuichiro Yamasaki,<sup>1</sup> Takashi Hashimoto<sup>2</sup> and Takeji Nishikawa<sup>2</sup>

<sup>1</sup>Section of Dermatology, Ogikubo Hospital, Tokyo 167, and <sup>2</sup>Department of Dermatology, Keio University School of Medicine, Tokyo 160, Japan

**Abstract.** Ultrastructural localization of bound IgA in the skin of a patient suffering from dermatitis herpetiformis with linear IgA deposition at the dermo-epidermal junction was studied using the horseradish peroxidase labelled antibody method. The reaction products were observed as electron-dense materials, not only immediately below the cytomembrane of the basal cells but also in the uppermost dermis just below the basal lamina. The major portion of the lamina lucida was free of the reaction products. These findings suggest a diversity in the mode of IgA deposition and the possibility of the presence of different antigens in the basement membrane zone, to which IgA class antibodies may be bound respectively.

**Key words:** Dermatitis herpetiformis; Linear IgA deposition; Ultrastructural localization

The presence of *in vivo* bound IgA in the skin of patients with dermatitis herpetiformis (DH) is now regarded as one of the reliable diagnostic criteria for establishing the diagnosis of DH (1). Direct immunofluorescence (DIF) studies have shown two different patterns of IgA deposition: i.e., granular deposition in the dermal papillae and linear deposition in the basement membrane zone (BMZ) (2-4). Furthermore, the ultrastructural localization of the linear type IgA deposition have been studied in detail in recent investigations (3, 5-7).

In the present report, a case of DH with linear IgA deposition is described and the ultrastructural localization of the bound IgA investigated using the horseradish peroxidase (HRPO) labelled antibody method.

### CASE REPORT

A 30-year-old housewife became aware of a bright reddish rash on the head, neck, trunk and the limbs. The rash was marked especially on the intertriginous areas. It first broke out in October 1980 and spread gradually. The patient visited Kawaguchi Saiseikai Hospital in January 1981. She was treated with topical application of be-

tamethasone valerate ointment. However, the exudative erythema spread centrifugally, and revealed a tendency to coalesce.

She was referred to our hospital for diagnosis with immunopathology. Her body surface was by then covered with exudative erythema (Fig. 1). There were small papules and blisters, only two or four in number, on some areas of the exudative erythema (Fig. 2). She complained of slight itching, but had no gastro-intestinal discomfort.

Most of the laboratory tests showed normal values; these included urinalysis, stool examination, complete blood count and routine chemical analyses of the serum. The serum immunoglobulin and complement levels differed slightly from the normal range i.e., IgG 1665 mg/dl, IgA 430 mg/dl, IgM 120 mg/dl, C3 50 mg/dl and C4 51 mg/dl. Histocompatibility antigen studies revealed HL-A A26, AW33, BW44, BW61, CW3 and DRW9. HL-A B8 was not detected. A precise examination of the gastro-intestinal tract was not performed.

Oral administration of dapsone (DDS) 75 mg/day worked dramatically and in few days the erythematous areas became pigmented. However, when the daily dose was reduced to 50 mg, the rash recurred. The patient is now undergoing treatment with oral administration of 75 mg of DDS as a maintenance dose.

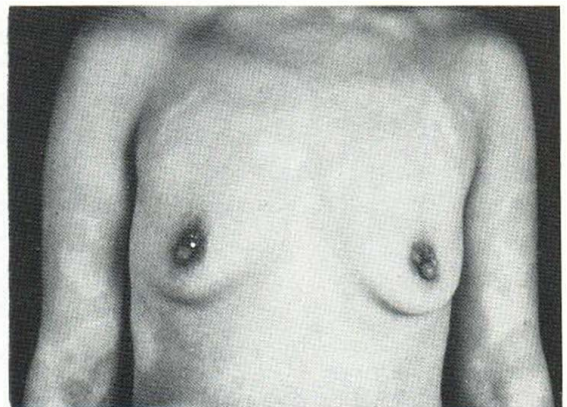


Fig. 1. Exudative erythemata covering the body surface.

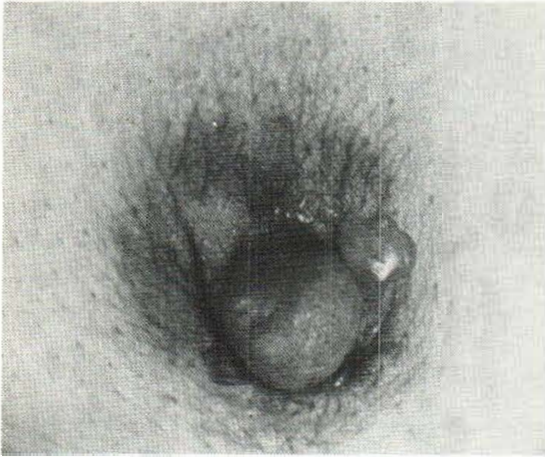


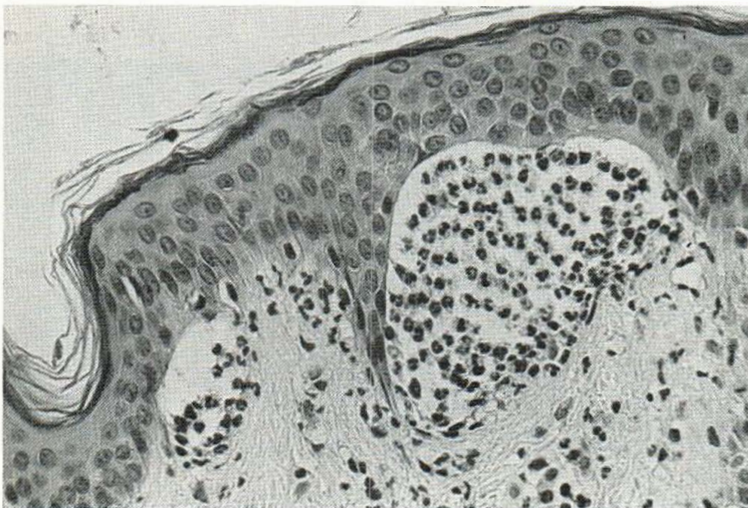Fig. 2. Occasional blister formation on the erythematous skin.

#### Histopathological findings

A hematoxylin-eosin stained section of the biopsy specimen obtained from erythematous skin with small blisters was examined. The epidermis revealed no evidence of intercellular edema or acantholysis. Papillary microabscesses consisting of polymorphonuclear leukocytes were observed, which is characteristic of DH (Fig. 3). Subepidermal blister formation was also observed. There was only slight mononuclear cell infiltration in the dermis.

#### Immunofluorescence studies

DIF studies on the biopsy specimens obtained from the erythematous and normal-appearing skin revealed pure IgA deposition at the BMZ in a linear fashion (Fig. 4). Circulating autoantibodies against BMZ of IgA and IgG class were, however, not demonstrated when using fresh human skin as substrates.



## DISCUSSION

The clinical feature of the present case was characterized by generalized exudative erythematata with occasional papulovesicular eruption and blister

### Ultrastructural Localization of Bound IgA

#### Materials and methods

The biopsy specimens obtained from erythematous and normal-appearing skin were fixed with McLean-Nakane's periodate-lysine-paraformaldehyde (PLP) fixative (8), and were prepared for the immunologic examination according to the previously reported method (9). Briefly, the 6- $\mu$ m cryostat sections were cut and were heated with HRPO-labelled anti-human IgA rabbit antiserum (Dakopatts Co., Denmark; Lot 030 and 108, 5 $\times$  in dilution). They were then incubated in 3,3'-diaminobenzidine (DAB)-H<sub>2</sub>O<sub>2</sub> solution for 10 min, followed by dehydration in graded alcohols and embedding in epoxy resin with the inverted gelatin capsule method. Ultrathin sections were observed with a JEM 100B electron microscope. Appropriate controls were run in each experiment.

#### Results

The reaction products were deposited along the dermo-epidermal junction in a linear fashion (Fig. 5). Approximately 0.1  $\mu$ m wide parallel lines of the electron density of the deposited reaction products were observed, not only immediately below the cytomembrane of the basal cells but also in the sub-lamellar region of the upper dermis (Fig. 6). The major portion of the lamina lucida was free of the reaction products (Fig. 6). The linear IgA deposition appeared to have such periodicity of electron density as was seemingly in accordance with the scattered half-desmosomes along the cytomembrane of basal cells (fig. 6). Controls were free of the reaction products in the dermo-epidermal junction.

Fig. 3. Papillary microabscesses consisting of polymorphonuclear leukocytes (H & E stained section).

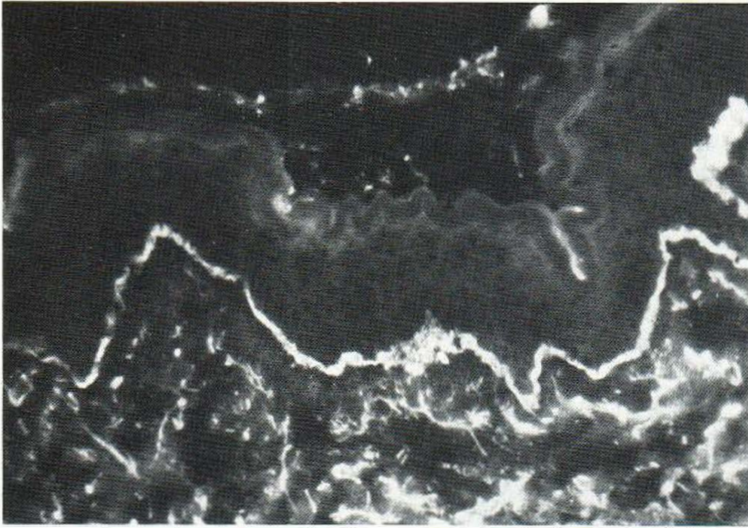


Fig. 4. Direct immunofluorescence. Linear IgA deposition at the dermo-epidermal junction.

formation and by the considerable improvement following oral administration of DDS. Histopathology revealed subepidermal blister formation and papillary neutrophilic microabscesses. Linear IgA deposition at the BMZ was demonstrated by DIF studies. Based on these findings, the diagnosis of DH with linear IgA deposition was made.

Since the first descriptions of immunoglobulins (10) and IgA (11) in the skin of patients with DH, numerous studies on the IgA deposition have accumulated (2-4, 12). It is now widely accepted that there are two types of IgA deposition in the dermo-epidermal junction of the lesional and non-lesional skin of DH, viz. granular dermal papillary IgA deposits and linear band-like deposits. It has also been pointed out that in the case of linear IgA deposition, the clinical features sometimes resemble bullous pemphigoid (7, 13-15) and circulating IgA class anti-BMZ antibodies can be found (6). Chorzelski et al. (16) therefore classify such cases as a unique disease entity, using the term "Adult form of linear IgA bullous dermatosis", whereas Yaoita et al. (5) and Pehamberger et al. (6) regard them as an atypical form of DH.

The present authors are of the opinion that it would be better to diagnose the case reported here as an atypical form of DH, since the conventional disease entity is preferable for the diagnosis of such rare and controversial cases.

Ultrastructural localization of the bound IgA has been classified into two types (5). One is sublaminar, in which the bound IgA is localized in the up-

permost dermis immediately below the basal lamina, while the other is laminar, in which the bound IgA is localized in the upper portion of the lamina lucida just below the cytomembrane of the basal cells (5). To date, the former type of deposition has been observed by Seah et al. (3), Pehamberger et al. (6) and the latter by Dabrowski et al. (7). IgA deposition of the latter, laminar, type and IgG deposi-

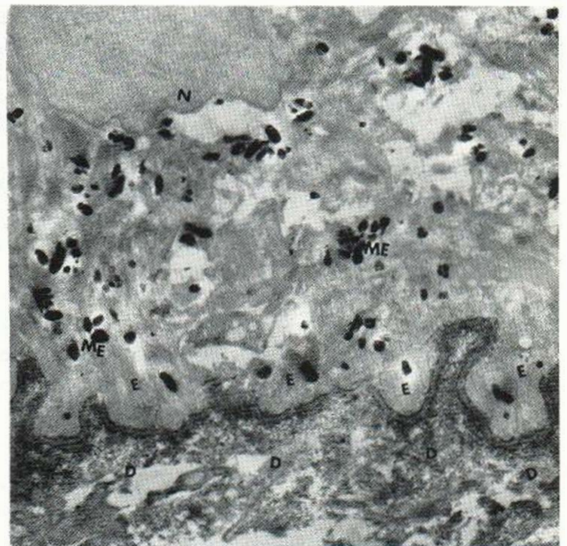


Fig. 5. HRPO-labelled antibody method for electron microscopy. Linear deposition of the reaction products along the dermo-epidermal junction (unstained, 9700). E) epidermis; N) nucleus; ME) melanin granules; D) dermis.

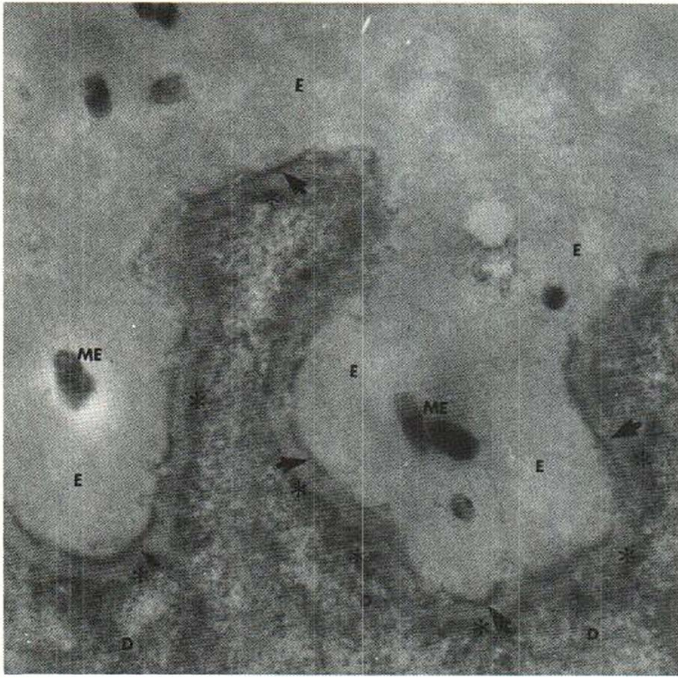


Fig. 6. High magnification. The reaction products were observed not only immediately below the cytomembrane of the basal cells (arrows), but also in the sublamellar region of the uppermost dermis (asterisk), with a periodicity apparently in accordance with the distribution of the half-desmosomes (unstained, 29 100 $\times$ ). E) epidermis; ME) melanin granules; D) dermis.

tion in the skin with bullous pemphigoid (BP) (17–19) can be demonstrated in an identical site. In the present case, the reaction products were deposited in both of the above-mentioned sites; i.e., not only in the uppermost dermis just below the basal lamina but also in the region immediately below the cytomembrane of the basal cells. Such a pattern of IgA deposition has not been reported previously, except that Chorzelski et al. referred to a couple of cases of bullous disease with linear IgA deposition, in which the immune deposits had been found both in and beneath the basal lamina in various lesions of the same patient and even in the same specimen in different areas (16).

The present authors speculate that these findings regarding the electron microscopic localization of the bound IgA may suggest the possibility of the existence of the various antigens in the BMZ to which IgA class antibodies may be bound. However, a completely satisfactory explanation of the various modes of IgA deposition, viz. sublamellar, lamellar, or both, must await a further accumulation of cases of DH with linear IgA deposition.

One other interesting finding in the immunoelectronmicroscopic study of the present case is that the reaction products were deposited with a periodicity which appeared to be in accordance with the half-

desmosomes along the basal cells. Although further study is needed, this finding would appear to tally with that of Yaoita et al. (20) who assumed the periodicity to be one correlating the sites of anchoring filaments.

#### ACKNOWLEDGEMENTS

The authors are grateful to Dr Hada, the chief physician of the Section of Dermatology, Kawaguchi Saiseikai Hospital, who kindly referred the present case to the authors for immunopathological study.

#### REFERENCES

1. Katz, S. I. & Strober, W.: The pathogenesis of dermatitis herpetiformis. *J Invest Dermatol* 70: 63, 1978.
2. Chorzelski, T. P., Beutner, E. H., Jablonska, S., Blaszczyk, M. & Triftshauser, C.: Immunofluorescence studies in dermatitis herpetiformis and its differentiation from bullous pemphigoid. *J Invest Dermatol* 56: 373, 1971.
3. Seah, P. P., Fry, L., Stewart, J. S., Chapman, B. L., Hoffbrand, A. V. & Holborow, E. J.: Immunoglobulins in the skin in dermatitis herpetiformis and coeliac disease. *Lancet* i: 611, 1972.
4. Fry, L. & Seah, P. P.: Dermatitis herpetiformis: An evaluation of diagnostic criteria. *Br J Dermatol* 90: 137, 1974.
5. Yaoita, H. & Katz, S. I.: Immunoelectronmicro-

- scopic localization of IgA in skin of patients with dermatitis herpetiformis. *J Invest Dermatol* 67: 502, 1976.
6. Pehamberger, H., Konrad, K. & Holubar, K.: Circulating IgA anti-basement membrane antibodies in linear dermatitis herpetiformis (Duhring): Immunofluorescence and immunoelectronmicroscopic studies. *J Invest Dermatol* 69: 490, 1977.
  7. Dabrowski, J., Chorzelski, T. P., Jablonska, S., Krainska, T. & Jarzabek-Chorzelska, M.: The ultrastructural localization of IgA in the skin of a patient with mixed form of dermatitis herpetiformis and bullous pemphigoid. *J Invest Dermatol* 70: 76, 1978.
  8. McLean, I. E. & Nakane, P. K.: Periodate-lysine-paraformaldehyde fixative, a new fixative for immunoelectronmicroscopy. *J Histochem Cytochem* 22: 1077, 1974.
  9. Yamasaki, Y.: Immunopathological study on perilesional pemphigus skin. A comparative study of light and electron microscopic localization of in vivo bound IgG and complement C3. *J Dermatol (Tokyo)* 8: 165, 1981.
  10. Cormane, R. H.: Immunofluorescent studies of the skin in lupus erythematosus and other diseases. *Pathologica Europaea* 2: 170, 1967.
  11. Van der Meer, J. B.: Granular deposits of immunoglobulins in the skin of patients with dermatitis herpetiformis. An immunofluorescent study. *Br J Dermatol* 81: 493, 1969.
  12. Holubar, K., Doralt, M. & Eggerth, G.: Immunofluorescence patterns in dermatitis herpetiformis. Investigations on skin and intestinal mucosa. *Br J Dermatol* 85: 505, 1971.
  13. Provost, T. T., Maize, J. C., Ahmed, A. R., Strauss J. S. & Dobson, R. L.: Unusual subepidermal bullous diseases with immunologic features of bullous pemphigoid. *Arch Dermatol* 115: 423, 1979.
  14. Van Joost, T., Faber, W. R., Westerhof, W. & de Mari, F.: Linear dermo-epidermal IgA deposition in bullous pemphigoid. *Acta Dermatovener (Stockholm)* 59: 463, 1979.
  15. Honeymann, J. F., Honeymann, A. R. m De la Parra, M. A., Pinto, A. & Egniguren, G.: Polymorphic pemphigoid. *Arch Dermatol* 115: 152, 1979.
  16. Chorzelski, T. P., Jablonska, S., Beutner, E. H., Bean, S. F. & Furey, N. L.: Linear IgA bullous dermatosis. In *Immunopathology of the Skin*. 2nd ed. p. 315. Wiley, New York, 1979.
  17. Holubar, K., Wolff, K., Konrad, K. & Beutner, E. H.: Ultrastructural localization of immunoglobulins in bullous pemphigoid skin. *J Invest Dermatol* 64: 220, 1975.
  18. Masutani, M., Ogawa, H., Taneda, A., Shoji, M. & Miyazaki, H.: Ultrastructural localization of immunoglobulins in the dermo-epidermal junction of patients with bullous pemphigoid. *J Dermatol (Tokyo)* 5: 107, 1978.
  19. Maciejewski, W. m Braun-Falco, O. & Scherer, R.: Immunoelectronmicroscopical localization of in vivo bound complement C3 in bullous pemphigoid with the use of peroxidase-antiperoxidase multistep technique. *Arch Dermatol Res* 26y: 205, 1979.
  20. Yaoita, H., Hertz, K. C. & Katz, S. I.: Dermatitis herpetiformis: Immunoelectronmicroscopic and ultrastructural studies of a patient with linear deposition of IgA. *J Invest Dermatol* 67: 69, 1976.

*Received November 20, 1981*

Y. Yamasaki M. D.  
Section of Dermatology, Ogikubo Hospital  
Imagawa 3-1-24, Suginami  
Tokyo 167  
Japan