

The treatment of severe psoriasis has received a great boost with the introduction of methotrexate, PUVA and etretinate (Tigason®). Some disadvantages, side effects and individual contra-indications to these agents are well known. For this reason the work recently published of Atherton et al. (1) is welcome. The peculiar antimitotic activity, apparently low toxicity (only neutropenia, easily controlled) and especially the lack of hepatic injury, makes razoxane a useful drug for investigative therapy in difficult or severe cases of psoriasis.

PATIENTS AND METHODS

During 6 months (April–October 1981), 36 patients with psoriasis resistant to or intolerant of PUVA, methotrexate or etretinate (Tigason Roche) were treated with razoxane (ICRF 159, Razoxin®) along the lines suggested by Atherton et al. (1). On 2 consecutive days, six doses of 125–250 mg each were administered with meals. Twenty-two patients had the disseminated (6 erythrodermic) and "unstable" type of psoriasis, most of them treated years ago with systemic corticosteroids. Two patients had pustular psoriasis—also post-corticosteroid oral administration—and the rest (12 patients) had psoriasis vulgaris. All female patients were older than 45 years and the age range of the males was 38–72.

Clinical photographs, skin punch and liver biopsies and Technetium-99 scans were performed in all patients. One case (male, 54 years, alcoholic) treated for 10 years with methotrexate, showed a typical precirrhotic liver fibrosis and another one (male, 56 years) had a year earlier had chronic granulomatous hepatitis (Au+) and was being treated with azathioprine and prednisone when a recurrent erythrodermic psoriasis flared up. This man had been treated for 3 years (1976–78) with methotrexate (1750 g altogether). Azathioprine and prednisone were stopped and the patient put on razoxane.

RESULTS AND COMMENTS

Clinical and laboratory tolerance were fairly good: the worse the case, the better the clinical results, i.e. erythrodermic (including the patient with chronic granulomatous hepatitis) and pustular psoriatics were cleared in 8–10 weeks. In no case did the white blood cell count fall below 2600 mm³. Routine laboratory tests showed no changes, including repeated liver biopsies (5-month interval) in the 2 cases mentioned above, who demonstrated "histological inactivation" in the chronic granulomatous hepatitis and no essential changes in the precirrhotic case. We did detect a special clinical improvement in all but 2 of the 7 associated chronic psoriatic arthritics. On the other hand, razoxane was of little use in "common fixed" psoriasis.

In summary, our therapeutic experience during 6 months allow us to suggest that razoxane is slower than methotrexate in its clinical response, but better tolerated and, as Baker (2) reported, the drug seems so far to be an excellent alternative for severe or resistant psoriatics.

Three cases unresponsive to etretinate and 2 more who experienced a severe alopecia (women) were put on razoxane, showed good tolerance and cleared in 8 weeks. Four patients who visited the beach when on razoxane therapy did not show any difference in their usual response to sunbathing.

ACKNOWLEDGEMENTS

The drug was kindly supplied—in part—through the courtesy of Dr J. C. A. Langtry, Pharmaceutical Division, ICI Ltd., England and of Mr A. A. Magni, ICI-Farma of Argentina.

REFERENCES

1. Atherton, D.J., Wells, R. S. Laurent, M. R. & Williams, Y. F.: Razoxane (ICRF 159) in the treatment of psoriasis. *Br J Dermatol* 102: 307, 1980.
2. Baker, H.: Report to the 3rd. International Psoriasis Symposium, Stanford, July 15, 1981 and personal communication.

The Effect of Etretinate on Fibronectin in Psoriatic Skin

J. Lauharanta, O. Salo,
L. Kanerva and A. Lassus

Department of Dermatology, University Central Hospital, SF-00170 Helsinki 17, Finland

Received December 9, 1981

Abstract. The distribution of fibronectin in psoriatic skin was studied in 6 patients during treatment with oral etretinate using indirect immunofluorescence technique. In untreated lesions fibronectin was clearly visualized in the dermo-epidermal junction (DEJ) and in the walls of papillary capillaries, and showed a reticular or fibrillar pattern in the dermis. In the horny layer there was some fluorescence which we regarded largely as unspecific. In all patients a transient accentuation of fibronectin accumulation in DEJ was seen after 3–7 days of treatment. Except for some decrease in the amount and intensity of capillary fluorescence, no other notable changes occurred in the fibronectin distribution during 4 weeks of treatment.

Key words: Fibronectin; Retinoids; Etretinate; Dermo-epidermal junction; Immunofluorescence

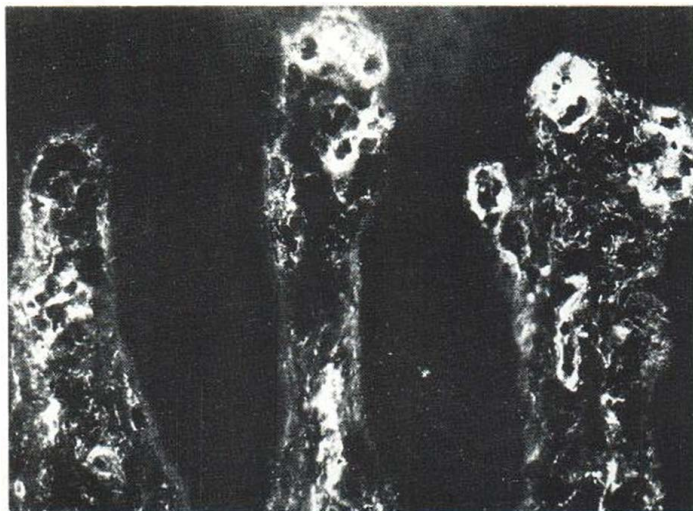


Fig. 1. Fibronectin immunofluorescence in untreated psoriasis. Dermal papillae are elongated and contain numerous enlarged capillaries with intense fluorescence in their walls. Dermo-epidermal junction (DEJ) shows continuous staining.

Retinoids are known to be able to regulate epidermal proliferation and differentiation (7). In addition to their effects on the epidermis, retinoids exert various effects on the dermal components, inducing dermal oedema, increasing the amount of amorphous ground substance, and activating dermal fibroblasts, macrophages, lymphocytes and Langerhans' cells (9).

Fibronectin is a physiological glycoprotein present in plasma in soluble form and in the extracellular matrix in insoluble form. It mediates cell to cell and cell to tissue matrix interactions (10). It occurs abundantly in various basement membranes (10). By the indirect immunofluorescence technique (IF) fibronectin can be visualized in normal human skin, where it is found mainly in the dermo-epidermal junction (DEJ) and in the dermis (2). In psoriasis the distribution quite closely resembles that in normal skin, but in this disease the epidermis also is reported to contain some fibronectin (2).

In order to study the effect of etretinate on fibronectin in psoriatic skin we monitored its distribution during treatment of the psoriasis.

MATERIALS AND METHODS

Six psoriatic patients (5 males and 1 female; age 50 ± 11 years) were included in the study. Five patients suffered from psoriasis vulgaris and one from psoriasis pustulosa; none had previously been treated with etretinate.

The specimens for immunofluorescence (IF) were 4 mm punch biopsy samples, taken before treatment and after 3 days and 1, 2 and 4 weeks of treatment with an aromatic

retinoid, etretinate (kindly supplied by F. Hoffmann-La Roche & Co. Ltd., Basle, Switzerland). Etretinate was administered at an initial daily dose of 0.8–0.95 mg/kg, which was later reduced according to the patients' response.

Indirect immunofluorescence technique

In the first step the biopsies were incubated with rabbit anti-fibronectin antiserum (Behringwerke, W. Germany) in dilution 1/80 in phosphate-buffered saline (PBS). After thorough washing with PBS the sections were stained with goat anti-rabbit IgG conjugate (Behringwerke) with an F/P ratio of 1.5, diluted 1/20 with PBS. Sections stained with only the goat anti-rabbit IgG conjugate served as controls. The fluorescence was studied with Leitz Orthoplan microscope with incident illumination, Xenon light source, two KP 490 excitation and OG 510 barrier filters.

RESULTS

The fluorescence in DEJ varied somewhat in width in various parts of the sections from untreated lesions, though always clearly discernible and occasionally appearing as a broad band. The numerous capillaries showed intense IF staining. The papillary dermis showed an intense reticular or fibrillar distribution of fibronectin in patients with psoriasis vulgaris (Fig. 1). In the patient with pustular psoriasis the fluorescence was more homogeneous, the reticular or fibrillar structure not being as clearly visualized as in normal skin or in the patients with psoriasis vulgaris. The fluorescence in the parakeratotic horny layers of the psoriatic plaques was not clearly distinguishable from that in control sections with anti-rabbit IgG conjugate.

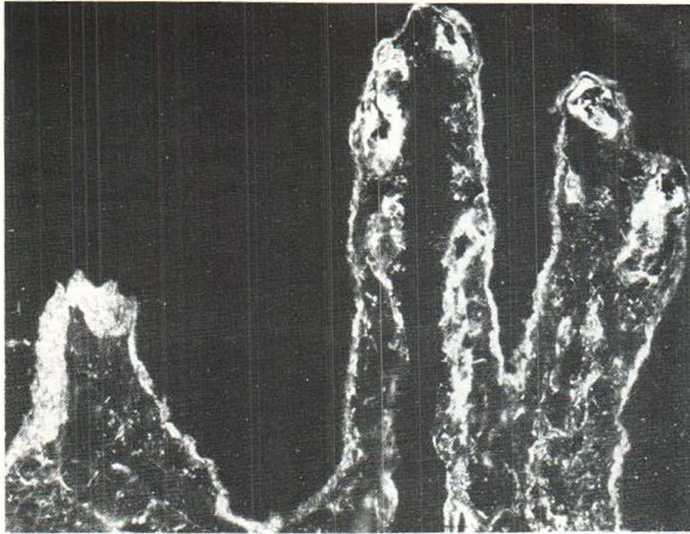


Fig. 2. Same lesion as in Fig. 1 after 3 days' treatment with etretinate. DEJ shows intense band-like staining.

In all patients the fibronectin pattern in DEJ was accentuated after 3-7 days of treatment. In most samples fibronectin was now present as a continuous broad band (Fig. 2). After 2 weeks of treatment the fibronectin IF in 5 of the 6 patients studied had reverted to resemble its pretreatment pattern (Fig. 3). In one patient, accentuation of the DEJ was still seen after 2 weeks but not after 4 weeks of treatment.

In some samples taken after 4 weeks of treatment, a therapeutic effect on psoriasis could be seen: capillaries were less striking and dermal papillae were less elongated. In these samples there was no fluorescence in the horny layer. In other re-

spects the fibronectin pattern in the dermis was virtually unchanged. In the patient with pustular psoriasis the fluorescence in the dermis became normalized during treatment.

DISCUSSION

Fyrand reported recently that in psoriasis, fibronectin is present not only in the dermis but also in the cornified layers as well as in some areas above the elongated dermal papillae (2). Since the epidermis does not produce fibronectin, he suggested that this IF-positive material is probably derived from plasma. It has been shown that the parakeratotic horny layer in psoriasis contains deposits of various plas-

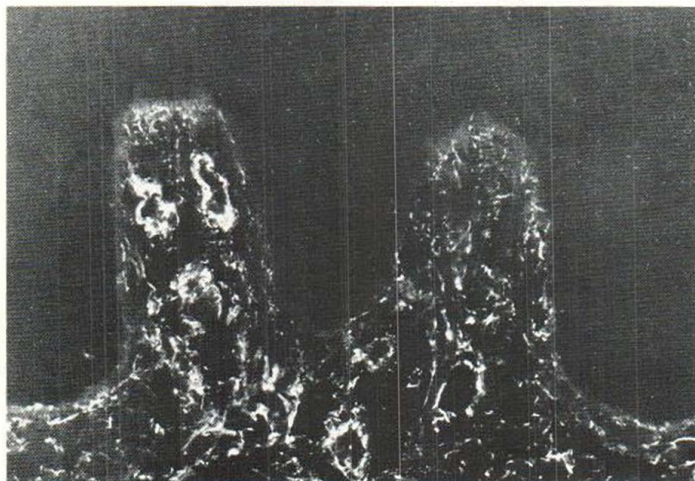


Fig. 3. Same lesion after 2 weeks' treatment with etretinate. Dermal papillae are less elongated and capillaries show normalization. Fibronectin staining in DEJ resembles that seen in untreated lesions.

ma proteins (6). Our impression was that the fluorescence seen in the psoriatic epidermis (especially in the parakeratotic horny layer) quite closely resembled that seen in control sections stained with anti-rabbit IgG conjugate only. We therefore think that this fluorescence is not caused by fibronectin alone but is largely a result of unspecific binding. In part it may represent the staining of autoantibodies against stratum corneum antibodies, as speculated by Fyrand (2).

Fibronectin is produced mainly by fibroblasts (8). Cell culture studies have suggested a stimulating effect of retinoid on fibronectin synthesis in fibroblasts. Retinoic acid induced the formation of cell surface-associated fibronectin in fibroblasts, which was accompanied by increased cell-to-substratum adhesiveness (4). Even in chick embryo chondrocyte culture a fibronectin-like surface glycoprotein was reported to be induced by retinoic acid (3). Under etretinate treatment, dermal fibroblasts show enhanced cytoplasmic activity (9). In the beginning of the treatment of psoriasis, fibronectin seemed to accumulate in the DEJ, suggesting that retinoid has a stimulatory effect on fibronectin formation *in vivo*, too.

Retinoids are also known to be able to modulate glycoprotein synthesis in biological membranes by inducing the incorporation of various sugar residues into glycoproteins (1), which might be one mechanism accounting for the effect of retinoid on fibronectin. This ability of retinoids has also been suggested to be a conceivable mechanism for the increase in fine granular, possibly mucoid material in the intercellular space of the psoriatic epidermis during the initial phase of treatment with etretinate (5). In our patients no fibronectin appeared in the epidermis during etretinate treatment, which suggests that the above-mentioned material does not consist of fibronectin-like cell surface-associated glycoprotein. Keratinocyte culture studies might give additional information about this subject.

So far, it is impossible to say whether the increase in fibronectin plays any part in the healing process. It may be only a secondary sign of the stimulatory effect of etretinate on dermal cells, especially fibroblasts, or it may be related in part to the previously observed oedematous changes in DEJ with rarefication of anchoring fibrils during initial etretinate treatment. On the other hand, it might have some influence on the dermo-epidermal interaction.

REFERENCES

1. DeLuca, L.: The direct involvement of vitamin A in glycosyl transfer reactions of mammalian membranes. *Vitam Horm* 35: 1, 1977.
2. Fyrand, O.: Studies on fibronectin in the skin. II. Indirect immunofluorescence studies in psoriasis vulgaris. *Arch Dermatol Res* 266: 33-41, 1979.
3. Hassel, J., Pennypacker, J., Yamada, K. & Pratt, R.: Changes in cell surface proteins during normal and vitamin A-inhibited chondrogenesis *in vitro*. *Ann NY Acad Sci* 312: 406, 1978.
4. Jetten, A. M., Jetten, M. E. R., Shapiro, S. S. & Poon, J. P.: Characterization of the action of retinoids on mouse fibroblast cell lines. *Exp Cell Res* 119: 289-299, 1979.
5. Kanerva, L., Lauharanta, J., Niemi, K.-M. & Lassus, A.: Fine structure of the intercellular space of psoriatic epidermis during retinoid (Ro 10-9359) and retinoid-PUVA treatment. *Acta Dermatovener (Stockholm)* 61: 319, 1981.
6. Kimura, S. & Nishikawa, T.: A further study on the mechanism of deposition of plasma protein in psoriatic scale. *Arch Dermatol Res* 268: 79-84, 1980.
7. Lauharanta, J.: Retinoids in the treatment and prevention of dermatoses and epithelial neoplasias. *Ann Clin Res* 12: 123-130, 1980.
8. Ruoslahti, E. & Vaheri, A.: Interaction of soluble fibroblast surface antigen with fibrinogen and fibrin. Identity with cold insoluble globulin of human plasma. *J Exp Med* 141: 497, 1975.
9. Tsambaos, D. & Orfanos, C.: Effects of oral retinoid on dermal components in human and animal skin. *In Retinoids. Advances in Basic Research and Therapy* (ed. C. Orfanos et al.). Springer-Verlag, Berlin, 1981.
10. Vaheri, A. & Mosher, F.: High molecular weight, cell surface-associated glycoprotein (fibronectin) lost in malignant transformation. *Biochim Biophys Acta* 516: 11, 1978.

A Three-year Follow-up Study of Psoriasis Patients Treated with Low Dosages of Etretinate Orally and Corticosteroids Topically

Machiel K. Polano,¹ Hendrik J. van der Rhee² and Jan Gerrit van der Schroeff¹

¹Department of Dermatology, University Medical Center, 2333 AA Leiden, and ²Department of Dermatology, Leyenburg Hospital, The Hague, The Netherlands

Received November 10, 1981

Abstract. Etretinate 0.5 mg/kg body weight combined with 0.1% triamcinolone acetonide and 5% salicylic acid in an O/W cream gave more than 70% improvement in