

22. Shao-Qiu Gu, Petrini, B., von Stedingk, L. V., Thyresson, N. & Wasserman, J.: Blood lymphocyte subpopulations in mycosis fungoides and their functions in vitro. *Acta Dermatovener (Stockholm)* 61: 487, 1981.

## Deposits of Complement and Immunoglobulins in Vessel Walls in Pyoderma gangrenosum

Susanne Ullman,<sup>1</sup> Poul Halberg and Jette Howitz<sup>1</sup>

<sup>1</sup>*Department of Dermatology, Rigshospital and Department of Medicine, Division of Rheumatology, Hvidovre Hospital, University of Copenhagen, Copenhagen, Denmark*

Received November 14, 1981

**Abstract.** Previous immunofluorescence studies on pyoderma gangrenosum (PG) proved negative. Biopsies from the ulcer edge of 8 patients with PG were examined by immunofluorescence microscopy. Deposits of complement C3 were seen in the vessel walls of all samples. IgM in three and IgA in one. Granular deposits of C3 were seen at the dermal-epidermal junction in 2 patients. Biopsies from clinically normal skin of 6 of the patients were negative. It is suggested that deposition of immune complexes in the dermal vessel walls may play a role in the pathogenesis of PG.

**Key words:** Pyoderma gangrenosum; Immunofluorescence; Vessel walls

Histopathological examination of pyoderma gangrenosum (PG) lesions has given conflicting results. Some authors have described vasculitis as an important feature (6, 7), whereas others found no inflammatory changes in the vessel walls (1, 2, 4). Several immunofluorescence studies did not find deposits of immunoreactants either in the vessel walls or at the dermal-epidermal junction (1-7).

### MATERIAL AND METHODS

Eight patients (7 women and one man) were included in the study. Besides PG, 2 patients had ulcerative colitis, one had Crohn's disease and one had seropositive, erosive deforming, nodular rheumatoid arthritis without active synovitis. Four patients had no other diseases.

Biopsy specimens were obtained from lesional skin at the edge of the ulcers. The red inflammatory zone was

preferred and the undermined destroyed part of the edge was avoided. Six patients had biopsies performed from clinically uninvolved skin of the buttock as well.

By direct immunofluorescence microscopy the biopsy specimens were examined for deposits of IgG, IgM, IgA and complement C3 (8). Material from lesional skin of 6 of the patients was also stained with hematoxylin-eosin.

### RESULTS

#### *Immunofluorescence microscopy*

Deposits of complement C3 were found in the dermal vessel walls of all samples of involved skin (Fig. 1). In three samples, deposits of IgM and, in one, deposits of IgA were found in the vessel walls. Granular deposits of C3 were seen in the dermal-epidermal junction in two biopsies. No deposits were found in any of the biopsies from clinically uninvolved skin.

#### *Light microscopy*

Endothelial cell proliferation and perivascular and intramural infiltrates of neutrophils and mononuclear cells were found in the dermal vessels of all six biopsies from lesional skin. Neither fibrinoid deposits, necrosis, nor nuclear dust were seen in any of the biopsies.

### COMMENT

Deposits of immunoreactants were found in the dermal vessels of all biopsies from lesional skin of patients with PG. C3 was found in all cases, and immunoglobulins were also found in some cases.

According to one report on a patient with paraproteinaemia and PG, vasculitis was found in the ulcer as well as in vasculitis lesions elsewhere in the skin. Immunofluorescence microscopy revealed deposits of IgG and complement C3 in the vessels of the vasculitic lesions (7). However, the ulcer itself was not examined by this technique. Several authors were unable to find deposits of immunoglobulins or complement in vessels of lesional skin of patients with PG (1-6). In this study, the indurated zone at the edge of the ulcer was biopsied in order to avoid the necrotic central area. In the other studies quoted the exact areas biopsied were not mentioned. Variations in biopsy sites may account for the discrepancies in the findings.

Fibrinoid deposits, necrosis and nuclear dust were not found by histopathological examination of lesional skin of our patients. On the other hand,

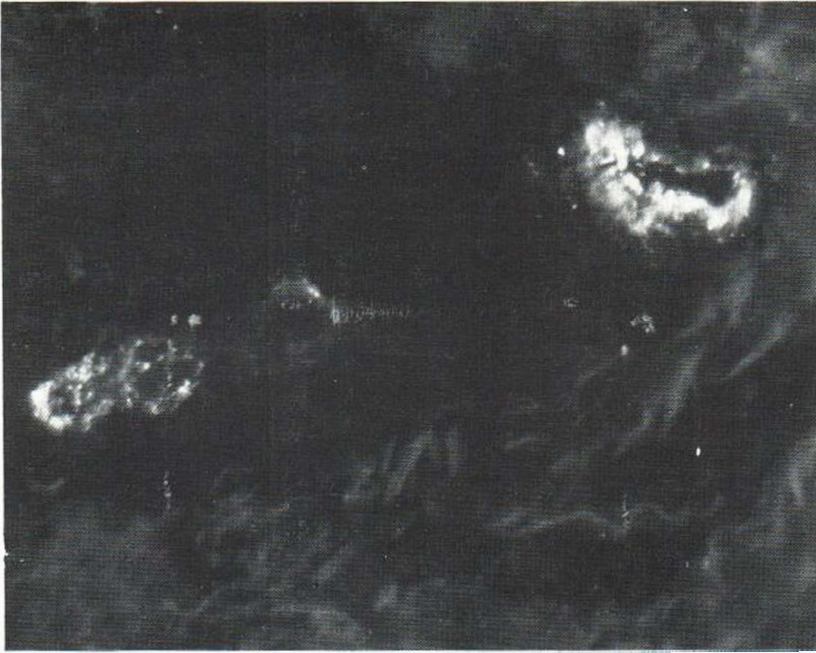


Fig. 1. Deposits of complement C3 in a dermal vessel at the edge of a lesion from a patient with pyoderma gangrenosum.

inflammatory changes in the dermal vessel walls were found in all patients examined.

Inflammatory vascular changes produced by the deposition of immune complexes may be of importance for the development of PG.

#### ACKNOWLEDGEMENT

This study was supported by a grant (No. 512-8196) from the Danish Medical Research Council.

#### REFERENCES

1. Dantzig, P. I.: Pyoderma gangrenosum. *N Engl J Med* 292: 47, 1975.
2. DeGeer, D. B.: Pyoderma gangrenosum. *Br J Dermatol* 101: 226, 1979.
3. Delescluse, J., deBast, C. L. & Achten, G.: Pyoderma gangrenosum with altered cellular immunity and dermonecrotic factor. *Br J Dermatol* 87: 529, 1972.
4. Holt, P. J. A., Davies, M. G., Saunders, K. C. & Nuki, G.: Pyoderma gangrenosum. *Medicine* 59: 114, 1980.
5. Romano, J. & Safai, B.: Pyoderma gangrenosum and myeloproliferative disorders. *Arch Intern Med* 139: 932, 1979.
6. Stolman, L. P., Rosenthal, D., Yaworsky, R. & Horan, F.: Pyoderma gangrenosum and rheumatoid arthritis. *Arch Dermatol* 11: 1020, 1975.
7. Thompson, D. M., Main, R. A., Beck, J. S. & Albert-Recht, F.: Studies on a patient with leucocytoclastic vasculitis 'pyoderma gangrenosum' and paraproteinaemia. *Br J Dermatol* 88: 117, 1973.
8. Ullman, S., Halberg, P. & Hentzer, B.: Deposits of immunoglobulin and complement in psoriatic lesions. *J Cutan Pathol* 7: 271, 1980.

#### Patch Testing with Perfume Mixture

N. K. Veien, T. Hattel,  
O. Justesen and A. Nørholm

*Dermatology Clinic, Vesterbro 99,  
DK-9000 Aalborg, Denmark*

Received December 10, 1981

**Abstract.** 145 of 1116 patients patch tested with the standard series of the International Contact Dermatitis Research Group, including the recently introduced perfume mixture, had positive patch test reactions to at least one of the traditional screening agents for fragrance allergy or to the perfume mixture. In 96 of the 145 patients the positive patch tests could be explained as being related to fragrance allergy. The perfume mixture was considered a useful screening agent for fragrance allergy. However, the results indicate that it is still necessary to employ several screening agents to detect this type of hypersensitivity.

Fragrance components of cosmetics and industrial products are common contact allergens, and it is