

## The Water-binding Capacity of Stratum corneum in Dry Non-eczematous Skin of Atopic Eczema

Ylva Werner,<sup>1</sup> M. Lindberg<sup>1,2</sup> and B. Forslind<sup>2</sup>

<sup>1</sup>Department of Dermatology, Södersjukhuset, S-10064 Stockholm, and <sup>2</sup>Department of Medical Biophysics, Karolinska Institute, Box 60400, S-104 01 Stockholm, Sweden

Received December 17, 1981

**Abstract.** The desorption curves obtained after full hydration of small discs of stratum corneum from dry non-eczematous skin in patients with atopic eczema (AE) were compared with normal specimens. The capacity to bind water was found to be reduced in the atopics.

**Key words:** Atopic dermatitis; Dry skin; Water-binding capacity

In atopic eczema (AE) the two most prominent clinical features are itching and dry skin. The dry skin is often seen on locations where there is no sign of eczema, i.e. the back and the outer aspect of the forearm. Itching is proposed to play a central role in the pathogenesis of AE and it is thought that at least a part of the sensation of itching is associated with the dry skin (8).

The presence of water is essential for the structure and function of the stratum corneum, thus an intact and optimally hydrated stratum corneum is necessary for a soft and flexible skin (2). There is still no satisfactory method for determining the absolute amount of water bound to stratum corneum in vivo (4). Indirect methods such as trans-epidermal water loss (TEWL) (6), measurement of electrical resistance and impedance (11) and surface contour analysis (surfometry) (4) have been used to determine the functional integrity of stratum corneum.

Scheuplein & Morgan (9) estimated indirectly the amount of water in normal human stratum corneum from the water desorption curves of fully hydrated tissue. In the present study a modification of their technique has been used to assess any difference arising in the water-binding capacity of the stratum corneum in clinically dry non-eczematous skin in AE, compared with normal skin.

## MATERIAL AND METHODS

### *Patients*

Twelve AE patients, aged 16–40 years, who had given their informed consent, were selected on specific clinical criteria for the desorption study. All patients thus had atopic eczema with dominantly flexural involvement and dry skin, but no signs of eczema on the back, the area for biopsy. The skin on the back was not treated with any ointment during one week before the investigation. A 3-mm punch biopsy was taken from each patient. Normal skin was obtained in the same way from the back of 12 age-matched healthy individuals without any family history of atopy and with no sign of dry skin.

For histological control of the dry skin in AE, biopsies were taken from 8 patients, using the same specific clinical criteria as in the desorption study.

### *Preparation of the stratum corneum*

The punch biopsies were placed in EDTA at 37°C. After 2 hours the epidermis was separated mechanically from the dermis and most of the viable epidermis was gently removed with a cotton swab. This thin sheet was placed on an aluminium foil in a closed sealed jar with 100% relative humidity for 8 days.

### *Desorption measurements*

A Mettler ME 22 microbalance was used in the desorption measurements. Silica gel was introduced into the weighing chamber as drying agent. The aluminium foil with the hydrated stratum corneum sheet was placed in the weighing chamber and the water desorption was recorded as the decrease in weight every 4 min for a period of 40 min. The specimen was then completely dehydrated at 60°C for 3 days, and the relative water content in stratum corneum per mg dry weight was calculated for each time interval. The AE specimens and the normal specimens were randomly chosen for weighing and the weighing room environment was constant during the experimentation period.

### *Histopathological study*

The biopsies were fixed in neutral formaldehyde solution and stained with H & E.

### *Statistical analysis*

Assuming a normal distribution for the values obtained, mean and standard deviations were calculated and Student's *t*-test was applied.

## RESULTS

The desorption curves for stratum corneum in AE and normal skin are shown in Fig. 1. Means and standard deviations for the water content per mg dry weight are plotted for each time interval. The same general pattern is seen in the curves of both AE and normal skin. At least two desorption phases are discerned, viz. a first, steep phase representing the free water desorption comprising

Table I. Mean values and standard deviations of the water content (mgH<sub>2</sub>O/mg dry weight)

Period of desorption (min)	Atopics (n=12)			Normal (n=12)		
	Mean	SD	Range	Mean	SD	Range
1	4.012	2.117	7.027	6.846	1.878	5.753
5	2.598	1.289	4.686	4.658	1.687	4.994
9	2.026	0.829	2.821	3.763	1.185	3.959
13	1.756	0.660	2.047	3.288	1.040	3.788
17	1.590	0.630	2.058	3.029	1.004	3.593
21	1.484	0.624	2.053	2.854	0.987	3.427
25	1.397	0.618	2.034	2.717	0.970	3.271
29	1.323	0.614	2.014	2.601	0.956	3.135
33	1.252	0.612	1.993	2.498	0.939	3.017
37	1.190	0.607	1.953	2.407	0.924	2.907
40	1.147	0.602	1.923	2.343	0.914	2.825

roughly the first 9 min. The curves then flatten out and this part represents desorption of bound water.

It is seen that normal skin contains more water at each time interval. However, the difference between the two groups decreases as a function of time. The range of measured values (Table I) for bound water is wider in the initial phase of desorption in both groups and wider in the normal skin than in AE throughout the entire period. There is a significant difference in the amount of bound water between the two groups both at one and at 40 min ( $p=0.05$ ).

The dry weights for the stratum corneum preparations were: for AE, 0.36 mg (SD 0.14) and, for normal skin, 0.33 mg (SD 0.11). There is no

significant difference between the two groups ( $p=0.05$ ).

In one of the biopsies taken for light microscopy, mild hyperkeratosis, patchy parakeratosis, and a slight dermal infiltrate of lymphocytes were found. No pathological changes were seen in the remaining histological specimens, compared with normal (E. Brehmer-Andersson).

## DISCUSSION

Most works on the water-holding capacity of stratum corneum have been based on studies of callus, which, however, is not representative of human stratum corneum. The choice of callus is

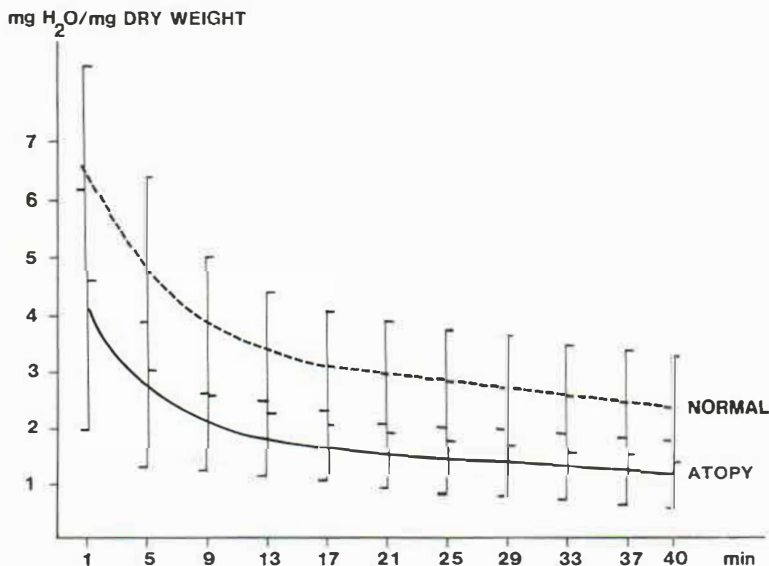


Fig. 1. The desorption curves for stratum corneum in AE and normal skin.

understandable, as the separation of stratum corneum from small fresh biopsies, i.e. ordinary clinical punch biopsies, has proved to be a difficult task. In our study, various methods for the isolation of stratum corneum sheet were tried and the present method was found to be the most reproducible one.

It is clinically well known that, besides eczema, patients with AE often present a dry skin. The development of this dryness is not fully understood at present.

Maintenance of moisture of stratum corneum depends mostly on the so-called "Natural Moisturizing Factors" (NMF), including pyrrolidone carboxylic acid, urea and inorganic salts. The beneficial effect of urea-containing ointments in the treatment of dry skin (10) supports the theory that some of these factors may be reduced in dry skin. However, this has not been proven.

Rajka (7) found a higher transepidermal water loss (TEWL) than normal both in eczema and in dry non-eczematous skin of the back of the hand in patients with AE. It has been suggested that the reason is a damaged barrier and quantitative alterations in the content of skin surface lipids (1, 8).

However, an increased TEWL does not prove a low content of water in the stratum corneum. Finley et al. (3) conclude that in the dry skin of AE, there are features of disturbed keratinization. They observed a reduced electrical impedance of stratum corneum which, paradoxically, implies an increased water content.

Using the method of S. D. S. gel electrophoresis and electron microscopy, Thaler et al. (12) investigated the keratin proteins in skin of AE patients, psoriatics, and normal persons. No differences were found between AE and normal skin. The histology of the dry skin in AE has been described (3, 5). Changes such as a slight acanthosis with patchy parakeratosis, in places a hypergranulosis but no frank eczema, have been reported from the outer aspect of the upper arm (3). The same results have been found in biopsies taken near the antecubital fossa (5).

In our investigation the histological changes in biopsies from the back were mild compared with earlier reports. It must be pointed out that the definition of skin dryness and "normal skin" in AE is the subject of the investigator's personal judgement. In the present study the patients were critically chosen after a thorough scrutiny of their recent

history and a searching evaluation of their skin status.

We performed this investigation to determine the water-binding capacity of stratum corneum in dry non-eczematous skin in AE and in normal skin. We found that normal stratum corneum bound more water per mg dry weight than did stratum corneum in AE. This seems to be valid for both free and bound water.

It was noted that the interindividual variations at each time interval of desorption were greater in the normal group than in the AE group. The most plausible explanation for this is normal biological variation. The dry weight of the stratum corneum preparations used for desorption measurement in this study did not differ between the two groups. This indicates that the preparation technique applied is reproducible and that it does not introduce any systematic error into the results. Thus, in conclusion, we can state that stratum corneum in dry non-eczematous skin of the back in patients with atopic eczema has a reduced water-binding capacity, compared with normal stratum corneum. The reason for this difference is not clear and needs to be further investigated.

#### ACKNOWLEDGEMENT

The present investigation was made possible by a generous grant from the trustees of the Lisa and Johan Grönberg Foundation.

#### REFERENCES

1. Abe, T., Ohkido, M. & Yamamoto, K.: Studies on skin surface barrier functions. Skin surface lipids and transepidermal water loss in atopic skin during childhood. *J Dermatol (Tokyo)* 5: 233, 1978.
2. Blank, I. H.: Factors which influence the water content of the stratum corneum. *J Invest Dermatol* 18: 433, 1952.
3. Finlay, A. Y., Nicholls, S., King, C. S. & Marks, R.: The "dry" non-eczematous skin associated with atopic eczema. *Br J Dermatol* 102: 249, 1980.
4. Marks, R. & Nicholls, S. C.: Drugs which influence the stratum corneum and techniques for their evaluation. *Clin Exp Dermatol* 6: 419, 1981.
5. Mihm, M. C., Soter, N. A., Dvorak, H. F. & Austen, F. K.: The structure of normal skin and the morphology of atopic eczema. *J Invest Dermatol* 67: 305, 1976.
6. Nilsson, G. E.: On the measurement of evaporative water loss. Methods and clinical applications. Linköping Studies in Science and Technology Dissertations, No. 11, and Linköping University Medical Dissertations, no. 48. Linköping, 1977.

7. Rajka, G.: Transepidermal water loss on the hands in atopic dermatitis. *Arch Dermatol Forsch* 251: 111, 1974.
8. Rajka, G.: *Atopic Dermatitis*. Saunders, London, Philadelphia and Toronto, 1975.
9. Scheuplein, R. J. & Morgan, L. J.: "Bound water" in keratin membranes measured by a microbalance technique. *Nature* 214: 456, 1967.
10. Swanbeck, G.: A new treatment of ichthyosis and other hyperkeratotic conditions. *Acta Dermatovener (Stockholm)* 48: 123, 1968.
11. Tagami, H., Ohi, M., Iwatsuki, K., Kanamaru, Y., Yamada, M. & Ichijo, B.: Evaluation of the skin surface hydration in vivo by electrical measurement. *J Invest Dermatol* 75: 500, 1980.
12. Thaler, M., Fuhuyama, K., Epstein, W. L. & Fisher, K. A.: Comparative studies of keratins isolated from psoriasis and atopic dermatitis. *J Invest Dermatol* 75 (2): 156, 1980.

## Sézary Syndrome: Relative Increase in T Helper Lymphocytes Demonstrated by Monoclonal Antibodies

J. Thivolet, R. Fulton, P. Souteyrand,  
M. Gaucherand and A. Claudy

U. 209 INSERM, Laboratoire de Recherche  
Dermatologique et Immunologie, Clinique  
Dermatologique, Hôpital Edouard Herriot,  
F-69374 Lyon Cédex 2, France

Received August 3, 1981

**Abstract.** Helper and suppressor T lymphocytes were measured in 7 patients with the Sézary syndrome and 6 patients with mycosis fungoides, by indirect immunofluorescence using monoclonal antibodies. A large relative increase in helper cells was found in the Sézary syndrome, while the results in mycosis fungoides were normal.

The Sézary syndrome is a rare systemic disease which presents as erythroderma and peripheral lymphadenopathy. A characteristic finding is the presence of large mononuclear cells with cerebriform nuclei in the peripheral blood and skin—the so-called Sézary cell. These cells have been shown to be thymus-derived lymphocytes (4, 5, 21). Mycosis fungoides is a related condition in which morphologically and immunologically identical cells initially preferentially infiltrate the skin and lymph nodes but are occasionally seen in the peripheral blood. It has been suggested that the two conditions are part of a spectrum of cutaneous T cell lympho-

ma, where the Sézary syndrome represents a leukaemic phase of mycosis fungoides (6). We have used monoclonal antibodies specific for T lymphocyte subsets to demonstrate that in the Sézary syndrome there is a large relative increase in T helper lymphocytes and that mycosis fungoides shows no similar imbalance of T lymphocyte subpopulations in peripheral blood.

## PATIENTS

Seven patients with typical features of the Sézary syndrome and persistent circulating Sézary cells were studied. There were 4 women and 3 men with an age range of 25–75 years. Peripheral blood Sézary cell counts varied from 7 to 52% of total white cells. Most of the patients had received various systemic treatments such as systemic corticosteroids, chemotherapy, leukopheresis and PUVA therapy. Six patients with histologically proven mycosis fungoides were studied—4 men and 2 women with an age range of 49–71 years. Four patients had plaque lesions only and 2 had, in addition, early tumours. One had superficial lymphadenopathy, but none had detectable circulating Sézary cells. All had received a range of conventional systemic therapies similar to the Sézary syndrome group. 20 sex- and age-matched healthy controls were included in the study.

## METHODS

Three monoclonal antibodies, produced by the Ortho Pharmaceutical Corporation, USA, named OKT3, OKT4 and OKT8, were kindly donated by Cilag-Chimie, France. These had been produced by the hybridoma technique in which myeloma cells are fused with spleen cells from mice immunized with human T lymphocytes. The myeloma cells subsequently produce highly specific IgG antibodies to surface antigens on human T lymphocytes and subsets (12). OKT3 identifies 100% of human peripheral T cells, OKT4 identifies the T helper/inducer subset and OKT8 identifies the suppressor/cytotoxic subset.

Mononuclear cells were separated from peripheral blood by "Ficoll-Paque" (Pharmacia) density centrifugation. After washing, the cells were suspended in RPMI-1640 supplemented with 5% foetal calf serum and 25 mM Hepes at a concentration of  $5 \times 10^6$  cells/ml. 10 microlitres of each reconstituted antibody (OKT3, OKT4, OKT8) was incubated with 200  $\mu$ l of the cell suspension on ice for 30 min. After washing, the cell pellet was incubated on ice for 30 min with 100  $\mu$ l of fluorescein-conjugated goat anti-mouse IgG (Nordic) which had been diluted 1 in 10 in RPMI-1640. Fluorescent cells were counted on a Leitz Orthoplan microscope and compared with the total number of cells.

Statistical analysis was carried out by Student's *t*-test.

## RESULTS

The mean percentage ( $\pm$  standard error of the mean) of OKT3+ cells was calculated. In the Sézary syn-