

IMMUNOFLUORESCENCE STUDIES ON C1q IN MAST CELLS

Ryoichi Igarashi,¹ Shigenori Sudo,¹ Masaaki Morohashi,¹
Seiji Takeuchi² and Yoshio Sato²

¹Department of Dermatology, Toyama Medical and Pharmaceutical University, Toyama and

²Department of Dermatology, Niigata University School of Medicine, Niigata, Japan

Abstract. Evidence has been obtained of deposition of complement component C1q in mast cells, by the immunofluorescence technique, using biopsy specimens from the scalp from 5 of 7 normal subjects and 14 of 17 patients with alopecia areata and also from skin lesions of 1 of 2 patients with urticaria pigmentosa studied. The fluorescence in mast cells was of a granular pattern in most instances. No deposition of immunoglobulins (IgG, IgA, IgM, IgE) or other complement components (C3, C4, C5, C9) was demonstrable in the mast cells. The specificity of the C1q deposition in mast cells was confirmed by various tests, viz., the blocking test, prerinse of tissue sections with bovine serum albumin-containing phosphate-buffered saline, absorption test of conjugates, C1q destruction test with urea or by heating, and the Ouchterlony method.

Key words: Mast cell; Complement component C1q; Immunofluorescence study

Our previous immunohistopathologic studies on scalp hair follicles demonstrated deposition of the complement components C3, C5 and C9 in the hair follicle, but no C1q deposits there (4, 5). As in previous studies immunofluorescence of C1q deposition had been seen in areas coinciding with perifollicular infiltrating cells, the present investigation was performed to identify the C1q-positive cells as mast cells and to ascertain the specificity of the C1q deposits in mast cells.

MATERIALS AND METHODS

Scalp tissue specimens obtained from 7 normal subjects and 17 patients with alopecia areata and skin tissue specimens from 2 patients with urticaria pigmentosa were studied. The normal scalp specimens were collected at resection of benign tumors of the head in 2 females and 5 males, ranging in age from 9 to 65 years. In the cases of alopecia areata, 5 females and 12 males (age: 14-40 years), the biopsy specimens were obtained from marginal regions of lesions. There were 2 patients with alopecia areata (single patch), 12 with alopecia areata multiplex, 2 with alopecia totalis and 1 with alopecia universalis. Both patients with urticaria pigmentosa were males,

20 and 29 years of age, from whom the specimens of erupted skin lesions were obtained.

Each specimen was divided into two parts, one being fixed in 10% formalin for preparation of paraffin sections, while the remaining portion was frozen with dry ice-acetone immediately after biopsy and preserved in a deep freezer at -70°C.

Localization of C1q

Direct immunofluorescence examination was made on all specimens with fluorescein isothiocyanate (FITC)-labeled anti-human C1q; both unfixed specimens and those fixed in 99.5% ethanol (5 min) were used. The procedure for the immunofluorescence study has been described elsewhere (4, 5). The tissue sections examined by fluorescent microscopy were then observed with toluidine blue, Giemsa, or hematoxylin and eosin (H & E) stains.

FITC-labelled anti-human C1q

Two commercially available antiserum preparations were used, viz. products of Behringwerke (West Germany) (5) and Medical and Biological Laboratories (MBL, Japan). The latter conjugate had an FITC content of 18.6 µg/ml and a protein content of 5.1 mg/ml, with an F/P molar ratio of 1.5. Both conjugates were diluted to between 1:10 and 1:30 for use in the immunofluorescence study.

Localization of immunoglobulins and other complement components

The immunofluorescence technique was carried out using slides prepared from biopsy or surgical tissue specimens from 5 normal subjects, 14 patients with alopecia areata and 2 with urticaria pigmentosa to detect deposition of immunoglobulins and complement components other than C1q in infiltrating cells. These included the immunoglobulins IgG, IgA, IgM and IgE and complement components C3, C4, C5 and C9. The methods of preparing the conjugates and the immunofluorescence technique were identical with those described previously (4, 5).

Tests for specificity of C1q deposition

1. **Blocking test.** Sections were preincubated with 1:2 to 1:5 dilutions of unlabelled anti-human C1q (Behringwerke, West Germany) at room temperature for 1 hour, and subsequently incubated with FITC-labeled anti-human C1q to ascertain whether any appreciable reduction or extinction of fluorescence had occurred.



Fig. 1. IF staining of mast cell in alopecia areata, showing granular deposition of C1q ($\times 800$).

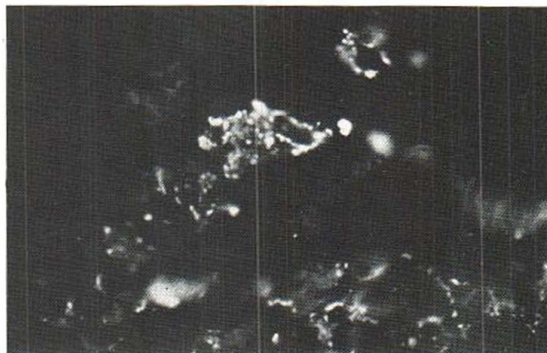


Fig. 2. IF staining of mast cell in urticaria pigmentosa, showing granular deposition of C1q ($\times 1600$).

2. *Phosphate-buffered saline containing bovine serum albumin.* Mast cell surfaces are negatively charged because of their high content of acid mucopolysaccharides. It is therefore conceivable that the FITC-labelled anti-human C1q may bind non-specifically to mast cells. With a view to avoiding this, sections were rinsed with phosphate-buffered saline (PBS) containing 0.5, 1, or 2% bovine serum albumin (BSA; Reheis Chemical Company, USA) for 1 hour and then examined by immunofluorescence technique.

3. *Absorption test.* The FITC-labelled anti-human C1q was combined with appropriate quantities of purified human C1q, and the mixture was incubated at 37°C for 2 hours and then at 4°C overnight, followed by centrifugation to collect the supernatant for use as a conjugate in direct immunofluorescence examination. The MBL preparation of FITC-labelled anti-human C1q was diluted to 1:10 and the Behringwerke preparation to 1:30 for use in the test. The purified human C1q used was prepared by purifying an MBL product according to the procedure of Yonemasu & Stroud (14). It had a C1q concentration of 0.8 mg/ml.

4. *Destruction of C1q.* On the assumption that the FITC-labelled anti-human C1q would no longer be coupled to C1q in mast cells if the latter had been destroyed; sections were either immersed in a 5 M urea solution for 1 hour (11) or heated at 56°C in PBS for 1 hour (16).

These four tests, 1 to 4, were performed on specimens from 3 patients with alopecia areata and 1 with urticaria pigmentosa where deposition of C1q in mast cells had been demonstrated.

5. *Ouchterlony method.* This test was performed to demonstrate immunological interrelations between the purified human C1q or fresh normal human sera and the FITC-labelled or unlabelled antisera to human C1q.

RESULTS

Localization of C1q

C1q deposition was evident in scalp tissue from 5 of the normal subjects (71%), from 14 of the 17 pa-

tients with alopecia areata (82%) and in erupted skin from 1 of the 2 patients with urticaria pigmentosa studied. Areas of fluorescence on these complement deposits coincided in location with infiltrating cells. ● Of the two commercial products of FITC-labelled anti-human C1q used, the MBL preparation was prone to yield a less intense fluorescence than the Behringwerke antiserum, but the difference did not affect the interpretation of test results. Fluorescent microscopic findings for C1q were rated tentatively in categories of (++) denoting an intense fluorescence with increased numbers of C1q-positive cells, and (+), a dim, faint fluorescence with fewer C1q-positive cells. By these criteria, the immunofluorescence was (++) in 1 normal control and (+) in 4 normal controls, (++) in 11 cases of alopecia areata and (+) in 3 cases of the same disease, and (++) in 1 case of urticaria pigmentosa (Table 1). Immunofluorescence was usually prominent, with appreciable numbers of C1q-positive cells, in alopecia areata and urticaria pigmentosa; it showed granular patterns in most positive cases (Figs. 1, 2) though indistinct in an occasional case. The sections which had been observed by fluores-

Table 1. *Immunofluorescence findings (C1q) in mast cells*

	No. of cases	IF findings (C1q)		
		++	+	-
Normal subject (scalp)	7	1	4	2
Alopecia areata	17	11	3	3
Urticaria pigmentosa	2	1	0	1

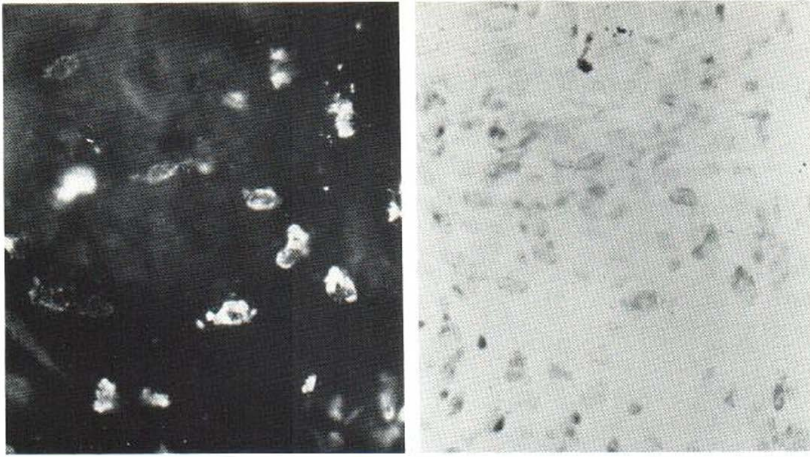


Fig. 3. Mast cells stained with FITC-labelled anti-C1q (*left*) and counterstained with toluidine blue (*right*) in alopecia areata ($\times 800$).

cent microscopy revealed metachromasia (Fig. 3) and degranulation of the C1q-positive cells when examined after toluidine blue staining. These cells stained red on slides with Giemsa stain. On the basis of these findings, the C1q-positive cells were identified as being mast cells.

Localization of immunoglobulins and other complement components

Fluorescence microscopy did not elicit evidence of deposition in mast cells of any of the immunoglobulins (IgG, IgA, IgM, IgE) or of the complement components (C3, C4, C5, C9) looked for.

Tests for specificity of C1q deposits

The blocking test showed extinction of the immunofluorescence. The immunofluorescence neither diminished nor disappeared after rinsing of the sections with PBS containing BSA at any concentration. No fluorescence could be demonstrated in the absorption test, nor after treatment of the sections with 5 M urea or by heating in PBS at 56°C. The Ouchterlony method demonstrated single precipitin lines of identity between the FITC-labelled or unlabelled anti-human C1q and the purified human C1q or fresh normal human sera (Fig. 3).

DISCUSSION

There are many reports on mast cells in the literature. It is now generally accepted that mast cells play an important role by releasing various chemical mediators at the site of inflammation. The histamine liberated from mast cells increases vascular

permeability via the H_1 -receptor of the endothelium of blood vessels and suppresses proliferation of fibroblasts and blood capillaries via the H_2 -receptor (2, 9). The eosinophil chemotactic factor of anaphylaxis (ECF-A) is also released from mast cell granules (8), and the eosinophils mobilized to the site bring the inflammation to an end (12). Furthermore, it has been described immunologically that mast cells possess the Fc receptor for IgE (6), that mast cells of the rat are stimulated by C3a and C5a to release histamine (7) and that complement activation is inhibited by heparin liberated from mast cell granules (13).

Recently, the complement component C1q has been demonstrated by amino acid analysis (15) as




Fig. 4. Ouchterlony method. C1q (C) (0.8 mg/ml), heated C1q (H) (56°C, 30 min) and FITC-labelled anti-C1q (F) (Behringwerke; 2.4 mg/ml) allowed to diffuse in agarose gels. A single line of precipitation is observed at the site of C-F interaction.

a collagen-like protein and to be synthesized and secreted by fibroblasts of human skin (1).

An immunohistopathologic study by Nieboer & van Leeuwen (10) demonstrated deposition of IgE in mast cells of patients with bullous pemphigoid. Hodge et al. (3) observed no evidence of deposits of IgG, IgA, IgM, IgE and C3 in the lesion of a patient with mastocytosis, though in this study no attempt was made to detect C1q.

As yet, there appears to have been no report concerned with C1q in mast cells. The present study may well be the first report of C1q deposition demonstrated in mast cells. In this study, fairly detailed assessments were made to explore the specificity of C1q deposition in mast cells, namely, detection of immunoglobulin and other complement component deposits in mast cells, comparison of two commercial preparations of FITC-labelled anti-human C1q, blocking test, prerinse of tissue sections with PBS containing BSA to avoid non-specific immunofluorescence, absorption test, destruction of C1q by chemical and physical agents, and the Ouchterlony method. All these procedures yielded the results which constitute evidence of C1q deposition in mast cells.

Nothing is yet known about the role played by C1q in mast cells. The granular immunofluorescence patterns of C1q deposits frequently observed in the present series seem to suggest that C1q may reside in characteristic mast cell granules. If this is true, then it is likely that C1q takes part in the mechanism whereby chemical mediators are liberated from the granules *per se* rather than in the mechanism of mast cell degranulation.

Further studies aimed at clarification of the role of C1q in mast cells are under way.

ACKNOWLEDGEMENTS

The authors are indebted to Dr Hiroaki Ueki, professor of dermatology, Kawasaki Medical College, Kurashiki, Okayama Prefecture, and Dr Kunio Yonemasu, assistant professor of bacteriology, Nara Prefectural College of Medicine, Kashiwara, Nara Prefecture, Japan, for helpful advice in this investigation.

REFERENCES

1. Al-Adnani, M. S. & McGee, J. O'D.: C1q production and secretion by fibroblast. *Nature* 263: 145, 1976.
2. Baudry, M., Martres, M. P. & Schwartz, J. C.: H₁ and H₂ receptors in the histamine-induced accumula-

- tion of cyclic AMP in guinea pig brain slices. *Nature* 253: 362, 1975.
3. Hodge, I., Block, M. M. & Gange, R. W.: Eosinophil fluorescence in cutaneous infiltrates. A possible source of confusion. *Clin Exp Dermatol* 3: 123, 1980.
4. Igarashi, R., Takeuchi, S. & Sato, Y.: Immunofluorescent studies of complement C3 in the hair follicles of normal scalp and of scalp affected by alopecia areata. *Acta Dermatovener (Stockholm)* 60: 33, 1980.
5. Igarashi, R., Morohashi, M., Takeuchi, S. & Sato, Y.: Immunofluorescence studies on complement components in the hair follicles of normal scalp and of scalp affected by alopecia areata. *Acta Dermatovener (Stockholm)* 61: 131, 1981.
6. Ishizaka, K., Tomioka, H. & Ishizaka, T.: Mechanisms of passive sensitization. I. Presence of IgE and IgG molecules on human leukocytes. *J Immunol* 105: 1459, 1970.
7. Johnson, A. R., Hugli, T. E. & Müller-Eberhard, H. J.: Release of histamine from rat mast cells by the complement peptides C3a and C5a. *Immunology* 28: 1067, 1975.
8. Kay, A. B. & Austen, K. F.: The IgE-mediated release of an eosinophil leukocyte chemotactic factor from human lung. *J Immunol* 107: 899, 1971.
9. Nahorski, S. R., Rogers, K. J. & Smith, B. M.: Histamine H₂ receptors and cyclic AMP in brain. *Life Sci* 15: 1887, 1975.
10. Nieboer, C. & van Leeuwen, H. J. E.: IgE in the serum and on mast cells in bullous pemphigoid. *Arch Dermatol* 116: 555, 1980.
11. Shelton, E., Yonemasu, K. & Stroud, R. M.: Ultrastructure of the human complement component, C1q. *Proc Nat Acad Sci* 69: 65, 1972.
12. Wasserman, S. I., Goetzl, E. J. & Austen, K. F.: Inactivation of slow reacting substance of anaphylaxis by human eosinophil arylsulfatase. *J Immunol* 114: 645, 1975.
13. Weiler, J. M., Yurt, R. W., Fearon, D. T. & Austen, K. F.: Modulation of the formation of the amplification convertase of complement, C3b, Bb, by native and commercial heparin. *J Exp Med* 147: 409, 1978.
14. Yonemasu, K. & Stroud, R. M.: C1q, Rapid purification method for preparation of monospecific antisera and for biochemical studies. *J Immunol* 106: 304, 1971.
15. Yonemasu, K., Stroud, R. M., Niedermeier, W. & Butler, W. T.: Chemical studies on C1q. A modulator of immunoglobulin biology. *Biochem Biophys Res Commun* 43: 1388, 1971.
16. Yonemasu, K.: Anti-human C1q. Rapid and simple method for preparing monospecific antisera. *J Immunol Methods* 9: 185, 1975.

Received June 12, 1981

R. Igarashi, M.D.

Department of Dermatology
Toyama Medical and Pharmaceutical University
2630 Sugitani, Toyama 930-01
Japan