

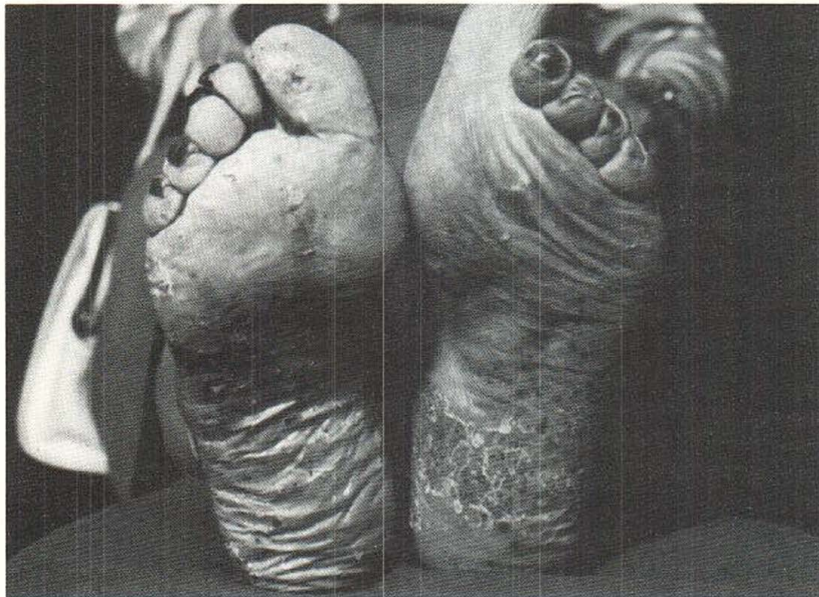Fig. 3. Soles after 5 weeks of treatment with Tigason® (Ro 10-9359).

neurocutaneous elements. The intra-epidermal abscesses might be the result of trans-epidermal elimination of immune deposits from the dermis (8). A neurocutaneous pathogenesis would support the "lower epidermis" theory concerning the morphogenesis of PPP (i.e. the first phase in characterized by spongiosis and vesicle formation in the lower layers of epidermis) (7).

#### REFERENCES

1. Baker, H. & Wilkinson, D. S.: Persistent pustulosis of hands and feet. In *Textbook of Dermatology* (ed. A. Rook, D. S. Wilkinson & F. J. G. Ebling), p. 1363. Blackwell Scientific Publications, Oxford, London, Edinburgh, Melbourne, 1979.
2. Mattsby-Baltzer, I., Mobacken, H., Olling, S. & Rosén, K.: Neutrophil granulocyte function in pustulosis palmoplantaris. *Acta Dermatovener (Stockholm)* 58: 494, 1978.
3. Molin, L. & Rajka, G.: Phagocytic activity of neutrophil leucocytes in pustulosis palmo-plantaris, chronic discoid lupus erythematosus and erysipelas. *Acta Dermatovener (Stockholm)* 51: 138, 1971.
4. Perry, H. O.: Pustular eruptions of palms and feet. In *Dermatology in General Medicine* (ed T. B. Fitzpatrick, A. Z. Zeissen, K. Wolff, J. M. Freedberg & K. F. Austen), 2nd ed., pp. 350-352. McGraw-Hill, New York, 1979.
5. Rosén, K., Mobacken, H. & Nilsson, L.-Å.: Increased prevalence of antithyroid antibodies and thyroid diseases in pustulosis palmoplantaris. *Acta Dermatovener (Stockholm)* 61: 237, 1981.
6. Thomsen, K. & Østerby, P.: Pustulosis palmaris et plantaris. *Br J Dermatol* 89: 293, 1973.
7. Uehara, M. & Shigeo, O.: The morphogenesis of pustulosis palmaris et plantaris. *Arch Dermatol* 109: 518, 1974.
8. Ueki, H., Kubo, M., Masuda, T. & Nohara, N.: Trans-epidermal elimination of immune deposits in the skin. An immunochemical study on immune deposits using horseradish peroxidase as antigen. *J Dermatol* 3: 209, 1976.
9. Ward, J. M., Corbell, M. F. & Hanna, M. J.: A double-blind trial of clomocycline in the treatment of persistent palmoplantar pustulosis. *Br J Dermatol* 95: 317, 1976.

### Tyrosinase-negative Albinism with Congenital Malformations and Squamous Cell Carcinoma of the Genitalia

A. L. Claudy<sup>1</sup> and J. P. Ortonne<sup>2</sup>

<sup>1</sup>Department of Dermatology, Hospital Bellevue, F-42000 St Etienne, and

<sup>2</sup>Department of Dermatology, Hospital E. Herriot, F-69003 Lyon, France

Received September 7, 1981

**Abstract.** A 41-year-old tyrosinase-negative male albino presented with congenital bilateral inguinal hernias, club feet and squamous cell carcinoma of the glans penis. Such associations do not appear to have been reported previously.

**Key words:** Tyrosinase-negative albinism; Genetic disorders; Squamous cell carcinoma; Genitalia

Albinism is a genetically determined disorder of pigmentation that may involve the eye (X-linked ocular albinism) or the eye, the skin and hair (autosomal recessive oculo-cutaneous albinism) (2). Skin cancers in albinos are rare in temperate climates and they occur mostly on sun-exposed areas. If one excepts the optic pathway abnormality, oculo-cutaneous albinism is not usually associated with congenital malformations. The presence of both, inborn abnormalities and cutaneous carcinoma of covered skin, in the same patient has not been reported earlier, to the best of our knowledge. We report such a case.

### CASE REPORT

The patient, a 41-year-old male albino, is the only child in a non-consanguineous marriage. Familial history failed to reveal any disorder of pigmentation. No bleeding tendency was noted.

Physical examination showed fair skin, blond hair, reduced tolerance to sunlight, photophobia, reduced visual acuity, nystagmus, brown irises and ocular deviation. Congenital bilateral inguinal hernias and club feet were also prominent clinical features. Early in 1979, the patient developed a squamous cell carcinoma of the glans penis, confirmed histologically, and died from metastasis in November 1980.

The examination of anagen hairbulbs plucked from the scalp showed no pigment formation after prolonged incubation in L-tyrosine and L-dopa (6).

### COMMENT

Oculo-cutaneous albinisms represent a heterogeneous group of four distinct autosomal recessive disorders: tyrosinase-positive, tyrosinase-negative, yellow mutant and albinism with hemorrhagic diathesis. Two additional uncommon entities should be mentioned: X-linked ocular albinism (9) and dominant oculo-cutaneous albinism (3).

Genetically determined disorders of pigmentation may be associated with various neurological defects such as neurosensory hearing loss and Hirschsprung's disease in Waardenburg's syndrome (1), cerebellar ataxia, mental retardation, Hirschsprung's disease in piebaldness (8) and nystagmus in albinism. Defective embryonic migration of the neural crest cells may partly explain both pigimentary and neurologic disorders.

Few extraneural congenital disturbances have

been described: one case of X-linked ocular albinism and familial nephritis (9), and one case of a unique type of familial hypopigmentation associated with a Prader-Willi syndrome and a chromosomal anomaly (5). Apart from disturbances in melanogenesis which characterize classical albinisms, pigimentary dilution syndromes due to an anomaly in melanosome formation, such as Chediak-Higashi syndrome and the Nettleship-Falls type of X-linked ocular albinism (9), have not been described in association with a high frequency of congenital neural or extraneural malformations. No inborn anomalies such as those noted herein have been reported so far, to our knowledge.

Albino patients who live in the equatorial regions of Africa are known to die of skin cancer in early adult life or in middle age at best (10). However, the occurrence of cutaneous carcinomas in albino patients living in extratropical regions is very rare (4). Furthermore, malignant changes commonly complicate solar keratosis (7). The unusual feature of our patient was the presence of squamous cell carcinoma on an area never exposed to sunlight. Although, in our case, the congenital malformations and the cutaneous carcinoma may be unrelated to the albinism, further studies will be needed to ascertain the relationship between these uncommon associated clinical features.

### REFERENCES

1. Branski, D., Dennis, N. R. & Neale, J. M.: Hirschsprung's disease and Waardenburg's syndrome. *Pediatrics* 63: 803, 1979.
2. Fitzpatrick, T. B. & Quevodo, W. C. Jr: Albinism. *In* Metabolic Basis of Inherited Disease (ed. J. B. Stanbury, J. B. Wyngaarden, and D. S. Fredrickson), p. 326. McGraw-Hill, New York, 1972.
3. Fitzpatrick, T. B., Jimbow, K. & Donaldson, D. D.: Dominant oculo-cutaneous albinism. *Br J Dermatol* 91, Suppl. 10: 23, 1974.
4. Freire-Maia, N. & Cavalli, I. J.: Albinism, skin carcinoma and chromosome aberrations. *Clin Genet* 17: 46, 1980.
5. Frenk, E. & Calame, A.: Hypopigmentation oculo-cutanée familiale à transmission dominante due à un trouble de la formation des mélanosomes. Association d'un syndrome de Prader-Willi et d'une anomalie chromosomique chez un des sujets atteints. *Schweiz Med Wochenschr* 107: 1964, 1977.
6. Kugelmann, T. P. & Van Scott, E. J.: Tyrosinase activity in melanocytes of human albinos. *J Invest Dermatol* 37: 73, 1961.
7. Leibowitz, M. R., Dogliotti, M. & Hart, G.: Schizophrenia and albinism. *Dermatologica* 156: 367, 1978.

8. Mahakrishnan, A. & Srinivasan, M. S.: Piebaldness with Hirschsprung's disease. *Arch Dermatol* 116: 1102, 1980.
9. O'Donnel, F. E., Hambrick, G. W., Green, R., Iliff, W. J. & Stone, D. L.: X-linked ocular albinism. *Arch Ophthalmol* 94: 1883, 1976.
10. Okoro, A. N.: Albinism in Nigeria: a clinical and sociological study. *Br J Dermatol* 91, Suppl. 10: 24, 1974.

## Incontinentia Pigmenti with Dental Anomalies: A Three-generation Study

Mats Bjellerup

Department of Dermatology, University of Lund,  
General Hospital, S-21401 Malmö, Sweden

Received July 17, 1981

**Abstract.** Three individuals with incontinentia pigmenti from one family spanning three generations are described. All three had associated dental anomalies. The pattern of inheritance is consistent with the theory of an X-linked gene, dominant in females and lethal in males.

**Key words:** Incontinentia pigmenti; Dental anomalies

Incontinentia pigmenti (IP) is an uncommon genodermatosis that occurs almost exclusively in female infants.

IP presents distinct clinical manifestations. The disease usually appears at birth, presenting with inflammatory lesions consisting of erythematous macules, papules and bullas arranged in a linear pattern on the extremities and torso. In the typical case this stage is followed by a verrucous stage after

2-6 weeks, lasting for a few months. During the verrucous stage or a few months thereafter the pigmented stage appears, not necessarily on the same places as the inflammatory lesions, with bizarre pigmentations mostly on the torso. These pigmentations gradually fade and are usually absent by adulthood.

In contrast to the benign skin manifestations there are also developmental defects in 80% of patients with IP, the most serious being ocular anomalies leading to blindness (3). Other reported defects are scalp abnormalities, nail dystrophy, dental anomalies and disorders of the central nervous system.

This report describes a family in which members of three successive generations have IP combined with dental anomalies (Fig. 1).

### CASE REPORT

The propositus (IV. 1) was born weighing 3.3 kg after an uncomplicated 43-week pregnancy. Two days after delivery a rash was noticed consisting of pronounced erythema, papules and vesicles, having a peculiar band-shaped distribution over the buttocks, dorsally on the thighs, laterally on the abdomen, but sparse on arms and cheeks. Three days later the rash had almost disappeared but after a few days a similar rash appeared, lasting for a few days. A blood leukocytosis of 22 600 was found, whereof 4060 were eosinophils. A punch biopsy was consistent with the second phase of IP, with dyskeratotic cells in the epidermis.

An examination at the age of 3 months revealed pigmentations medially on the thighs and on the left labium majus. At the age of 18 months there were small pigmented patches laterally on the torso and a larger irregular pigmented patch on the left buttock. Neurological and ophthalmological examinations were normal. Chromosomal analysis showed a normal 46, XX pattern. The child, now 27 months old, has developed normally except that she has no primary laterals in the upper jaw (Fig. 2).

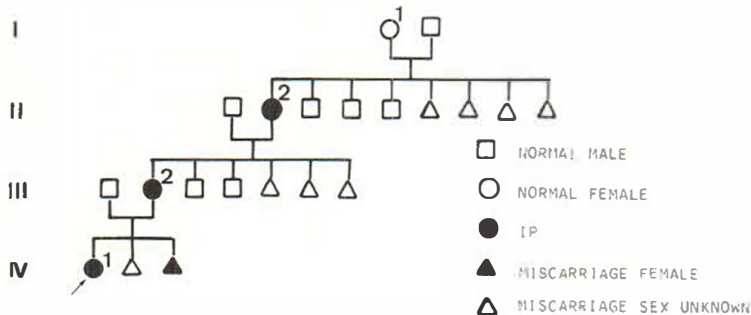


Fig. 1. Pedigree of family. Propositus is indicated by arrow.