

- leukocytoclastic angiitis. *J Invest Dermatol* 64: 105, 1975.
2. Dubois, E. L.: *Lupus Erythematosus*. 285 pp. Univ. of Southern California Press, Los Angeles, 2nd ed. 1974.
 3. Estes, D. & Christian, C. L.: The natural history of systemic lupus erythematosus by prospective analysis. *Medicine* 50: 85, 1971.
 4. Harvey, A. M., Shulman, L. E., Tumulty, A., Conley C. L. & Schoenrich, E. H.: Systemic lupus erythematosus: Review of the literature and clinical analysis of 138 cases. *Medicine* 33: 291, 1954.
 5. Horváth, A., Krámer, M., Vajda, T., Ablonczy, É., Kohánka, V., Bognár, Á., Daróczy, J. & Király, K.: Urticaria-like skin eruptions in systematic lupus erythematosus. *In Proc. Current Problems of Immunology and Their Dermatological Aspects*. Symp. (ed. I. Rácz), 261 pp. Budapest, 1977.
 6. Horváth, A., Ablonczy, É., Molnár, L., Baló-Banga, J. M., Leibinger, J. & Rácz, I.: Immunokomplex fagocitózis vizsgálata lupus erythematosesben. *Rheum-Baln-Allerg* XX: 9, 1979.
 7. Ishizaka, T., Sian, C. M. & Ishizaka, K.: Complement fixation by aggregated IgE through alternative pathway. *J Immunol* 108: 849, 1972.
 8. Matthews, C. N. A., Saihan, E. M. & Warin, R. P.: Urticaria-like lesions associated with systemic lupus erythematosus: response to dapsone. *Br J Dermatol* 99: 455, 1978.
 9. McDuffie, F. C., Sams, W. M., Jr, Maldonado, J. E., Andreini, P. H. & Samayda, E. A.: Hypocomplementemia with cutaneous vasculitis and arthritis. Possible immune complex syndrome. *Mayo Clin Proc* 48: 340, 1973.
 10. O'Loughlin, S., Schroeter, A. L. & Jordan, R. E.: Chronic urticaria-like lesions in systematic lupus erythematosus. *Arch Dermatol* 114: 879, 1978.
 11. Provost, T. T., Thomasy & T. B., Jr: Immunopathology of bullous pemphigoid. Basement membrane deposition of IgE alternative pathway components and fibrin. *Clin Exp Immunol* 18: 193, 1974.
 12. Tuffanelli, D. L.: Cutaneous immunopathology: recent observations. *J Invest Dermatol* 65: 143, 1975.

Cutaneous Periarteritis nodosa Occurring during Pregnancy

Anne Janin-Mercier,¹ André J. Beyvin,²
Martin Pablo² and Bernard Jacquetin³

¹Department of Pathology, ²Department of Dermatology and ³Department of Gynecology, Faculté de Médecine, Place H. Dunant, F-63 000 Clermont-Ferrand, France

Received November 10, 1981

Abstract. In 9 reported cases of periarteritis nodosa accompanying pregnancy, 7 patients developed systemic periarteritis nodosa during pregnancy and died in post-

partum phase, but full-term infants survived. In 2 cases a cutaneous form of periarteritis nodosa was diagnosed 12 and 4 years before pregnancy and women survived.

We now report the first case of cutaneous periarteritis nodosa beginning during pregnancy. After a thorough 4-year follow-up and a review of the literature we suggest that the successful maternal outcomes may be related to the milder prognosis of cutaneous periarteritis nodosa compared with the systemic form, and that there is apparently no relation between the maternal and the infant involvement in periarteritis nodosa.

Key words: Periarteritis nodosa; Cutaneous form; Pregnancy; Survival

Eight cases of periarteritis nodosa (PAN) and pregnancy were reviewed in 1978 (1). In one of them, cutaneous PAN was diagnosed several years before pregnancy (4). Another similar case was described by Szinnyai (9). We report here the first case of cutaneous PAN occurring during pregnancy.

CASE REPORT

A 25-year-old primigravida developed during the sixth month of pregnancy a painful, violaceous livedo reticularis of both legs (Fig. 1) with myalgia. On admission a month later, the patient was pale, with severe asthenia, anorexia and weight loss. Temperature was 37.6°C, BP 120/70. Laboratory studies showed a Hgb of 10 mg, a WBC count of 7 800 and an ESR of 83 mm, total serum protein was 7.4 ml/100 ml with a rise in the alpha-2 fraction on electrophoresis. Coombs test and Hb electrophoresis gave normal results, as did the hepatitis-associated antigen test, the liver function, and the kidney function studies. Tests for cryoglobulinemia, MNI, rickettsia proved negative. EKG and chest X-ray were normal.

Biopsy of the skin lesions revealed necrotizing vasculitis of the arterioles (Fig. 2) with focal panniculitis in the hypodermis. Fibrinoid necrosis was found on the inner arteriolar wall, the media was thickened, the internal elastic lamina disrupted, fibroblasts and polymorphonuclear leukocytes were prominent.

Three weeks after admission fever (39°C) appeared, cutaneous lesions progressed to necrosis and ulceration, pain and myalgia increased and peripheral neuritis of the legs and feet occurred, causing unilateral foot drop. BP remained at 120/70, however. A cesarean section was performed in the 37th week of pregnancy, delivering a 3000 g healthy boy. Careful examination of the placenta did not reveal infarcts or necrotizing arteritis. Postoperatively the patient was given 120 mg Prednisolone daily.

Clinical improvement with normal temperature began only a month later and prednisone was then progressively decreased. After a 4-year follow-up, the boy shows no signs of vasculitis; the patient has deep atrophic scars on the legs and permanent foot drop.

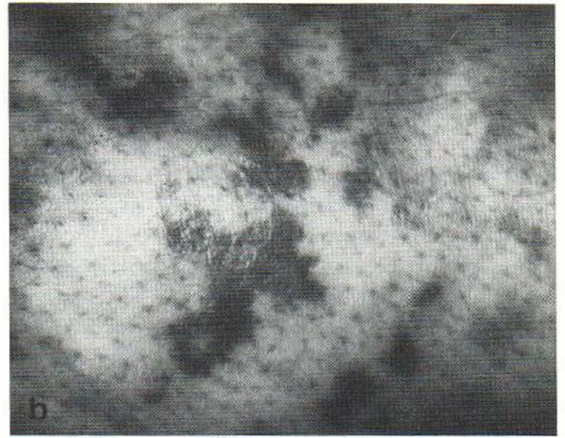
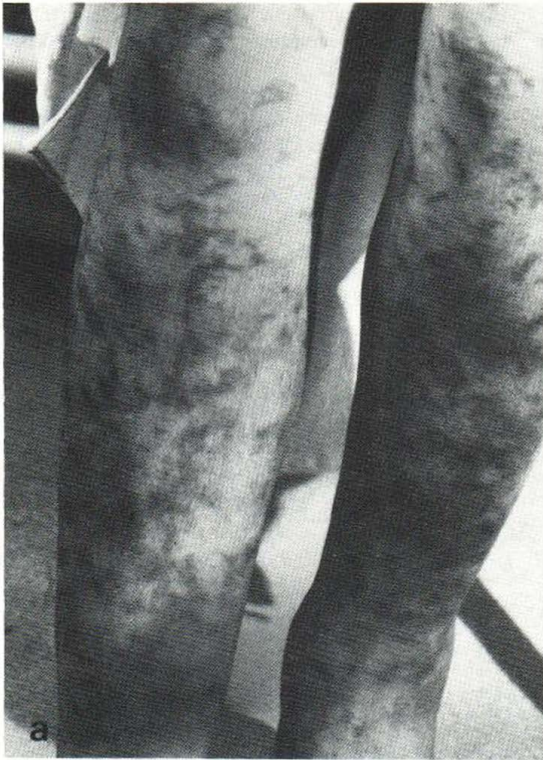

Fig. 1. (a). Violaceous livedo reticularis of both legs. (b). High magnification of the livedo.

DISCUSSION

Among 9 patients with PAN in pregnancy, reported in the literature (8-4), 7 had no clinical sign of PAN before pregnancy. All died with hypertension and impaired renal function simulating toxemia and PAN—except in one case (4)—was discovered on post-mortem examination. Maternal deaths occurred in the post-partum phase in each instance. In one case (3) a therapeutic abortion did not improve the prognosis.

In 2 other cases, PAN was diagnosed on skin biopsies 12 (9) and 4 (4) years before pregnancy. The first patient had only cutaneous lesions for 8 years, but recurrent abdominal involvement occurred later, before pregnancy. Admitted in the ninth month of pregnancy with hypertension, she was delivered of an infant whose death was attributed to necrotizing vasculitis of the placenta. During prednisolone therapy, PAN did not worsen in the post-partum period. In the second case, PAN was limited to the skin, no placental lesion was reported, and the infant was healthy. The maternal lesions treated with prednisone, hydroxyprogester-

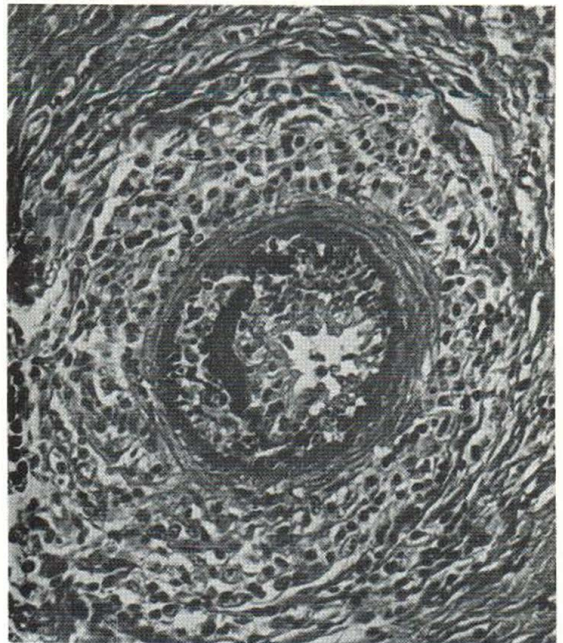


Fig. 2. Necrotizing vasculitis in a hypodermal arteriole.

terone and estradiol did not worsen in the postpartum phase.

Our patient developed PAN during pregnancy, but in a cutaneous form. This is a distinct clinical entity (5) usually limited to the medium-size arteries in the deep dermis and panniculus. It is accompanied (2) by pain, myalgia and peripheral neuritis of the lower extremities. Compared with the systemic form it has a benign course and this may explain the maternal survival in the 3 cases of cutaneous PAN.

In our case, the infant survived, as in 6 of the 7 cases where pregnancy could proceed to full term. The only infant death (9) was related to placental arteritis and not to infant vasculitis. Thus the pathological process in pregnant women with PAN is apparently not transmitted to the fetus *in utero*.

Conversely, of the 28 reported cases of PAN in infancy (6) only 3 began shortly after the birth (10 days, 25 days (10), 6 weeks (7) with symptoms since the birth), which may suggest an *in utero* involvement. In these cases no maternal illness or complication of pregnancy was reported. Furthermore, of the 28 cases, only one maternal connective tissue disease (rheumatoid arthritis) was reported (1).

The fetus resistance to PAN in pregnancy may be explained by the fact that the fetus cannot synthesize antibodies until after 4 weeks of *ex utero* life (8). Further follow-up of the infants was not reported. In our case no sign of vasculitis could be detected in the child throughout a 4-year period of regular follow-up.

ACKNOWLEDGEMENTS

We thank Mr Ragonnaud for the photographs and Mrs Brunel for preparation of the typescript.

REFERENCES

1. Benyo, R. B. & Perrin, E. V.: Periarthritis nodosa in infancy. *Am J Dis Child* 116: 539, 1968.
2. Borrie, P.: Cutaneous polyarteritis nodosa. *Br J Dermatol* 87: 87, 1972.
3. Chesley, L. C.: Maternal deaths. *Bull M Hague Matern Hosp* 2: 91, 1949.
4. De Beukelaer, M. M., Travis, L. B. & Roberts, D. K.: Polyarteritis nodosa and pregnancy: report of a successful outcome. *South Med J* 66: 613, 1973.
5. Diaz-Perez, J. L. & Winkelmann, R. K.: Cutaneous pariarthritis nodosa. *Arch Dermatol* 110: 407, 1974.
6. Ettliger, R. E., Nelson, A. M., Burke, E. C. & Lie, J. T.: Polyarteritis nodosa in childhood. A clinical pathologic study. *Arthritis Rheum* 22: 820, 1979.

7. Liban, E., Shamir, Z. & Schorrs, S.: Periarthritis nodosa in a nine-month-old infant. *Am J Dis Child* 88: 210, 1954.
8. Reed, N. R. & Smith, M. T.: Periarthritis nodosa in pregnancy: report of a case and review of the literature. *Obstet Gynecol* 55: 381, 1980.
9. Szinnyai, M., Toth, F., Hegyi, J. & Fülöp, E.: Polyarteritis nodosa and Schwangerschaft. *Zentralbl Gynaekol* 7: 21, 1970.
10. Wilmer, H. A.: Two cases of periarthritis nodosa occurring in the first month of life. *Bull Johns Hopkins Hosp* 77: 275, 1945.

Palmoplantar Pustulosis: A Neurocutaneous Disease?

Knud Hamann

*Department of Dermatology, Gentofte Hospital,
DK-2900 Hellerup, Denmark*

Received September 22, 1981

Abstract. A case of palmoplantar pustulosis in a 74-year-old woman is presented. The clinical appearance suggests a neurocutaneous pathogenesis.

Key words: Palmoplantar pustulosis; Neurocutaneous disease

Palmoplantar pustulosis (PPP) is a chronic and persistent eruption of yellowish sterile pustules occurring predominantly and most often symmetrically on the thenar or hypothenar eminence and the soles or sides of the heel. Occasionally the pustules are more diffusely scattered over the palms or soles (1).

The aetiology is still undetermined (1, 4). The present case suggests that PPP is a neurocutaneous disease.

CASE REPORT

A 74-year-old woman was referred with PPP. A brother had psoriasis. The right hand had been amputated at the age of 4 because of complications after an antebachium fracture.

Since 1978 the patient had been treated for PPP with local steroides, salicylic ointment, Bucky and K_2MnO_4 baths without effect. Examination revealed a crusting, hyperkeratotic element localized to the hypothenar of the left hand (Fig. 1). On the right antebachium, crusting and hyperkeratotic elements were found at the distal end (Fig. 2). The soles showed numerous yellow and brown pustules and crusting. Fig. 3 shows the therapeutic situation after 5 weeks of treatment with 25 mg aromatic retinoid (Ro 10-9359).