

in 4 cases. Thus complete and partial remission was achieved in 6 out of 9 cases. Owing to toxic effects or therapeutic failure (NC, PD) the treatment was withdrawn after two to seven treatment cycles. It was thus not possible to maintain the initial remission by the present combinations of drugs.

*Side effects* requiring dosage reduction or withdrawal of treatment were reported as: nausea in one case, alopecia in 4 cases, dental loss in one, bone marrow depression in 2, neurological complaints (mainly paresthesia of the lower legs) in 3.

## DISCUSSION

Aggressive treatment with three to five drug combination chemotherapy as presented in this report has been disappointing. Initially only one patient obtained complete remission and 5 partial remission. This response rate is of the same magnitude as we have previously found with other systemic treatments (1, 2, 3). However, the induced remissions were short-lived. Owing to the high degree of toxicity of the chosen combination of drugs their dosage levels could not be increased and were completely ruled out as maintenance treatment.

At this point it is tempting to speculate if a less aggressive attitude would be more beneficial in these patients, as such a treatment could be continued for prolonged periods.

We are still searching for the drug, or combination of drugs, of choice for the treatment of advanced cases of mycosis fungoides.

## ACKNOWLEDGEMENT

This work was supported by the Danish Cancer Society, the Norwegian Cancer Society, the Swedish Cancer Society and the Edvard Welander Foundation.

## REFERENCES

1. Groth, O., Molin, L., Thomsen, K., Grunnet, E., Hellbe, L., Holst, R., Michaelsson, G., Nilsson, E., Roupe, G., Schmidt, H. & Skogh, M.: Tumour stage of mycosis fungoides treated with bleomycin and methotrexate. *Acta Dermatovener (Stockholm)* 59: 59, 1979.
2. Hansen, M. M., Bloomfield, C. D., Jørgensen, J., Ersbøll, J., Pedersen-Bjergaard, J., Blom, J. & Nissen, N. I.: VP-16-213 in combination with cyclophosphamide, adriamycin, vincristine, and prednisone in treatment of non-Hodgkin's lymphomas. *Cancer Treatment Reports*, accepted for publication.

3. Molin, L., Thomsen, K., Volden, G., Bergqvist-Karlsson, A., Hallberg, O. & Hellbe, L.: Epipodophylotoxin (VP-16-213) in mycosis fungoides. *Acta Dermatovener (Stockholm)* 59: 84, 1979.
4. Molin, L., Thomsen, K., Volden, G., Bergqvist-Karlsson, A. & Hellbe, L.: Prednimustine in mycosis fungoides. *Acta Dermatovener (Stockholm)* 59: 87, 1979.

## A Lidocaine-Prilocaine Cream for Superficial Skin Surgery and Painful Lesions

Lennart Juhlin, Hans Evers and Fredrik Broberg

*Department of Dermatology, University Hospital, Uppsala, Sweden and Medical and Research Departments, Astra Läkemedel, Södertälje, Sweden*

Received June 9, 1980

**Abstract.** A eutectic mixture of lidocaine and prilocaine in a water emulsion cream base produces effective superficial dermal analgesia when applied under occlusive dressing for 60 minutes. On the genitals, lips and oral mucosa, the application time can be reduced. The cream was found to be an effective alternative to conventional infiltration anesthesia for dermabrasion and superficial surgical procedures. It is especially useful in children for the removal of molluscum contagiosum and prior to venepuncture. The preparation is also an effective pain reliever when used on certain ulcerations.

**Key words:** Topical anesthesia; Anesthetic cream; Lidocaine; Prilocaine; Skin surgery

When injecting a local anesthetic, pain is produced by the needle's penetration and by the deposition of the anesthetic solution, which is a problem especially in children and in the genital area in adults. Infiltration of large areas can also be a problem.

In a previous study we found that, using the pinprick technique, a 10% eutectic mixture of lidocaine and prilocaine base produced more effective skin anesthesia than each base alone in the same total concentration (1). The reason for the greater effectiveness of the eutectic mixture composition, compared with the individual active components, is the higher concentration of the local anesthetic bases in the emulsion droplets (80% versus 20%).

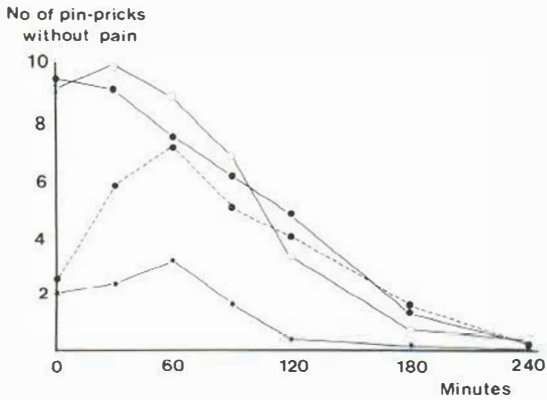


Fig. 1. Effect of drug concentration and application time on skin anesthesia in 24 healthy subjects. Ordinate: Mean number of 10 pin-pricks without pain when tested on the inside of the forearm. Abscissa: Anesthetic applied under occlusion for 60 min: 1% (★—★), 2.5% (○—○), 5% (●—●), and 5% for 30 min (●---●).

## METHODS

In a double-blind dose-response study, various concentrations of the lidocaine-prilocaine mixture were tested with a pin-prick method on the inside of the forearm of 24 healthy volunteers. Small pads, 1×3 cm, each soaked with 0.3 ml of the test emulsions were applied under occlusive tape bandages for 30 and 60 minutes. The highest concentration of the mixed bases in this study was 5%. The same initial analgesic effect, recorded immediately after the removal of the bandages, was found with 2.5% and 5% test emulsions after 60 minutes' application. An application time of 30 minutes, and the use of concentrations lower than 2.5% produced less pronounced dermal analgesia. (See Fig. 1.)

In the clinical part of our present study a 5% eutectic water-based emulsion cream, containing equal amounts of the lidocaine and prilocaine bases, an emulsifying agent and a viscosity increasing substance, was used. A separate experimental study had revealed that the dermal

analgesia efficacy, tested with pin-prick, was not influenced by the addition of a viscosity increasing agent, when using an application time of 60 min. To obtain an even distribution of the test cream on the skin the cream was covered with a thin, soft paper before the occlusive bandage was applied. In the adult patients the bandage was left in contact with the skin for 60 min, while in children 30 min was often found to be enough. On the genitals and on the lips shorter application times may provide adequate analgesia. When the cream is applied to mucous membranes, analgesia becomes evident within a few minutes. A slight blanching of the skin in the areas that have been in contact with the cream was noticed in most cases. This effect is a useful marker for complete anesthesia, which persists for 1-2 hours.

## RESULTS

The results are summarized in Table 1.

*Removal of molluscum contagiosum.* The cream was applied to the molluscs for 30-45 min. Scrapings were done with a scalpel on 8 children aged 2-9 years, without causing any pain. The lesions were situated on various areas such as the neck, abdomen, genitals and legs.

*Before venepuncture in children.* The area on the arm was treated with the cream for one hour. No pain was felt when the needle was inserted. In adults no pain was felt in the skin but when the needle perforated a thick vein.

*Epidermal surgery.* Lentigo and superficial skin lesions can be removed without any pain for sample investigation with recourse to the razor-blade technique (5). This has been done on the face and on various other areas in 24 patients.

*Removal of tattoos.* The tattoo was covered with the cream for one hour. Dermabrasion was done over the tattooed area with a dentist's drill until slight bleeding occurred. When pure salt was applied on the dermabraded skin a burning sensation was felt for a short time. This could be prevented by reapplication of the cream for a few minutes before adding the salt. The salt was left on under a bandage for 24 hours.

*Removal of hair.* In hirsutism, removal of hair with wax is painful. Nothing or little is felt after pre-treatment of the face, arms or legs with the anesthetic cream. It can also be used when removing hair from the scalp.

*Skin biopsy.* When biopsy samples were taken with a rotating punch, pain could be felt when cutting deep. Superficial cutting with a knife could also be done, but pain was felt when cutting into subcutaneous tissue.

Table 1

Indications	No. of patients	Effect
Removal of contagious molluscs	8	No pain
Before venepuncture in children	10	No pain
Epidermal surgery	24	No pain
Tattoo removal	5	No pain
Venereal and oral lesions	20	No pain
Painful ulcers	14	No pain
Hair removal	6	No or slight pain
Skin biopsy	10	Pain deep in dermis and subcutis

*Venereal and oral lesions.* Venereal warts were removed without pain after 15–30 minutes' treatment in both men and women. Biopsies of penile lesions can also be done, as incisions in the frenulum. On the lips and oral mucosa the penetration of the anesthetic is rapid and superficial lesions can be removed without pain.

*Painful ulcers.* We have used the composition with good effect in patients with painful leg ulcers and painful ulcers in patients with pemphigus and pemphigoid. When the anesthetic cream is left on the ulcer the effect lasts for several hours, which is useful when dressing changes are painful. The anesthetic cream has been used in 3 patients with severe herpes simplex on the lips to allow an otherwise quite painful scraping of the lesions.

### DISCUSSION

Superficial dermal analgesia can be obtained after epicutaneous application of compositions containing 10% of the amino-ether ketocain which produced adequate skin analgesia for split-skin grafting procedures and dermabrasion (2, 3, 4). The relative chemical instability of the substance, however, as well as the presence of local irritation, especially after repeated application, was a drawback. We have therefore tested water emulsions instead of alcoholic solvents in the compositions. By using a eutectic mixture of two well-tried local anesthetic bases, lidocaine and prilocaine, it has been possible to increase the droplet concentration in the water emulsion from about 20% in a lidocaine emulsion to nearly 80% in the eutectic mixture composition. In the experimental studies preceding our clinical pilot study this was found to increase the dermal analgesic properties considerably.

In contrast to the findings with the ketocaine formulations, we have not observed any signs of local irritation or itching with the eutectic mixture cream. On the other hand there was a slight blanch-

ing caused by vasoconstriction in the skin treated with the lidocaine–prilocaine cream. This effect disappeared within 2 hours after removal of the bandage.

The anesthetic mixture has been found to be especially useful in children and for superficial surgical procedures. It gives a complete anesthesia of the superficial skin and was found to be useful for dermabrasion, scrapings and epidermal surgery. When removing more deeply situated tumours, pain is felt in the subcutis. Superficial atheroma and steatoma multiplex could be removed through a small incision but slight pain was felt when traction was exerted on the capsule with forceps.

A disadvantage with the method is that it can take up to one hour before the anesthesia is complete. We have therefore often instructed the patients to apply the anesthetic themselves before the visit. When applying it they should be careful to get an even distribution, especially if there are elevated tumours. Usually only small areas were anesthetized. We have never applied more than 5 g of the cream at the same time, which is enough to cover an area of 3–5 dm<sup>2</sup> and corresponds to a maximum total dose of 250 mg.

### REFERENCES

1. Juhlin, L., Evers, H. & Broberg, F.: Inhibition of hyperhidrosis by topical application of a local anesthetic composition. *Acta Dermatovener (Stockholm)* 59: 556, 1979.
2. Petterson, L.-O.: Percutaneous anaesthesia for taking split skin grafts. *Scand J Plast Reconstr Surg* 11: 79, 1977.
3. Pontén, B. & Ohlsén, L.: Skin surface application of ketocaine to provide local anaesthesia for cutting split skin grafts. *Br J Plast Surg* 30: 251, 1977.
4. Östrup, L. T. & Edström, H. H.: Percutaneous analgesia with Astra 2358 for taking split-thickness skin grafts. A preliminary report. *Acta Anaesthesiol Scand [Suppl.]* 70: 92, 1978.
5. Shelley, W. B.: The razor blade in dermatologic practice. *Cutis* 16: 843, 1975.