

Ia-LIKE ANTIGENS IN LICHEN PLANUS

Ulla Malmnäs Tjernlund

Department of Dermatology, University Hospital, Uppsala, Sweden

Abstract. The occurrence of Ia-like antigens in the skin of patients with lichen planus was studied by an indirect immunofluorescence (IIF) technique with use of immunosorbent-purified anti-Ia antibodies. Normal skin from the patients and skin from healthy persons showed dermal histiocytes and epidermal suprabasal dendritic cells expressing these antigens. In lichen planus lesions Ia-like antigens were found on virtually all mononuclear cells in the dermal infiltrate and showed an intercellular pattern in the epidermis. The finding of cells expressing Ia-like antigens in the dermal infiltrate, most probably activated T lymphocytes, renders likely a cell-mediated type of reaction in the pathogenesis of lichen planus.

Key words: Ia-like antigens; Immunosorbent-purified antibodies; Immunofluorescence; Lichen planus; Activated T cells

Lichen planus has a typical clinical and histopathological picture. The latter is characterized by a dermal, band-like round cell infiltrate dominated by lymphocytes, pressing on a degenerated and destroyed basal cell layer of the epidermis (12). The etiology is unknown. In a few cases a drug can cause lesions identical with those seen in idiopathic lichen planus. This might indicate that the disease has an immunological basis. That lichen planus like eruptions can be seen as a manifestation of the graft-versus-host disease in bone-marrow transplanted patients points in the same direction (19).

Recently several reports have indicated that the dermal lymphocytes in lichen planus are of the T-cell type (1, 2, 4, 8, 21, 22). In contrast to all B cells, only sub-populations of T cells express Ia-like antigens¹ (rev. 6). It therefore seemed of value to examine the skin of lichen planus patients for the presence of these antigens. This was done with an indirect immunofluorescence (IIF) technique using immunosorbent-purified hetero-anti-Ia-antibodies. It was found that virtually all dermal cells in lichen planus express Ia-like antigens. Furthermore, an intercellular pattern of these antigens was revealed in the epidermis above the dermal infiltrate in a way which previously we have only seen in certain stages of mycosis fungoides (13).

MATERIAL AND METHODS

Skin biopsies were taken from normal and affected skin from 11 patients with lichen planus and from lesions in 66 patients with various other skin diseases (Table I) using a punch 3-4 mm in diameter. The biopsies were quick-frozen in isopentane at -70° and stored at the same temperature unless sectioned immediately. Sections 6 µm thick were cut on a cryostat.

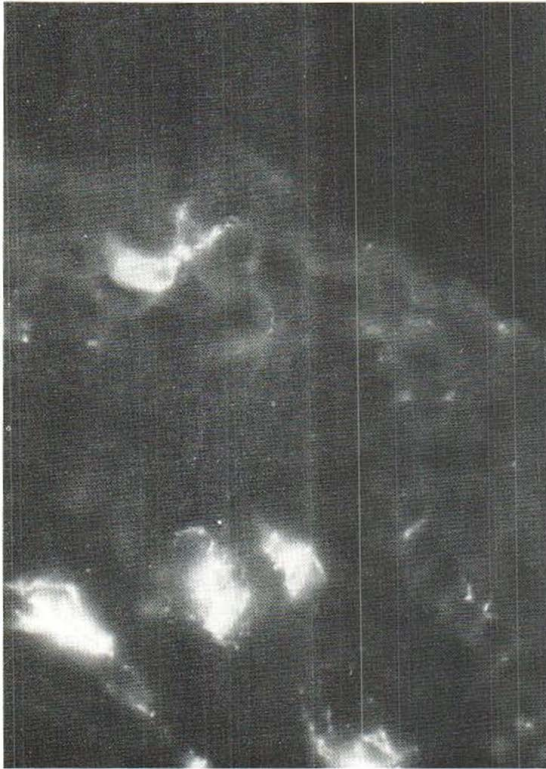Antiserum

The specific antibodies directed against Ia (HLA-DR) antigens used in this study were produced by initial purification of the IgG fraction of a previously described rabbit anti-Ia-serum (10) on a Sepharose-coupled protein A affinity chromatography column (see ref. 10) followed by purification of the specific anti-Ia-antibodies on Sepharose-coupled highly purified Ia antigens obtained from the lymphocytes of a patient suffering from chronic lymphatic leukemia (11).

Immunofluorescence method

The air-dried 6 µm sections were initially washed in phosphate-buffered saline (PBS), pH 7.2, and then separately incubated with 50 µl portions of the diluted specific antibodies (see above). The antibodies were diluted in PBS (pH 7.2) containing 4% bovine serum albumin (BSA). The concentration of IgG protein was varied from 0.5 to 0.004 mg ml⁻¹. The antibodies were allowed to react with the skin sections for 30 min at room temperature in a humid atmosphere, then washed extensively in PBS and allowed to react with specific fluorescein-isothiocyanate (FTC)-conjugated swine anti-rabbit IgG (Dakopatts, Denmark, lot 107) at a working protein concentration of about 0.1 mg ml⁻¹. After an incubation time of 30 min and several washes, the sections were mounted in glycerol in PBS, pH 7.2, and examined in a Leitz Orthoplan fluorescence microscope with incident light and blue narrow band activation (filter combination K 480, 2 KP 490, TK 510/K515, secondary filter K 510), illuminated with a Philips Xenon XBO 75 lamp. The slides were read blind and decoded after examination.

¹ The gene product(s), coded for by a locus (or several loci) closely associated or identical with the HLA-D locus of the major histocompatibility complex (MHC) in man are called HLA-DR antigens, or, in analogy with the terminology used in other species, Ia-antigens. Antigens reacting with the immunosorbent-purified hetero-anti-Ia (HLA-DR)-antibodies are for brevity called Ia-like antigens in this study.



Figs. 1-4. Immunofluorescence of thin sections of skin biopsies after indirect staining with immunosorbent-purified anti-Ia-antibodies.

Fig. 1. Normal skin, with one epidermal dendritic cell and several dermal cells stained.

Specificity tests

The specificity of the antibody binding was assessed by replacing the antibodies in the first step of the IIF method by normal rabbit serum and normal rabbit IgG and by incubating the sections in a single step with the FTC-conjugated swine anti-rabbit IgG.

Blocking tests

The specific antibodies (25 μ l) were diluted in PBS-BSA (4%) to an IgG concentration of about 0.4 mg ml⁻¹. Packed, washed cells (50 μ l) of an Ia-negative T-cell line (MOLT cells) and an Ia-positive B-lymphoma cell line (Raji cells) respectively were mixed with the antibodies on a Whorl mixer and incubated for 45 min on ice. The mixture was centrifugated and the supernatant was used in successive dilutions in the first step in the IIF technique. The FTC-conjugated anti-rabbit IgG was used as the second step, as described above. Sections from three different patients with lichen planus and sections from normal skin were investigated in this way, and on the same occasion a dilution series of sections from the same patients, using the specific antibodies was prepared. The slides were read blind.

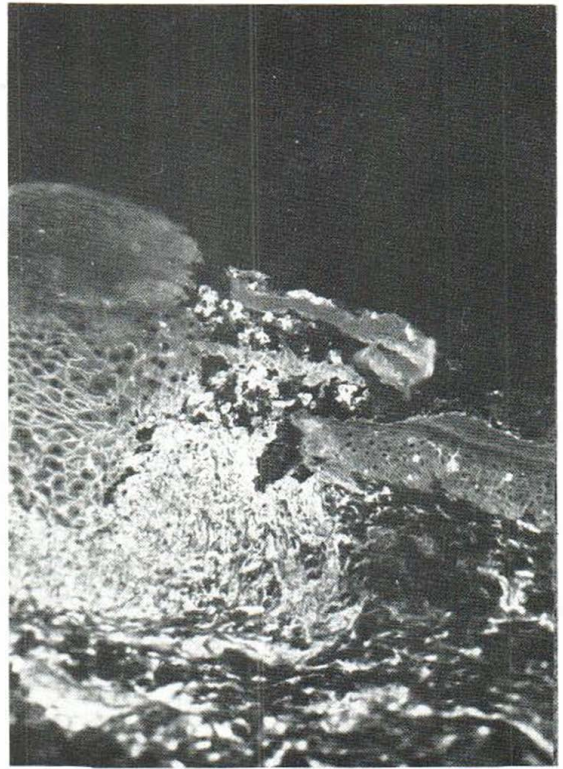


Fig. 2. Perilesional lichen planus. Note the epidermal intercellular staining in the lesion above the dermal infiltrate, while the normal epidermis (*right*) shows only a few stained dendritic cells in a suprabasal position.

Peripheral blood

This was drawn from healthy donors and lymphocytes were separated by the Isopaque-Ficoll technique (3). Membrane-bound Ia-like antigens were sought by the IIF method with use of the specific antibodies.

Hematoxylin-eosin staining

Alternate cryostat sections and also sections previously examined for fluorescence were stained with hematoxylin and eosin. The same stain was used on parallel biopsies fixed in formalin.

RESULTS

Biopsies from 11 patients with a clinically and histopathologically clear lichen planus were investigated with an IIF technique for the occurrence of Ia-like antigens, using immunosorbent purified antibodies (10, 11). None of the patients showed the hypertrophic type of lesion.

Specificity tests

The IIF technique demands accurate controls to provide guarantees for the specificity of the staining, even when immunosorbent-purified antibodies are used. Replacement of the specific antibodies by normal rabbit serum and normal rabbit IgG in the first step of this technique, and use of the second step alone gave no staining of either epidermal or dermal cells.

Further specificity tests involved blocking tests with absorption of the specific antibodies on Ia-positive Raji cells and Ia-negative MOLT cells, respectively. In normal skin and in skin from lichen planus lesions, the MOLT supernatant used in the first step of the IIF technique gave the same picture as the specific antibodies, but with a dilution effect of 3-4 dilution steps in different cases. The Raji supernatant used in the same way completely quenched the epidermal and dermal staining.

The proportion of Isopaque-Ficoll isolated lymphocytes that stained with the anti-Ia antibodies in peripheral blood from healthy donors varied between 13 and 16%, with a mean of 14%.

Staining for Ia-like antigens

In the biopsies from the lichen planus lesions it was found that virtually all of the cells infiltrating the upper part of the dermis in a band-like way stained with the antibodies, giving a rim-like membrane pattern (Fig. 4). Furthermore, above these round cells positive for Ia-like antigens, the epidermis showed an intercellular staining with the antibodies (Figs. 2 and 3).

In 9 patients the intercellular staining could be seen in the whole epidermis except in one to three layers just below the stratum corneum. In most

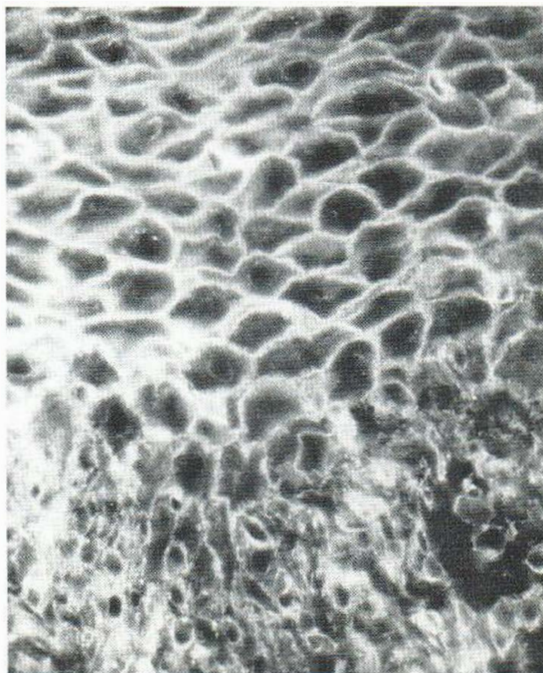


Fig. 3. Lichen planus. Epidermal-dermal junction.

sections it showed a brilliant, regular pattern. In a few of the 40-50 sections studied from each biopsy an irregular epidermal staining was seen. This phenomenon seemed to occur mainly at the edges of the lesion nearest normal skin (Fig. 2). In 2 patients the intercellular staining was limited to the basal third of the epidermis in all sections examined.

The same epidermal intercellular pattern was observed in one patient with discoid lupus erythematosus (LE) who after several years of skin lesions showed serological signs of a transition to systemic LE. The histology in this case showed a dense band-like lymphocyte-dominated dermal infiltrate in a lichenoid way. Four patients with discoid LE, in whom the dermal infiltrate was more sparse and not associated with the epidermis, showed an epidermal Ia pattern as in normal skin.

In various other dermatoses (Table I) examined in this study there was no epidermal intercellular staining with the antibodies. In normal skin from lichen planus patients the epidermal pattern was the common one with dendritic cells in a suprabasal position (9) and histiocytic cells in the corium staining with the antibodies (Fig. 1). The epidermal and dermal staining was brilliant at an IgG-protein con-

Table I.

Diagnosis	No
Atopic dermatitis	4
Basal cell carcinoma	8
Contact dermatitis	10
Dermatitis herpetiformis	3
Ichthyosis vulgaris	5
Lichen planus	11
Lupus erythematosus	5
Polymorphous light eruption	3
Psoriasis	6
Various other skin diseases	22
Total	77

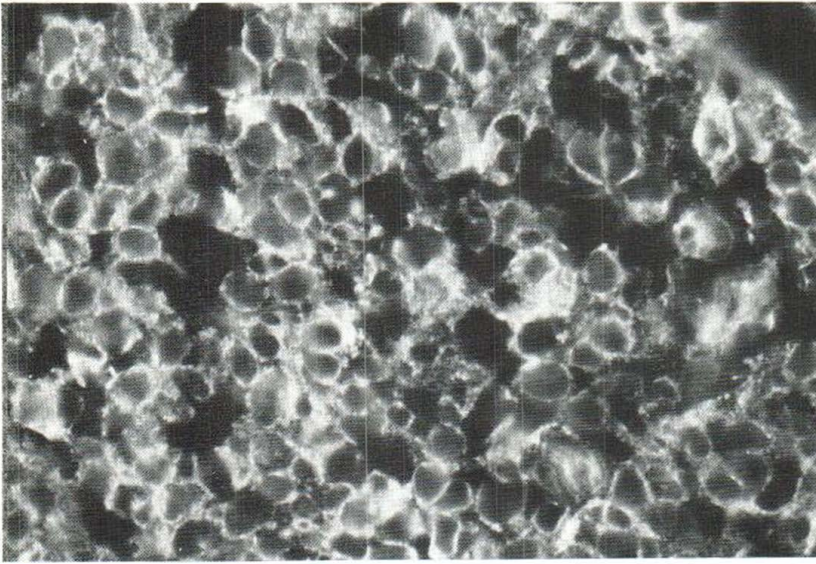


Fig. 4. Lichen planus. Dermal infiltrate.

centration of 0.5 to 0.125 mg ml⁻¹, then gradually faded and was no longer detectable at a concentration of 0.004 mg ml⁻¹.

DISCUSSION

The intercellular occurrence of Ia-like antigens in the epidermis of lichen planus might seem a confusing finding. The only cell types in normal epidermis expressing these antigens are the dendritic Langerhans (9, 16, 20) and indeterminate (17) cells. One possible explanation could be a shedding of Ia-like antigens from dermal cells *in vitro* or *in vivo*. Shedding of Ia-like antigens from peripheral B lymphocytes seems to be rather sparse (L. Klareskog, personal communication), but this fact does not of course rule out the possibility that Ia-positive cells in the tissues behave differently.

Other possible explanations are a proliferation of Langerhans cells which normally express Ia-like antigens, or shedding *in situ* from these cells. The destroyed basal cell layer might also allow immigration of an abnormal number of cells other than lymphocytes expressing these antigens, as a part of the pathological or repair process.

A switch-on in the pathological skin of latent genes for the expression of Ia-like antigens in the highly differentiated keratinocytes might seem a less probable explanation.

The epidermal pattern described in lichen planus was also seen in one out of 5 patients with LE

lesions and has previously been observed in certain cases of mycosis fungoides (13). It was not seen in 65 patients with various other dermatological diseases (Table I).

According to ultrastructural studies, the primary event in the lichen planus lesions is the liquefaction degeneration of the basal epidermal layer, while the inflammatory infiltrate comes later (18). We found that the epidermal intercellular staining was always accompanied by the band-like dermal infiltrate. It would therefore be interesting to study the situation of the epidermal Ia-like antigens in very early lesions with a damaged basal cell layer but with no infiltrate.

The dermal infiltrate in lichen planus is dominated by lymphocytes (12). Using different techniques, several research groups have shown the T-cell nature of these cells (1, 2, 4, 8, 21, 22). The majority of T cells, in contrast to B cells, do not express Ia-like antigens. There have been reports, however, that suppressor T cells do so (rev. 6). Recently, it has also been demonstrated that peripheral human T cells in a mixed leukocyte culture (MLC) synthesize and express Ia-like antigens (5). Besides B cells and the above-mentioned types of T cells, antigen-presenting macrophages (15), epidermal Langerhans cells (9, 16, 20) and at least some of the so-called epidermal indeterminate cells (17) express the Ia-like antigens. The former assumption that Ia-like antigens were confined only to cells belonging to the immune system is not in

keeping with recent data indicating that cells in several types of epithelia (24), endothelial cells (7) and melanoma cells grown *in vitro* (23, 25) also express these antigens.

The presence of Ia-like antigens on the lymphocytes of the lichen planus dermal infiltrate as indicated by this study might mean that these antigens are transferred from macrophages and passively attached or that the lymphocytes are T suppressor cells. Ultrastructural studies have shown that contact sites frequently occur between lymphocytes and macrophages in the dermal infiltrate of lichen planus (14), suggesting an antigen-presenting situation. A more probable explanation for the findings would thus be that there is a production of Ia-like antigens by activated T cells in the dermal infiltrate, triggered by foreign antigens, in analogy with the MLC assays mentioned above. The expression of Ia-like antigens on dermal T lymphocytes in lichen planus would thus be looked upon as a differentiatial or functional marker in a specific phase of the T-cell cycle and gives further support to a cell mediated type of reaction in the pathogenesis of lichen planus.

ACKNOWLEDGEMENTS

Excellent technical assistance was given by Ms Eva Hagforsen.

The immunosorbent-purified anti-Ia antibodies were generously supplied by Drs L. Klareskog and K. Wiman. The MOLT and Raji cells were kindly provided by Dr K. Nilsson.

This work was supported by grants from the Swedish Medical Research Council (No. B 80-12 x-00769 15 C), the Tore Nilsson Foundation and "Förenade Liv" (Mutual Group Life Insurance Company) Stockholm.

REFERENCES

- Alario, A., Ortonne, J.-P., Schmitt, D. & Thivolet, J.: Lichen planus: study with anti-human T lymphocyte antigen (anti-HTLA) serum on frozen tissue sections. *Br J Dermatol* 98: 601, 1978.
- Bjerke, J. R. & Krogh, H. K.: Identification of mononuclear cells *in situ* in skin lesions of lichen planus. *Br J Dermatol* 98: 605, 1978.
- Böyum, A.: Separation of leucocytes from blood and bone marrow. *Scand J Clin Lab Invest* 21: suppl. 97, 1968.
- Braathen, L. R., Dähl, B.-L. & Meitbye, O. J.: Immunological *in situ* identification of the lymphoid cells in the skin infiltrate of lichen planus. *Clin Exp Dermatol* 4: 175, 1979.
- Evans, R. L., Faldetta, T. J., Humphreys, R. E., Pratt, D. M., Yunis, E. J. & Schlossman, S. F.: Peripheral human T cells sensitized in mixed leukocyte culture synthesize and express Ia-like antigens. *J Exp Med* 148: 1440, 1978.
- Hämmerling, G. J. (rev): Tissue distribution of Ia antigens and their expression on lymphocyte subpopulations. *Transplant Rev* 30: 64, 1976.
- Hirschberg, H., Moen, T. & Thorsby, E.: Specific destruction of human endothelial cell monolayer by anti-DR-w antisera. *Transplantation* 28: 116, 1979.
- Hovmark, A.: Acid α -naphthyl acetate esterase staining of T-lymphocytes in human skin. *Acta Dermatovener (Stockholm)* 57: 497, 1977.
- Klareskog, L., Malmnäs Tjernlund, U., Forsum, U. & Peterson, P. A.: Epidermal Langerhans cells express Ia antigens. *Nature* 268: 248, 1977.
- Klareskog, L., Trägårdh, L., Lindblom, J. B. & Peterson, P. A.: Reactivity of a rabbit antiserum against highly purified HLA-DR antigens. *Scand J Immunol* 7: 199, 1978.
- Klareskog, L., Trägårdh, L., Rask, L. & Peterson, P. A.: Isolation and characterization of detergent-solubilized human HLA-DR transplantation antigens. *Biochemistry* 18: 1481, 1979.
- Lever, W. F. & Schaumburg-Lever, G.: *Histopathology of the Skin*. 5th ed., 1975.
- Malmnäs Tjernlund, U.: Epidermal expression of HLA-DR antigens in mycosis fungoides. *Arch Dermatol Res* 261: 81, 1978.
- Medenica, M. & Lorincz, A.: Lichen planus: an ultrastructural study. *Acta Dermatovener (Stockholm)* 57: 55, 1977.
- Rosenthal, A. S.: Determinant selection and macrophage function in genetic control of the immune response. *Immunol Rev* 40: 136, 1978.
- Rowden, G., Lewis, M. G. & Sullivan, A. K.: Ia antigen expression on human epidermal Langerhans cells. *Nature* 268: 247, 1977.
- Rowden, G., Phillips, T. M. & Lewis, M. G.: Ia antigens on indeterminate cells of the epidermis: immunoelectronmicroscopic studies of surface antigens. *Br J Dermatol* 100: 531, 1979.
- Sarkany, I. & Gaylarde, P. M.: Ultrastructural and light microscopic changes of the epidermo-dermal junction. *Trans St John's Hosp Dermatol Soc* 57: 139, 1971.
- Saurat, J. H., Didier-Jean, L., Gluckman, E. & Busnel, A.: Graft versus host reaction and lichen planus-like eruption in man. *Br J Dermatol* 92: 591, 1975.
- Stingl, G., Katz, S. I., Abelson, L. D. & Mann, D. L.: Immunofluorescent detection of human B cell alloantigens on S-Ig-positive lymphocytes and epidermal Langerhans cells. *J Immunol* 120: 661, 1978.
- Tan, R. S.-H., Byrom, N. A. & Hayes, J. P.: A method of liberating living cells from dermal infiltrate: studies on skin reticuloses and lichen planus. *Br J Dermatol* 93: 271, 1975.
- Walker, D. M.: Identification of subpopulations of lymphocytes and macrophages in the infiltrate of lichen planus lesions of skin and oral mucosa. *Br J Dermatol* 94: 529, 1976.
- Wilson, B. S., Indiveri, F., Pellegrino, M. A. & Fer-

- rone, S.: DR (Ia-like) antigens on human melanoma cells. *J Exp Med* 149: 658. 1979.
24. Wiman, K., Curman, B., Forsum, U., Klareskog, L., Malmnäs Tjernlund, U., Rask, L., Trägårdh, L. & Peterson, P. A.: Occurrence of Ia antigens on tissues of non-lymphoid origin. *Nature* 276: 711. 1978.
25. Winchester, R. J., Wang, C-Y., Gibofsky, A., Kunkel, H. G., Lloyd, K. O. & Old, L. J.: Expression of Ia-like antigens on cultured human malignant melanoma cell lines. *Proc Natl Acad Sci USA* 75: 6235. 1978.

Received December 14, 1979

U. Malmnäs Tjernlund, M.D.
Department of Dermatology
University Hospital
S-75014 Uppsala 14
Sweden