

## DISCUSSION

Photochemotherapy has been used in some diseases in which itching is one of the most disturbing symptoms, e.g. in lichen planus (6) and in atopic dermatitis (3, 5) with good results in both complaints. Since itching is the main symptom in nodular prurigo as well, we decided to try photochemotherapy for its treatment. We tried trioxsalen bath instead of systemic methoxsalen because trioxsalen bath plus UVA has proved effective and safe in the treatment of psoriasis (1, 4).

Our results during both initial and maintenance therapy were unexpectedly good. The mode of action of the therapy may be triphasic. First of all, photochemotherapy blocks the rapid turnover in epidermal cells. This reduction leads to a reduction of the pseudoepitheliomatotic hyperplasia of the epidermis. The treatment also reduces the numbers of inflammatory cells in the dermis. The main effect of photochemotherapy in nodular prurigo seems to consist in breaking the vicious circle of itching and scratching.

Local application of the photosensitizing drug is more advisable than the systemic mode because it is obviously only with difficulty that the drug reaches the lesions when given perorally. The pharmacological basis of the beneficial effect remains obscure. The mechanism may be of the same type as that seen in the treatment of pruritus in uraemia with UVB (2), whatever it might be.

## REFERENCES

1. Fischer, T. & Alsins, J.: Treatment of psoriasis with trioxsalen baths and dysprosium lamps. *Acta Dermatovener (Stockholm)* 56: 383, 1976.
2. Gilchrist, B. A., Rowe, J. W., Brown, R. S., Steinman, T. I. & Arndt, K. A.: Relief of uremic pruritus with ultraviolet phototherapy. *N Engl J Med* 297: 136, 1977.
3. Gschnait, F., Hönigsmann, H., Konrad, K., Fritsch, P. & Wolff, K.: Photochemotherapie (PUVA) bei Neurodermatitis. *Z Hautkr* 52: 1219, 1977.
4. Hannuksela, M. & Karvonen, J.: Trioxsalen bath plus UVA effective and safe in the treatment of psoriasis. *Br J Dermatol* 99: 703, 1978.
5. Morison, W. L., Parrish, J. A. & Fitzpatrick, T. B.: Oral psoralen photochemotherapy of atopic eczema. *Br J Dermatol* 98: 25, 1978.
6. Ortonne, J. P., Thivolet, J. & Sannwald, C.: Oral photochemotherapy in the treatment of lichen planus (LP). *Br J Dermatol* 99: 77, 1978.
7. Rook, A. & Wilkinson, D. S.: Eczema, lichen simplex and prurigo. *In* Textbook of Dermatology, pp. 256-294 (ed. A. Rook, D. S. Wilkinson & F. J. G. Ebling). Blackwell, Oxford, 1972.

## Induction of Delayed-Type Sensitivity to Leishmania Parasite in a Case of Leishmaniasis Cutanea Diffusa with BCG and Cord-Factor (Trehalose-6-6'-Dimycolate)

Haim A. Cohen

*Department of Dermatology and Venereology of the Hadassah University Hospital, Jerusalem, Israel*

Received March 7, 1979

**Abstract.** The delayed hypersensitivity against the leishmania parasite was restored to a patient who had suffered from diffuse cutaneous leishmaniasis (DCL) for 26 years, by the application of an ointment containing heat-killed and lyophilized BCG and cord-factor (trehalose-6-6'-dimycolate) after stripping the affected and adjacent areas with scotch-tape.

A 46-year-old Patient, suffering from leishmaniasis lesions on the nose, cheeks and upper lip which appeared 26 years ago, was hospitalized in our department. According to his history, 11 years before the appearance of these lesions he suffered from leishmaniasis nodosa localized to the lower and flexor side of his right arm, where a scar can be seen. During these 26 years, he was treated with all known therapeutic modalities, including five surgical interventions, with no beneficial effect; the lesions merely reappeared and multiplied (Fig. 2).

In the repeated microscopic examinations,

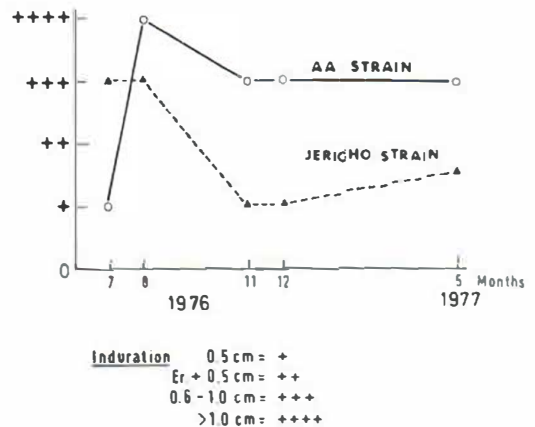


Fig. 1. Leishmanin reaction.

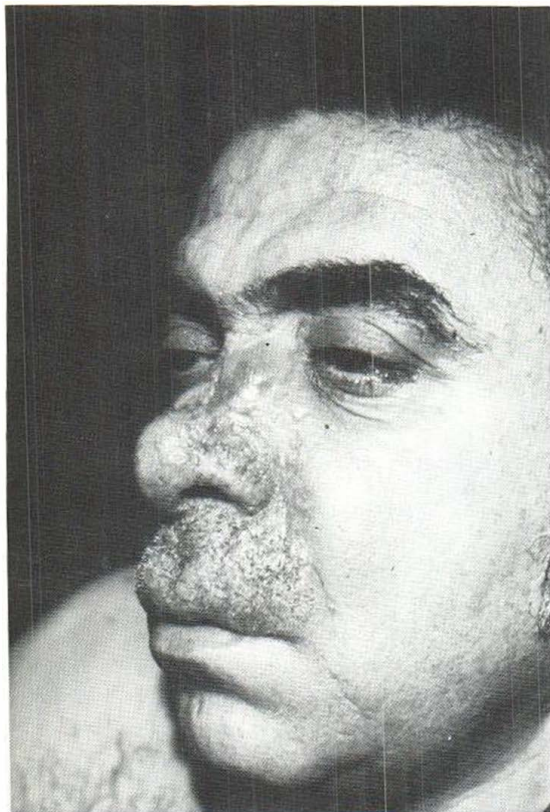


Fig. 2. Patient before treatment.

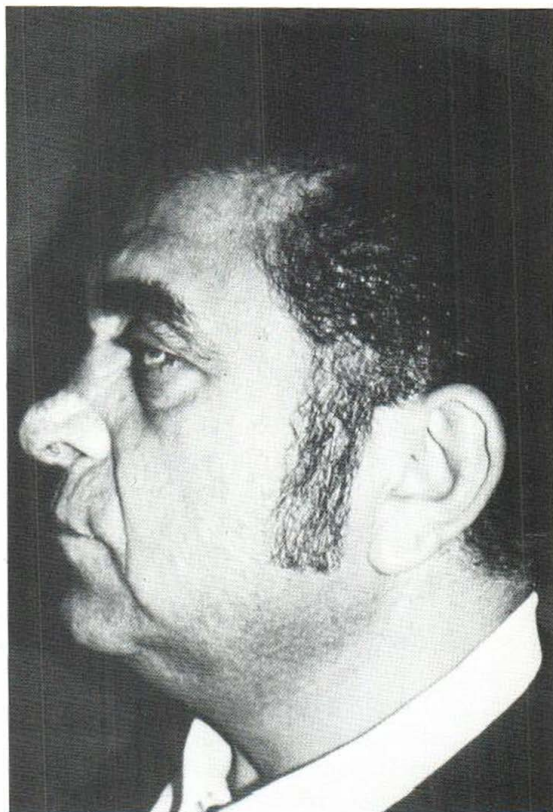


Fig. 3. Patient after treatment.

macrophages full of LD bodies were found in great numbers and mastigotes were grown in cultures. The leishmanin test was negative to Jericho strain and to his own parasites. The Mantoux test was strongly positive.

Treatment with infusions of 150 mg of amphotericin B, given once a week for a 6-week-period, was unsuccessful. The leishmanin test was still negative. The infusions of amphotericin B were discontinued and replaced with applications of an ointment containing 1 500  $\mu\text{g/g}$  heat-killed and lyophilized BCG and 75  $\mu\text{g/g}$  cord factor (trehalose-6,6'-dimycolate), which is a glycolipid extracted from *Mycobacteria* (9) and has been shown to have granulomagenic effect and adjuvant activity (13) and also attracts macrophages and activates them (8) apparently with participation of lymphocytes in the process of activation (10). Six applications were made after stripping for 30 times the involved areas and 2-3 cm of the surrounding normal skin once every 15 days. The ointment was covered with Saran-wrap and kept in place for 48 hours. This treatment produced a very strong local, inflammatory reaction

and the patient began to develop a positive reaction to leishmanin, which was stronger at the beginning to the Jericho strain than to his own parasites, became subsequently stronger than his own strain, and remained so to the present day—almost 2 years after his hospitalization (Fig. 1).

The infusions of amphotericin B were reinstated and 170 mg was given once each 15 days for a period of 4 months. The induction of sensitivity to the leishmania parasite, and the amphotericin B treatment produced ulceration of some nodules and absorption of the lesions for the first time in a period of 26 years. Five months later, a few lesions appeared in the upper lip mucosa and were successfully treated with four intralesional injections of 0.1-0.2 ml emetin hydrochloride (Fig. 3).

#### DISCUSSION

*Leishmaniasis cutanea diffusa* was described for the first time in Bolivia (1948) by Barrientos (2) and by Convit & Lapenta in Venezuela (7) the same year. Bryceson (4) reported 33 such cases in Ethiopia, but it has not been found as yet in India, Europe or the Middle East (4), and our case seems

to be the first known in Israel. Convit et al. (5) and Convit & Kerdel-Vegas (6) described the characteristics of this type of cutaneous leishmaniasis. The most important characteristic in connection with the resistance to treatment, chronicity and recurrence of the disease, is the selective anergy condition of the patient against the leishmania parasite. The leishmanin (Montenegro) test is negative.

Unsuccessful attempts have been made in the past by the late Prof. Adler and Prof. Nelken (1) to induce delayed sensitivity to leishmania in normal individuals, by injecting subcutaneously peripheral leukocytes,  $10^5$  organisms, and by blood transfusions of  $3 \times 10^9$  leukocytes from strongly sensitive donors. Bryceon succeeded in transferring sensitivity to leishmanin from strongly positive reactors, to leishmanin-negative patients and normal volunteers by injecting intradermally  $5 \times 10^8$  organisms. This sensitivity lasted from some days up to 3 weeks but did not affect the course of the disease.

It seems therefore that heat-killed and lyophilized BCG bacilli and cord-factor in vaseline, on coming into contact with the leishmaniasis lesions, produce a strong inflammatory reaction, attract and activate macrophages, and induce sensitivity against the leishmania parasite, thus creating the prerequisite condition for the successful antibiotic and chemotherapeutic effect.

#### REFERENCES

1. Adler, S. & Nelken, D.: Attempts to transfer delayed hypersensitivity to leishmania tropica by leukocytes and whole blood. *Trans R Soc Trop Med Hyg* 59: 59-63, 1965.
2. Barrientos, L. P.: Un caso atipico de leishmaniose cutaneo-mucosis (espondia). *Mem Inst Oswaldo Cruz* 46: 417-418, 1948.
3. Bekierkunst, A.: Acute granulomatous response produced in mice by trehalose-6,6'-dimycolate. *J Bacteriol* 96: 958-961, 1968.
4. Bryceon, M. D. A.: Diffuse cutaneous leishmaniasis in Ethiopia. I. Clinical and histological features of the disease. *Trans R Soc Trop Med Hyg* 63: No. 1, 1969.
5. Convit, J., Kerdel-Vegas, F. & Gordon, B.: Disseminated anergic cutaneous leishmaniasis. *Br J Dermatol* 74: 132, 1962.
6. Convit, J. & Kerdel-Vegas, F.: Inoculation to laboratory animals, electron microscopy and fluorescent antibodies studies. *Arch Dermatol* 91: 439-447, 1965.
7. Convit, J. & Lapenta, P.: Sobre un caso de leishmaniasis diseminada. *Rev Pol XVII*, Caracas, 1948.
8. Kelly, M. T.: Activation of guinea-pig macrophages by cell walls of *Mycobacterium bovis*, strain BCG. *Cell Immunol* 26: 254-263, 1976.

9. Lederer, E.: Cord factor and related trehalose esters. *Chem Phys Lipids* 16: 11-21, 1975.
10. Ofek, I. & Bekierkunst, A.: Chemotactic response of leucocytes to cord factor (trehalose-6,6' dimycolate). *J Natl Cancer Inst* 57: 1379-1380, 1976.

## Treatment of Leishmaniasis Recidivens with Intralesional Injections of Emetine Hydrochloride: A Case Report

Haim A. Cohen and Asher Wahaba

*Department of Dermatology and Venereology, Hadassah University Hospital, Jerusalem, Israel*

Received June 16, 1979

**Abstract.** A patient, suffering for 42 years from the late tuberculoid-type of leishmaniasis located in his face, was successfully treated with intralesional injections of emetine hydrochloride. Previous treatments, which included intralesional injections of steroids and concomitant intramuscular injections of antimonials, flayyl, fluorocytosine, infusions of amphotericin B—with and without concomitant treatment by steroids systemically and/or intralesionally—and amphotericin B intralesionally, were altogether ineffective. In addition, the patient underwent five operations in a plastic surgery department.

Cutaneous leishmaniasis is a spectrum disease having in the center the primary nodular leishmaniasis lesion and two poles, which are the diffuse type and the tuberculoid or recidiva type (1). In Israel, the most common is the nodular type, while the recidiva is relatively rare, accounting for only about 10% of the cases observed (4). Recently on our country one case of the diffuse type was found and described (2). These three different variants of the disease are an expression of the underlying immunological mechanism (1). Whilst patients suffering from the nodosa type react to a dilution of leishmanin from 1:100 to 1:10000—with represents the "normergic zone"—those with the late tuberculoid type react to the dilution up to 1:10000000 (5). This is a hyperergic reaction characterizing the tuberculoid type of leishmaniasis.

Patients suffering from the diffuse type show a specific anergy against the parasite, have a negative