

APOPTOSIS IN LICHEN PLANUS AND SEVERAL OTHER DERMATOSES

Intra-epidermal Cell Death with Filamentous Degeneration

Ken Hashimoto

*From Memphis Veterans Administration Hospital and Division of Dermatology, Department of Medicine,
The University of Tennessee Center for the Health Sciences, Memphis, Tennessee, USA*

Abstract. In hyperplastic conditions of the skin, eosinophilic bodies are often observed in the epidermis and upper dermis. These have been named variously Civatte body of lichen planus and dyskeratotic cell of actinic keratosis. In the present studies, it was found that (i) these cells commonly contain whorls of distinct filaments (60-80 Å), which may be attached to desmosomes; (ii) unlike keratinized cells, the cellular envelope was not thickened by the formation of the marginal band; (iii) the cytoplasm contains a large number of vacuoles; (iv) the nucleus is lost by condensation or diffuse disintegration; and (v) these cells could be dropped into the upper dermis and filamentous contents could be released to dermal phagocytes. From these observations it was concluded that Civatte bodies and other eosinophilic bodies of neoplastic and hyperplastic epidermis represent "filamentous degeneration" or premature keratinization of keratinocytes.

Key words: Lichen planus; Lichen amyloidosis; Epidermis; Cell kinetics; Basal cell nevus syndrome

In recent years a new concept "apoptosis", a kind of cell death, has been developed and proposed as a self-regulatory mechanism involved in cell population control in both normal and abnormal tissues (23). The Greek term apoptosis means "dropping-off" of flower petals or leaves and indicates a mechanism which normal as well as abnormal tissue employs to regulate the cell population by controlled cell deletion. Apoptosis is, therefore, complementary to mitosis (23).

Ultrastructurally, the first stage is nuclear condensation and cytoplasmic fragmentation into well-preserved small pieces. In the second stage, these apoptotic bodies are discharged from the epithelium and phagocytosed and digested by phagocytes.

These changes seem to be quite rapid and apoptotic fragments are difficult to see histologically; therefore, the presence of a few apoptotic bodies does not necessarily mean that only a few cells are undergoing apoptotic degeneration in that tissue (23).

Benign versus malignant states may well be balanced between apoptosis and mitosis. For example, in low grade malignancies such as actinic keratosis, a number of "dyskeratotic" cells or individual cell keratinizations are observed, whereas in more malignant epidermoid carcinomas the dyskeratotic cells are overwhelmed by mitotic cells. In the past, dyskeratosis was considered to be a sign of maturity, i.e. a tendency to keratinize, and hence a mark of the benign nature of the condition. Such dyskeratotic cells could be considered to represent the apoptotic process; namely, the host reaction for eliminating tumor cells by accelerating keratinization. If this apoptotic process supersedes mitosis, the tumor remains benign. In a benign hyperplastic condition such diseases as psoriasis, lichen planus (except the atrophic type), discoid lupus erythematosus, primary cutaneous amyloidoses, and reactive hyperplasia of the epidermis may be regulated by apoptosis. In fact, Weedon (32) considered the ultrastructure of Civatte bodies (4, 11) in oral lichen planus (7) to be typical of apoptotic cells as defined by Kerr et al. (23).

As a long-term goal, it is planned to test the following hypotheses: (i) various eosinophilic bodies and cells that are found in various dermatoses involving the epidermis (colloid bodies, hyaline bodies, dyskeratotic cells, etc.) are identical with Civatte bodies in their ultrastructure; (ii) these

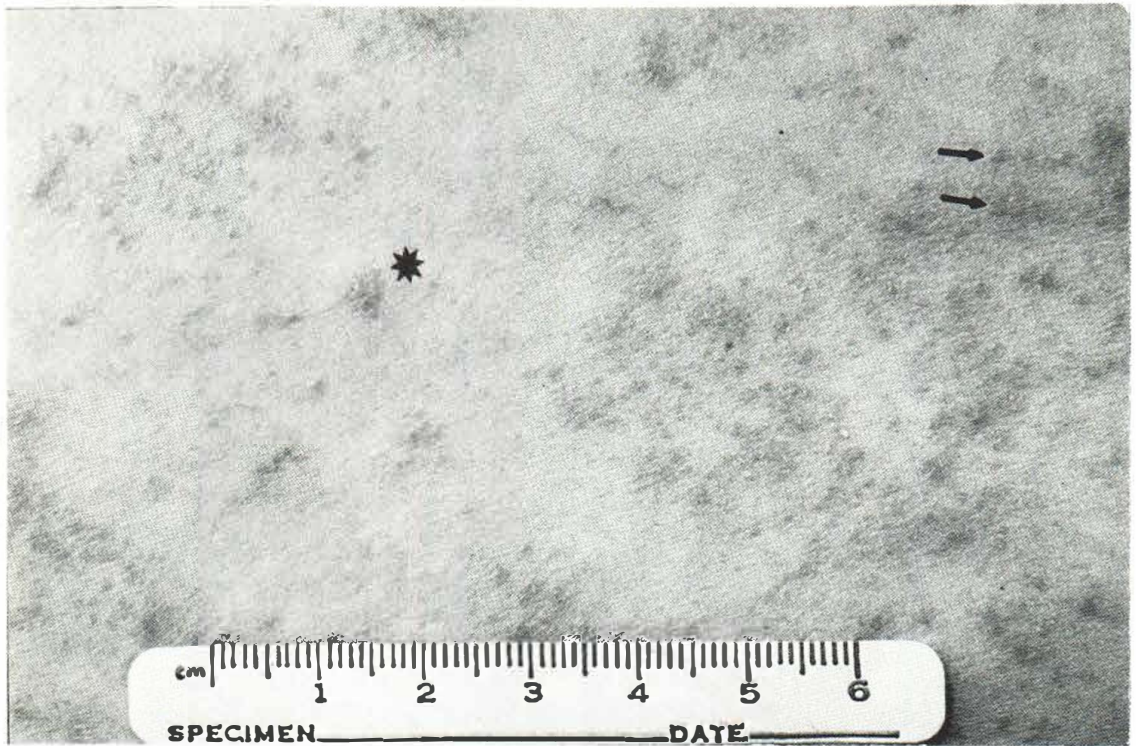


Fig. 1. Lichen planus. Polygonal (*) or angular shaped, flat-topped eruptions and a linear arrangement (arrows) of small papules are seen.

bodies and cells are more frequently present in benign epithelial tumors and hyperplastic conditions or involuting lesions of these, than in others; (iii) these bodies and cells are sublethally damaged keratinocytes which are following a course of premature keratinization; and (iv) this accelerated course of keratinization represents one form of apoptosis as manifested by the epidermal keratinocyte.

In the present study, it will be noted that (i) actinic keratosis, squamous cell carcinoma grade III, palmar and plantar pits of nevoid basal cell epithelioma syndrome, cutaneous amyloidoses and balloon cell nevus contained the same "filamentous cells" which were ultrastructurally identical with the Civatte bodies of lichen planus; (ii) these filamentous cells were derived from keratinocytes and the fibres were intermediate between tonofilaments and keratin filaments in diameter and density; and (iii) the "filamentous degeneration" could be induced experimentally by injecting peroxidase into guinea pig skin (peroxidase-phagocytosed keratinocytes often become filamentous cells).

MATERIALS AND METHODS

Case histories

(i) *Lichen planus*. A 67-year-old white female developed for the first time a generalized pruritic eruption of a few weeks' duration. Physical examination revealed generalized, violaceous, reddish papular eruptions over her entire body surface (Fig. 1). Oral mucous membranes were not involved. Findings from the physical examination of other organ systems and laboratory studies were all within the normal limits. Biopsies taken from several sites showed histologically typical pictures of lichen ruber planus (Fig. 2 A). In addition, there were numerous Civatte bodies (Figs. 2 B, C). New biopsies from eruptions similar to those which contained Civatte bodies were taken for electron microscopic studies.

(ii) *Others*. Ten cases of lichenoid and 2 cases of myeloma-associated amyloidoses (3, 12, 13), 2 cases of nevoid basal cell epithelioma syndrome (14), one case of balloon cell nevus (15), 7 cases of actinic keratosis including that which was studied previously (16), and one case of squamous cell carcinoma grade II (17), were re-examined specifically for Civatte bodies. Normal skin taken from 20 individuals of various age groups serves as control specimens. A random-bred white guinea pig was injected with 1% horseradish peroxidase. Biopsy was taken from the injected site 22-24 hours after the injection. The tissue was

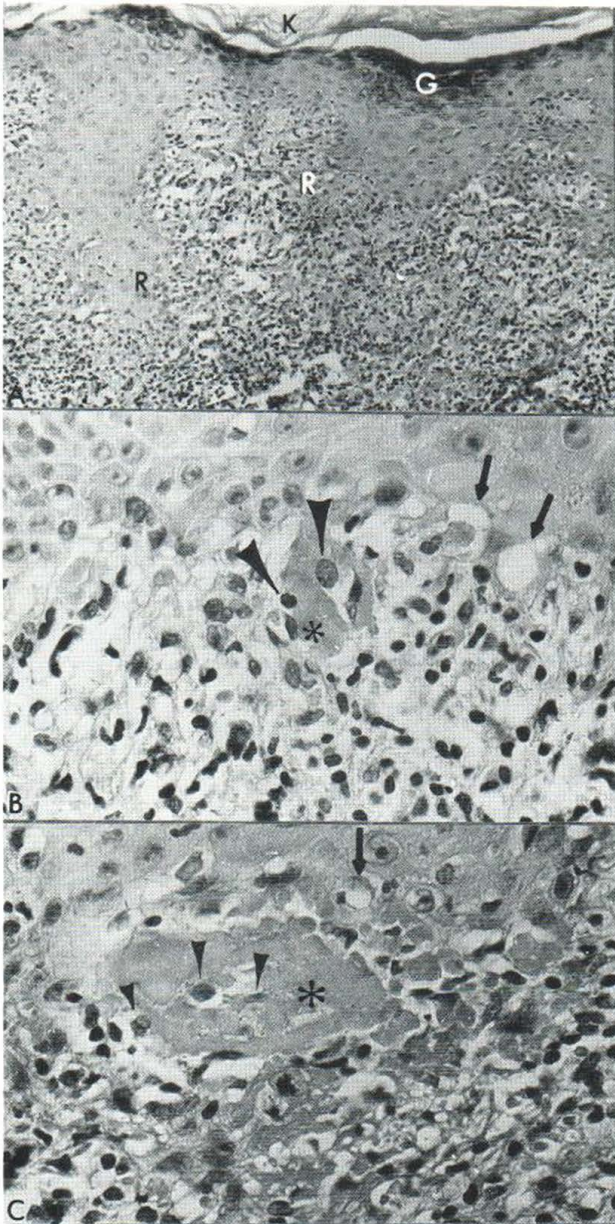


Fig. 2. (A) Lichen planus. Hyperkeratosis (K) and hypergranulosis (G) over the saw tooth-like rete ridges (R) and lymphocytic infiltration hugging these ridges are typical of lichen planus. $\times 100$. (B, C) Lichen planus. The epidermo-dermal junction shows many hydropic basal cells (arrows), strongly eosinophilic Malpighian cells, dense lymphocytic infiltration and hyaline or Civatte bodies (*). Some of these are large and multinucleated (arrowheads). $\times 250$.

processed according to the method of Schneeberger-Keeley & Karnowsky (30) and our previous method (18) to render peroxidase electron dense. After this procedure, the tissue was processed as below. Non-injected guinea pigs served as control.

Preparation of the specimens. All of these specimens were biopsied with 6 mm skin punches under 1% lidocaine local anesthesia. Each specimen was bisected: one-half of the specimen was used for the electron microscopic examination and the remaining half was processed for routine histological examination using H & E stain, alkaline Congo red stain and methyl violet stain. For the last two stains,

amyloid kidney was used as control. Specimens for electron microscopy were cut into 1.0 mm³ pieces, fixed in 5% glutaraldehyde in 0.1 M cacodylate buffer (pH 7.4) for 2 hours and rinsed in the same buffer overnight. Specimens were post-osmicated with 1% osmic acid in the same buffer for 30 min and dehydrated with 50% through absolute ethanol. After 50% ethanol dehydration, specimens were stained *en bloc* with 1% uranyl acetate in 50% ethanol for 15 min. Specimens were embedded in Araldite and thin-sectioned in a Porter-Blum MT-2 Ultramicrotome. Thin sections were stained with 15% uranyl acetate in 50% methanol and then with Reynolds' lead citrate (28). Stained

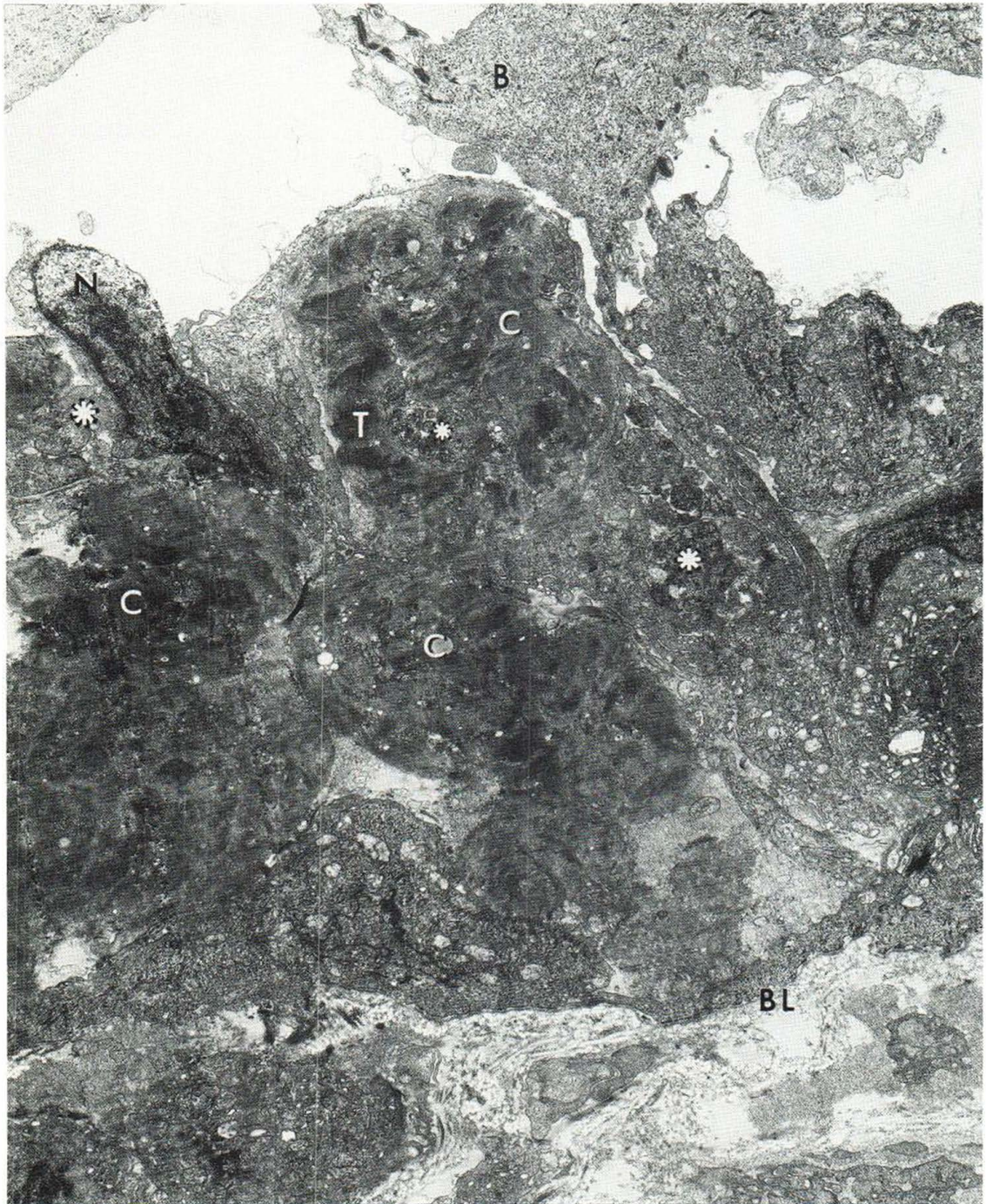


Fig. 3. Lichen planus. Several Civatte bodies (C) are seen in the basal layer below the hydroptic basal cells (B). Some of these are premature "filamentous cells" and still retain the nucleus (N) and/or clumped, electron-dense tonofibrils (T). Fragmentation of cytoplasm and its organelles into small particles is seen (*). BL: Basal lamina, $\times 6700$.

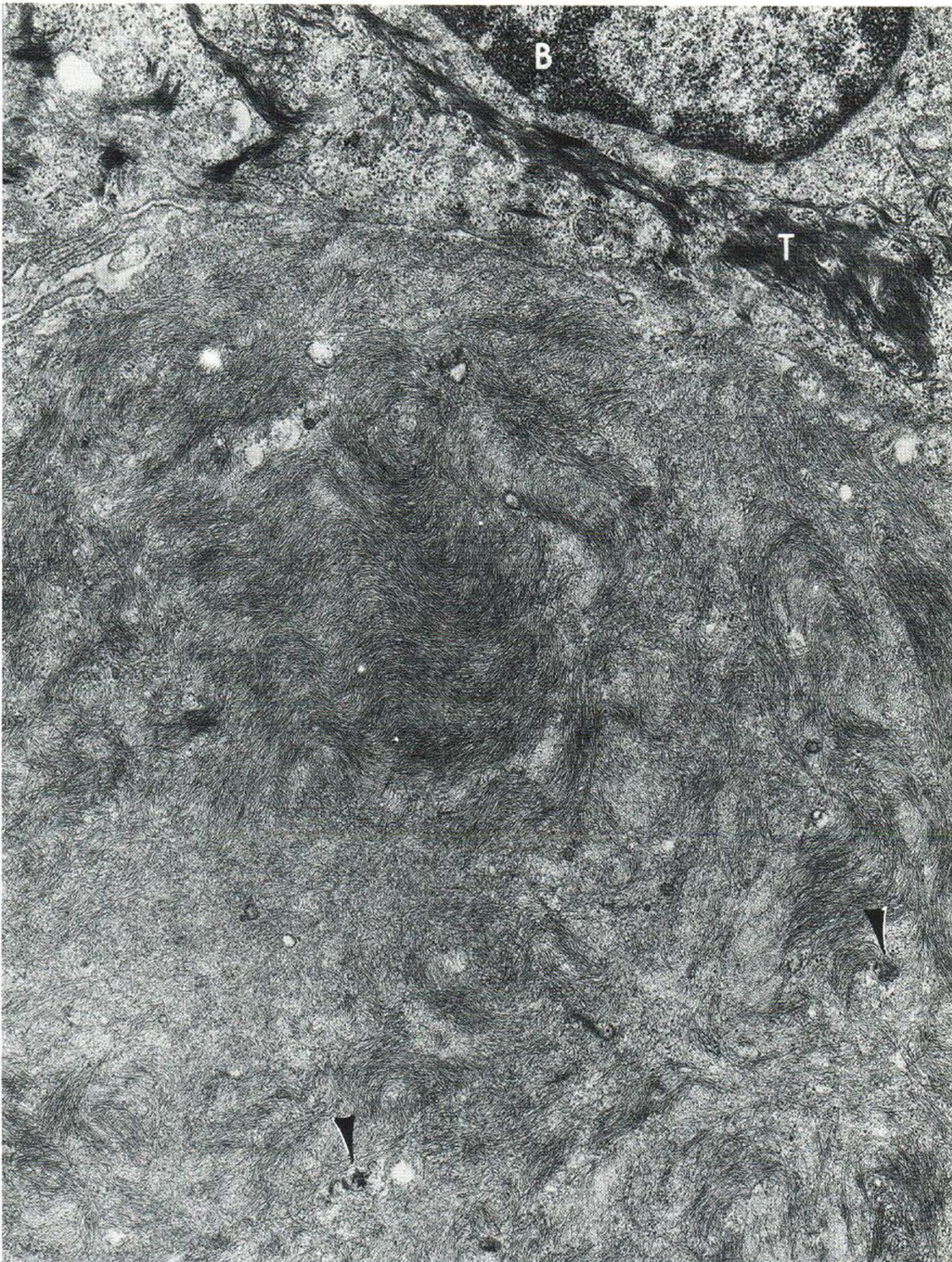


Fig. 4. Lichen planus. A Civatte body or a filamentous cell consists of a whorled mass of filaments. Only a little cellular debris (*arrowheads*) remains in this cell. Compared

with the tonofilaments (*T*) of the normal basal cell (*B*), the filaments of this cell are generally electron-light. $\times 22\ 500$.

sections were examined in an Hitachi HU-12 electron microscope at 125 kV.

Prior to thin-sectioning, 1 μm thick sections were cut from each block and stained with 0.01% Azure B on a hot plate to identify the lesion and confirm the presence of Civatte bodies.

RESULTS

Light microscopy

In lichen planus, in addition to typical histopathological pictures (Fig. 2A), there were a number of eosinophilic bodies compatible with the Civatte bodies (4, 11) (Fig. 2B, C). Large Civatte bodies contained more than one nucleus or nuclear debris (Fig. 2B, C). Alkaline Congo red did not stain these bodies specifically, although some showed a weak staining. Under polarized light (with 360° specimen rotation) no greenish birefringence was detected in Congo red stained Civatte bodies. Methylene blue did not produce any metachromatic staining in these bodies. In other conditions the identical eosinophilic bodies ("dyskeratotic cells") were found in various numbers and localizations, mostly in the lower epidermis or upper dermis.

Electron microscopy

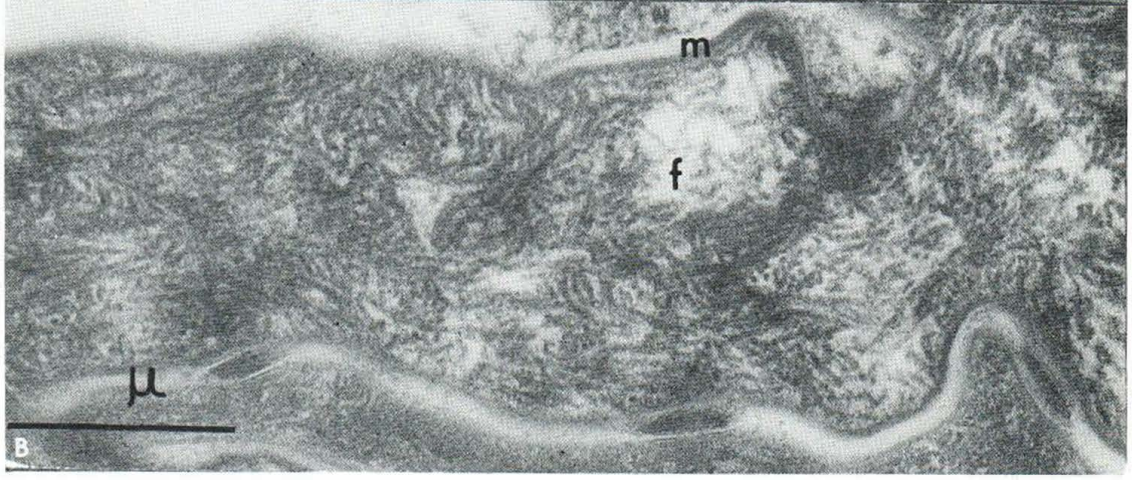
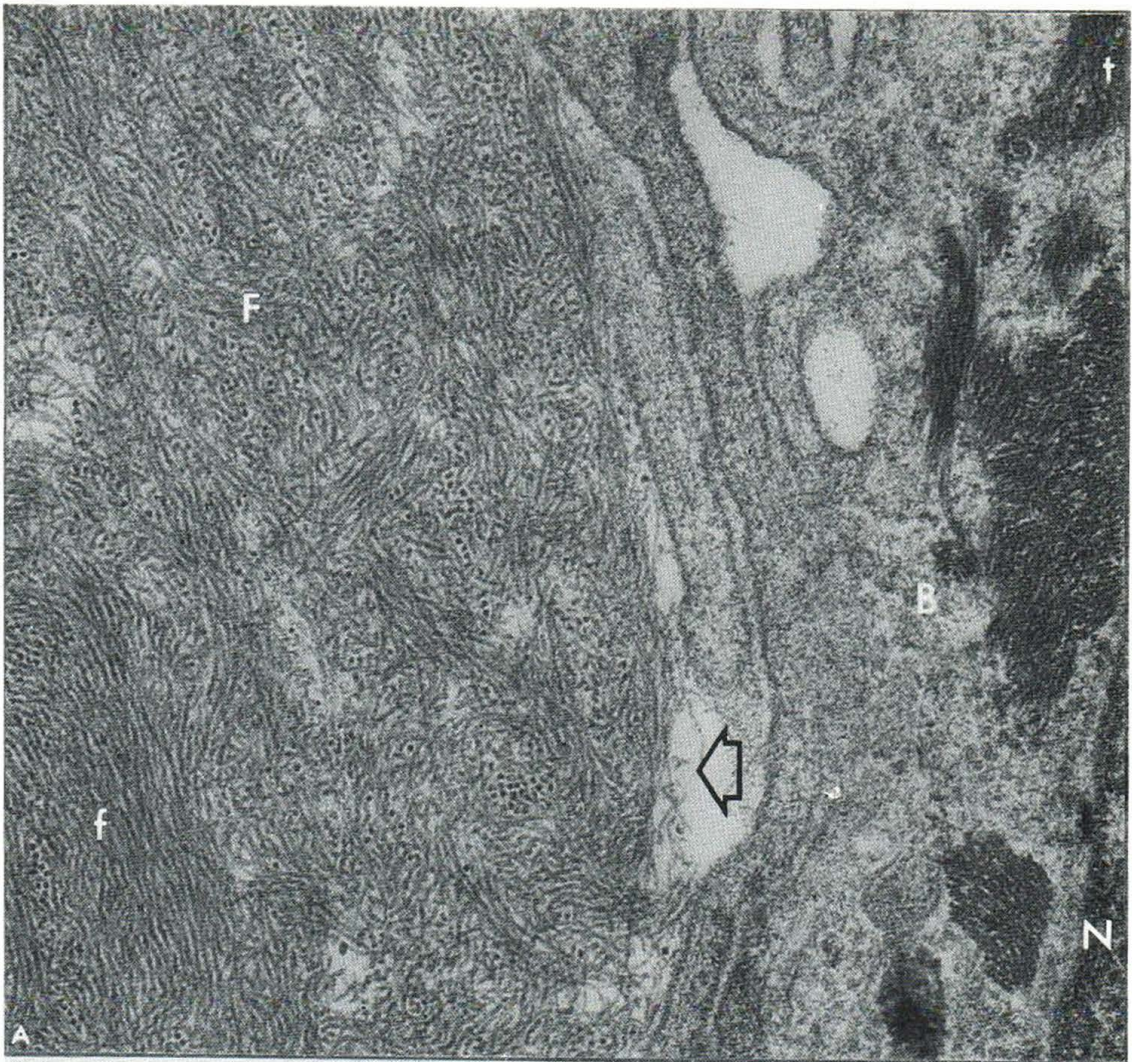
Keratinocyte origin of Civatte body. Civatte bodies identified in the thick sections were cells filled with fibers, to be called "filamentous cells" hereafter. In some of these cells undergoing "filamentous degeneration" pyknotic nuclei were still discerned, whereas in the majority no more than ghosts or fragmented debris of nuclei were recognized (Fig. 3). Other cellular organelles had likewise deteriorated and were either extruded or had disappeared within the cytoplasm (Fig. 3). The filamentous cells were shrunken and detached from the neighboring cells; desmosomes disappeared and intercellular spaces were widened (Fig. 3). The filamentous cells, therefore, appeared at low magnification like balls of clumped fibers of various densities (Figs. 3, 4). At higher magnification, clumped fibers were resolved into bundles of individual filaments. The thickness of individual filaments was approximately 60–80 Å and, therefore, slightly thicker than the normal tonofilaments, which measured approximately 40–60 Å. They were thinner than keratin filaments (100 Å). These filaments are shown in the same magnification in Fig. 5A, B. It is seen in Fig. 5A that the dimensions of filaments of a filamentous cell may not be significantly thicker than the tonofilaments in the

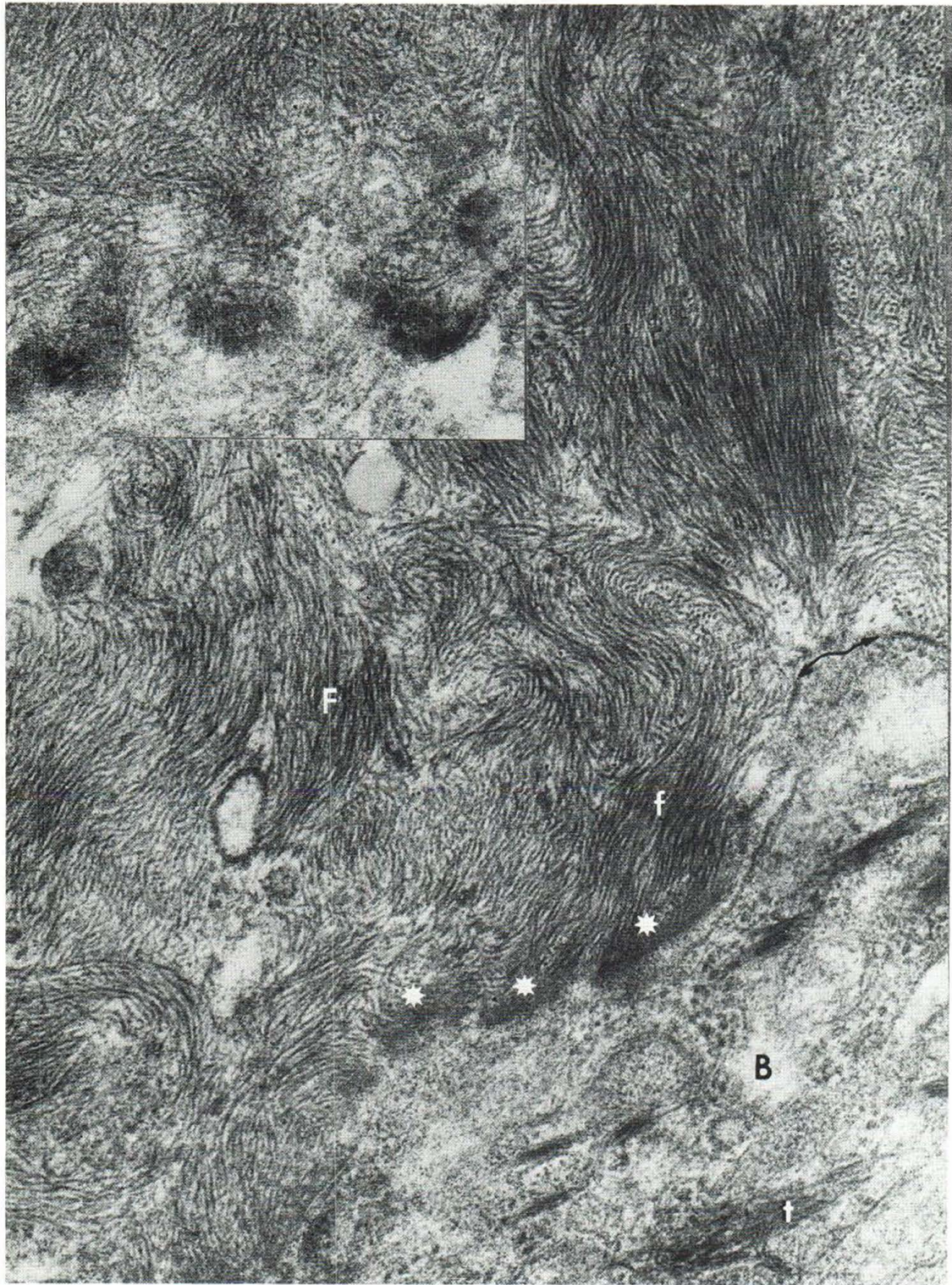adjacent keratinocyte, but individual filaments are more distinct because they are loosely aggregated. In this respect, these filaments are similar to keratin filaments (Fig. 5B). The variation of density of clumped fibers as seen in low magnification (Fig. 3) was due to the degree of aggregation of these filaments (Figs. 4, 5) and not to the variation of density in individual filaments. Heavily aggregated filaments in some cells were dense (Fig. 6). The evidence that these filaments are modified tonofilaments and that the Civatte bodies, namely the filamentous cells, represent filamentous degeneration of keratinocytes, came from the following observations: (i) Filaments of the filamentous cell bundled together and converged upon the attachment plaques of the desmosomes of their own cell (Fig. 6); (ii) although interruptedly, plasma membranes were seen along the periphery of some cells (Fig. 6); (iii) transitional forms existed between the normal basal cell and the filamentous cell (Figs. 7, 8); and (iv) phagocytosed melanosomes were seen in the filamentous cells (Fig. 9, also see Fig. 13D and Fig. 14B).

Fig. 5. (A) Lichen planus. Higher magnification of a filamentous cell (*F*) and adjacent normal basal cell (*B*) reveals that the filaments (*f*) of the filamentous cell are much more loosely aggregated and electron-lighter than the tonofilaments (*t*) of the basal cell. The diameters of these filaments may be slightly larger than those of tonofilaments. The cytomembrane of this cell has already been broken and individual filaments are extended into the inter-cellular space (*arrow*). *N*: nucleus of the basal cell. $\times 75\,000$. (B) Normal skin. Horny cells of the normal epidermis are surrounded with thickened cell envelope (the marginal band) (*m*) and contain keratin filaments (*f*) which measure approximately 100 Å in diameter. Compare these keratin filaments with filaments of the filamentous cell in (A). $\times 75\,000$.

Fig. 6. Lichen planus. This filamentous cell (*F*) is still partially enveloped by an intact cytomembrane (*arrow*). Desmosomes (*) are also preserved. Wavy bundles of filaments (*f*), 200 Å in diameter, converge upon the attachment plaques of these desmosomes. Compared with the tonofilaments (*t*) of the subjacent basal cell (*B*), the individual filaments (*f*) of the filamentous cell are more distinct and thicker. $\times 54\,000$. *Inset*: a similar example of the filament-desmosome complex found in other filamentous cells. $\times 75\,000$.

Fig. 7. Lichen planus. Two basal cells (*1*, *2*) are seen, one upon another. Cell no. 1 is a mature filamentous cell with its cytoplasm filled with loosely woven, whorled filaments, whereas cell no. 2 is a partially degenerated apoptotic cell with typical filament aggregation (*f*) in the center and a remnant of tonofilaments (*t*) at the periphery. Cell no. 2 is located above the basal lamina (*BL*) and connected to it with hemidesmosomes (*arrow*). $\times 60\,000$.





6

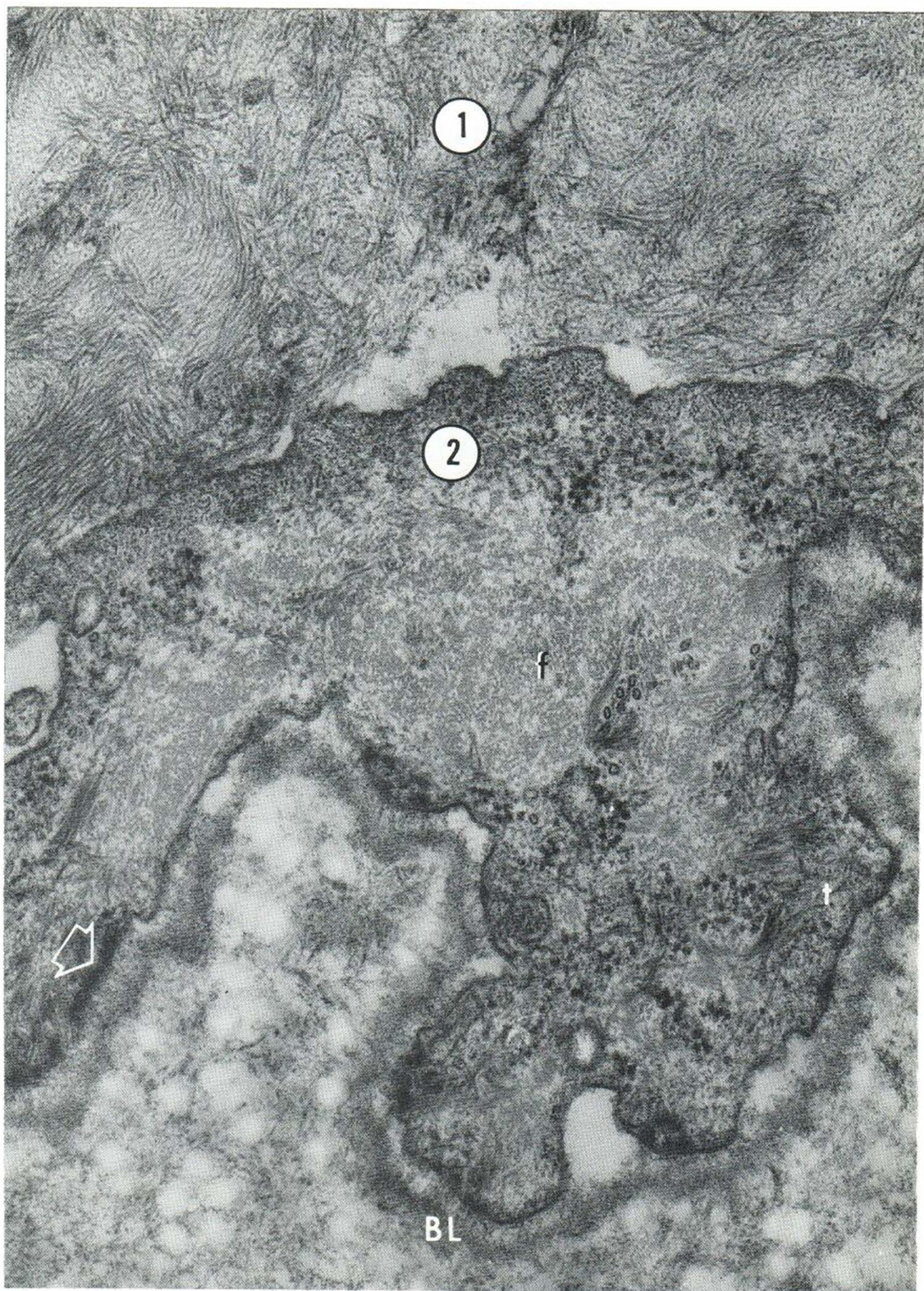

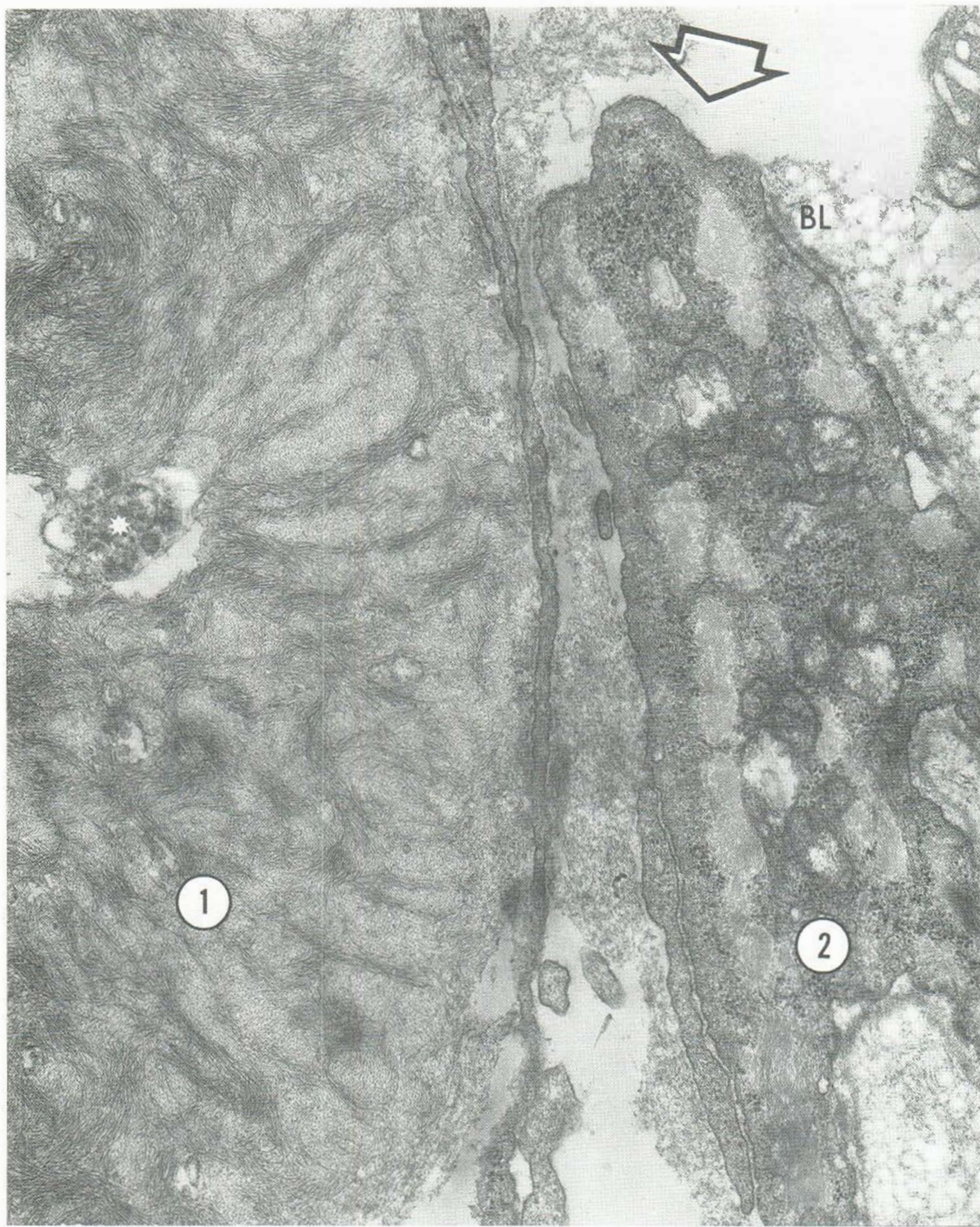


Fig. 8. Lichen planus. There are two filamentous cells (1, 2) in the basal layer. Cell no. 2 is only partially degenerated (cf. Fig. 7). Cell no. 2 is dropping into the upper dermis with the basal lamina (BL) attached. The basal lamina is dis-

rupted at the arrow. Amorphous or fine filamentous substance separates the space between cell no. 1 and cell no. 2. *: cellular debris of cell no. 1. $\times 26\ 700$.

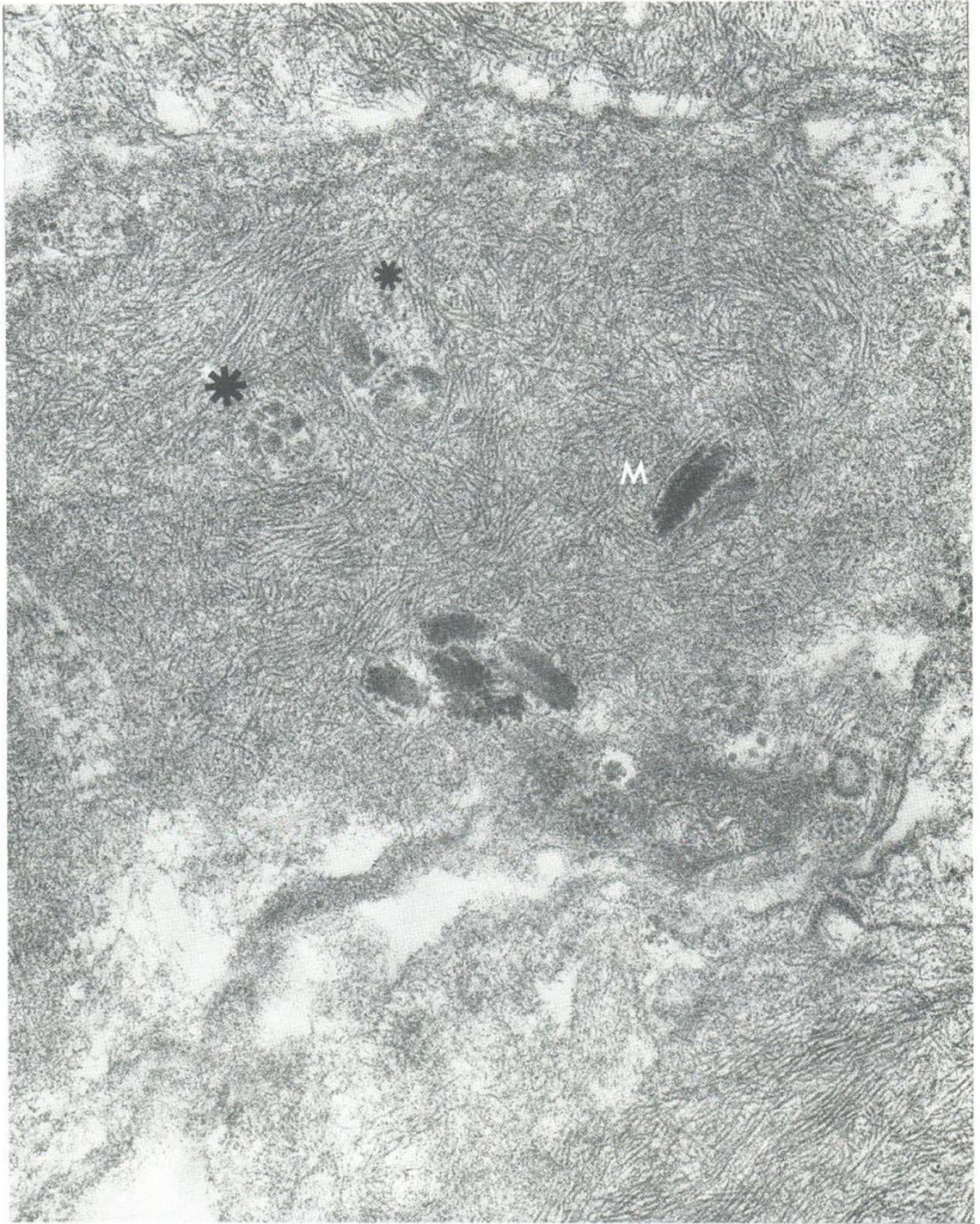


Fig. 9. Lichen planus. A melanosome-containing (M) filamentous cell is sandwiched between similar filamentous cells. Some melanosomes appear to have been partially

digested (*). See also Figs. 15 and 17 for other examples of melanosomes in a filamentous mass. $\times 55\,000$.

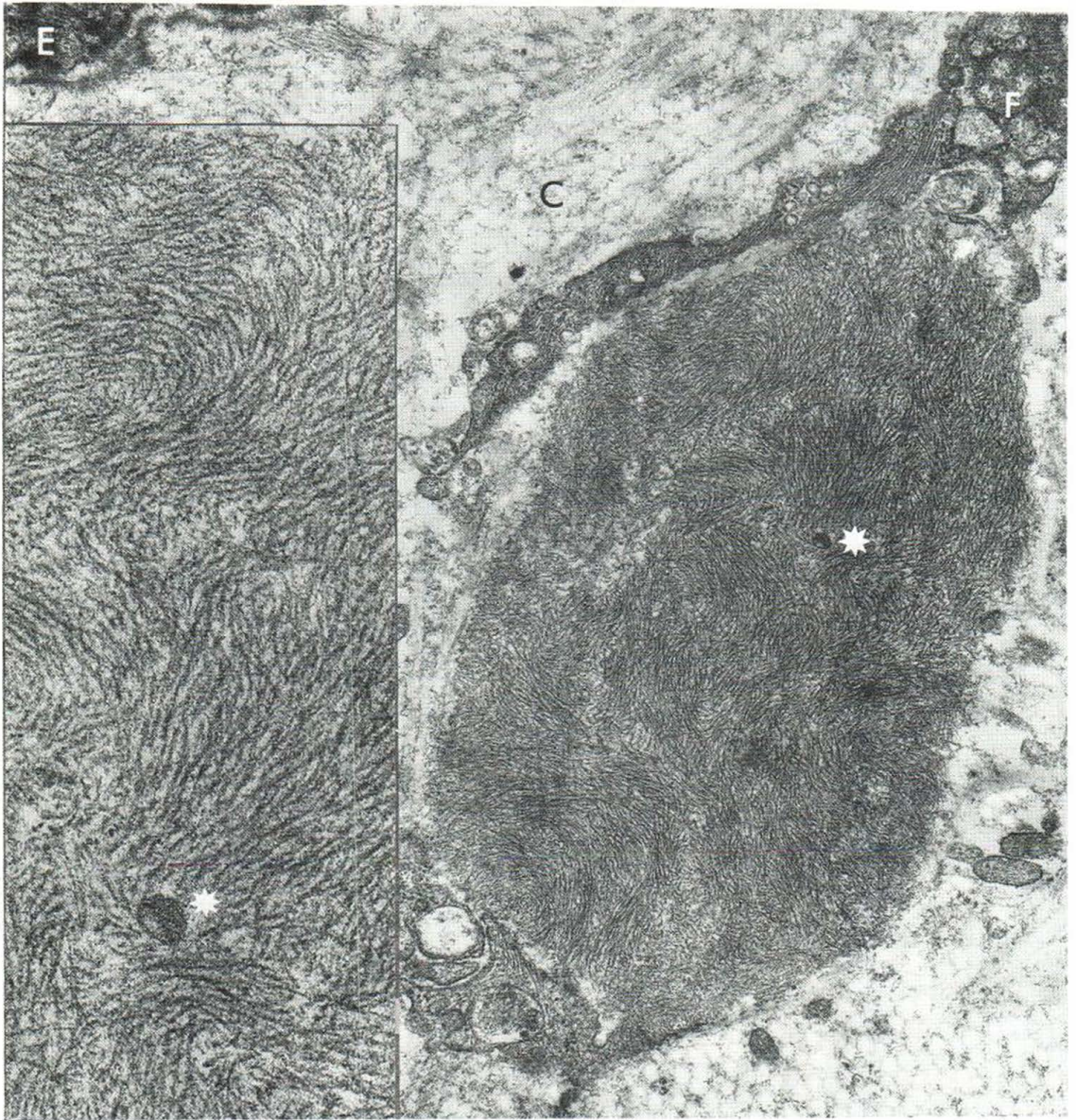


Fig. 10. Lichen planus. A subepidermally located filamentous mass contains the same type of filaments as those observed in the epidermal filamentous cell (cf. Figs. 5-9).

This mass is adjacent to cytoplasmic processes of a fibroblast (F). The center of this mass (*) is magnified in the inset. C: collagen E: epidermis. $\times 23\,350$. Inset, 70 000.

Dermal Civatte bodies. On many occasions the Civatte bodies were found in the upper dermis. These were revealed by electron microscopy to be "filamentous masses" (Fig. 10). As shown in Fig. 7, transitional forms between the normal basal cell and filamentous cells existed and occasionally these transitional cells were seen dropping off into the upper dermis (Fig. 8). In some macrophages in the

upper dermis filament aggregations identical to those of the Civatte body were found (Fig. 11). The dermal Civatte bodies were, therefore, of two types; (i) epidermal filamentous cells which dropped into the dermis, and (ii) phagocytes containing filament aggregations originating in the epidermal filamentous cells. Fibroblasts and other connective tissue cells were examined carefully but

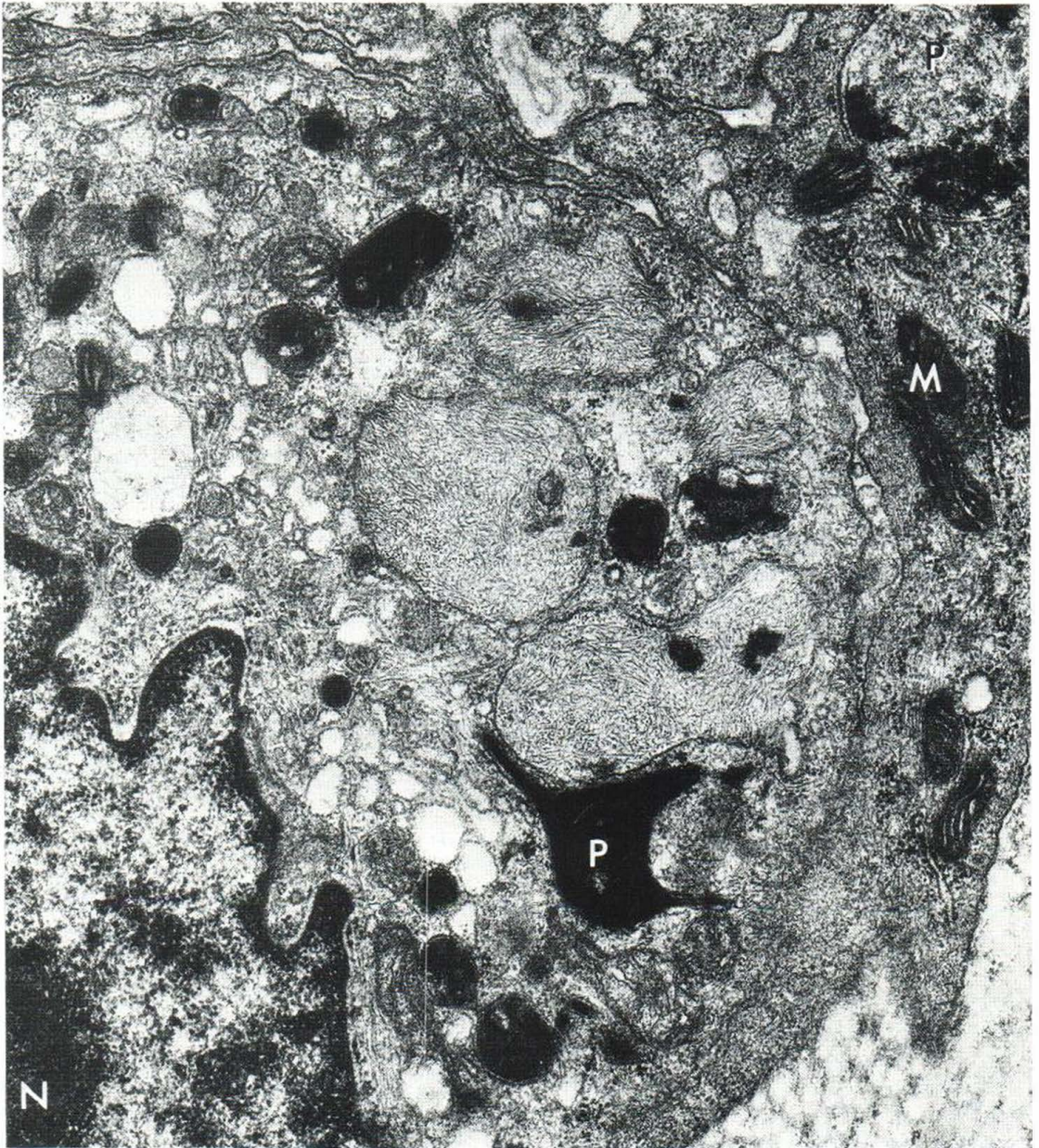

Fig. 11. Lichen planus. A subepidermal phagocyte contains small masses of filamentous substance similar to

that of the filamentous mass. *M*: mitochondria. *N*: nucleus, *P*: phagosome, $\times 28\,000$.

there was no ultrastructural evidence that these cells were producing Civatte bodies, although in some cells cytoplasmic microfilaments were increased in number. Phagocytes, histiocytes, lymphocytes and fibroblasts infiltrated the epidermis by breaking through the basal lamina (Fig. 12 A, B). In many instances, the cytoplasmic processes of fibro-

blasts extended between the intra-epidermal filamentous cells and embraced them (Fig. 12 B).

Comparative studies. Filamentous degeneration of the keratinocytes and the production of filamentous masses or Civatte bodies identical with those of lichen planus were observed in lichenoid, macular and myeloma-associated amyloidoses (Fig.




Fig. 12 A. Lichen planus. A histiocyte (*H*) is migrating into the epidermis, breaking the basal lamina (*BL*) at the arrows. *B*: basal cell. $\times 15000$.

13 A, B, C). In lichen and macular amyloidoses, some filaments were straight and stiff and measured 60–100 Å (Fig. 13 A). These were therefore similar to amyloid filaments found in the dermis of the same specimen (Fig. 13 B). In the palmar and plantar pits of the nevoid basal cell epithelioma syndrome (Fig. 14 A, B), in the lesions of balloon cell nevus (Figs. 15 A, B, and 16), squamous cell carcinoma grade III (Fig. 17) and discoid LE, the identical fibrous bodies were found in both the lower epidermis and the upper dermis.

Peroxidase-injected guinea pig skin contained a number of keratinocytes which were undergoing filamentous degeneration (Fig. 18). Such cells often contained a number of peroxidase-positive phagosomes, vacuoles, degenerating nuclei and residual tonofilaments alongside the typical whorled filaments of the filamentous cell (Fig. 18). Langerhans cell granules contained peroxidase (18) but did not show filamentous degeneration. The control animal's skin did not have any filamentous cells.

DISCUSSION

Civatte thought that the bodies he described were of epidermal, lympho-reticular or connective tissue cell origin (23, 32). Even before Civatte studied them, other authors (9, 29) had described the same "colloid" bodies in lichen planus. Goltz & Hult (10) described the presence of a large amount of glycoprotein in these bodies and thought that this represented a secretion or degeneration product. They concluded that the Civatte bodies were derivatives of either epithelial or inflammatory cells. The Civatte bodies in oral lichen planus were studied ultrastructurally by El-Labban (8) and El-Labban & Kramer (7) who thought that the Civatte bodies originate from keratinizing epithelial cells by abnormal mitosis. They thought (8) that these masses were subsequently engulfed by cells containing pre-melanosomes and melanosomes. Degenerated mast cells were also thought to contribute to the formation of eosinophilic masses.

In the present investigation, it was clearly shown

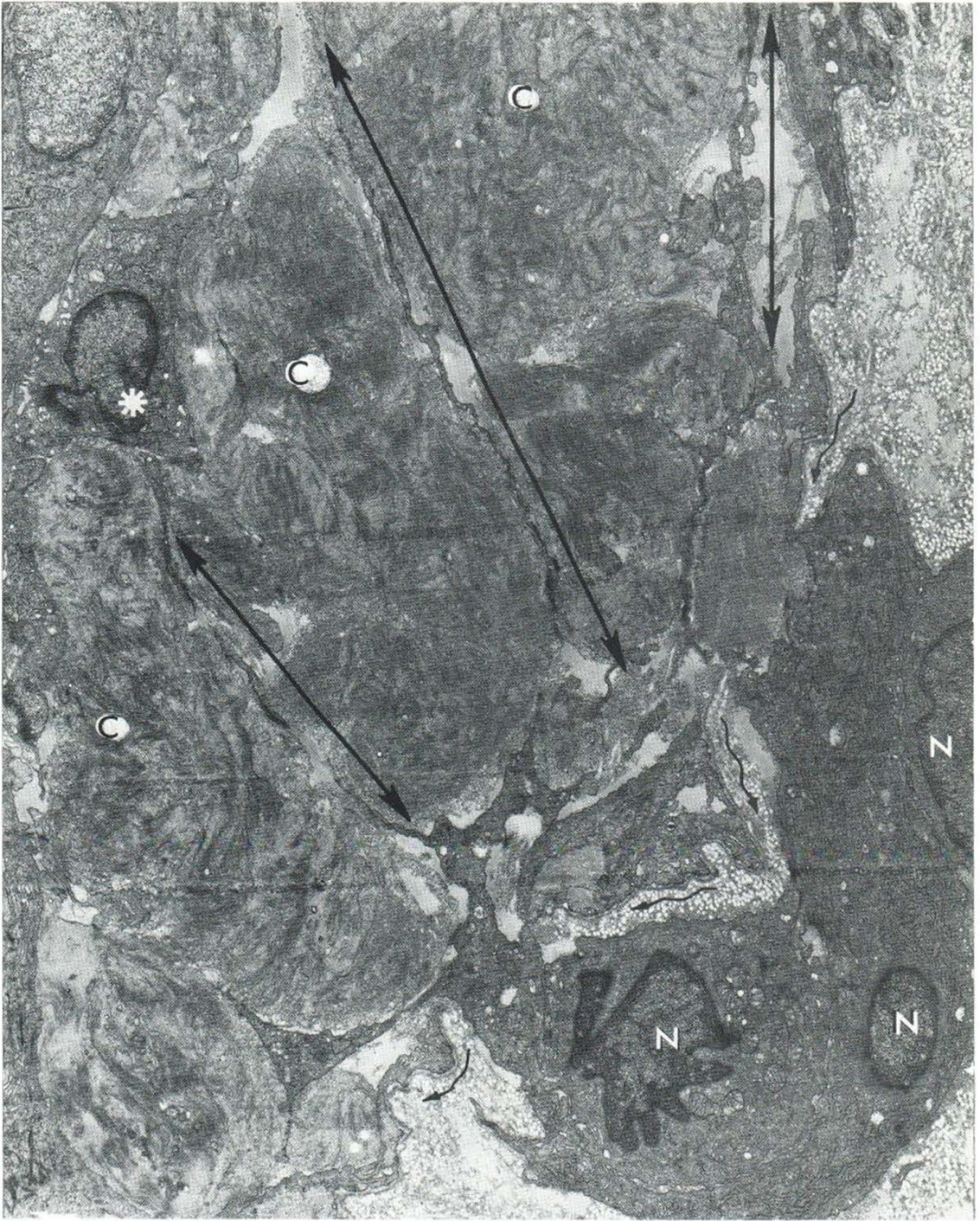

Fig. 12 B. Lichen planus. A fibroblast, whose nucleus (*N*) is located beneath the basal lamina (*curved arrows*), extends a number of cytoplasmic processes into the epider-

mis. These dendritic processes (*straight arrows*) surround individual Civatte bodies, i.e. filamentous cells (*C*). Another fibroblast (***) is seen in the epidermis. $\times 8000$.

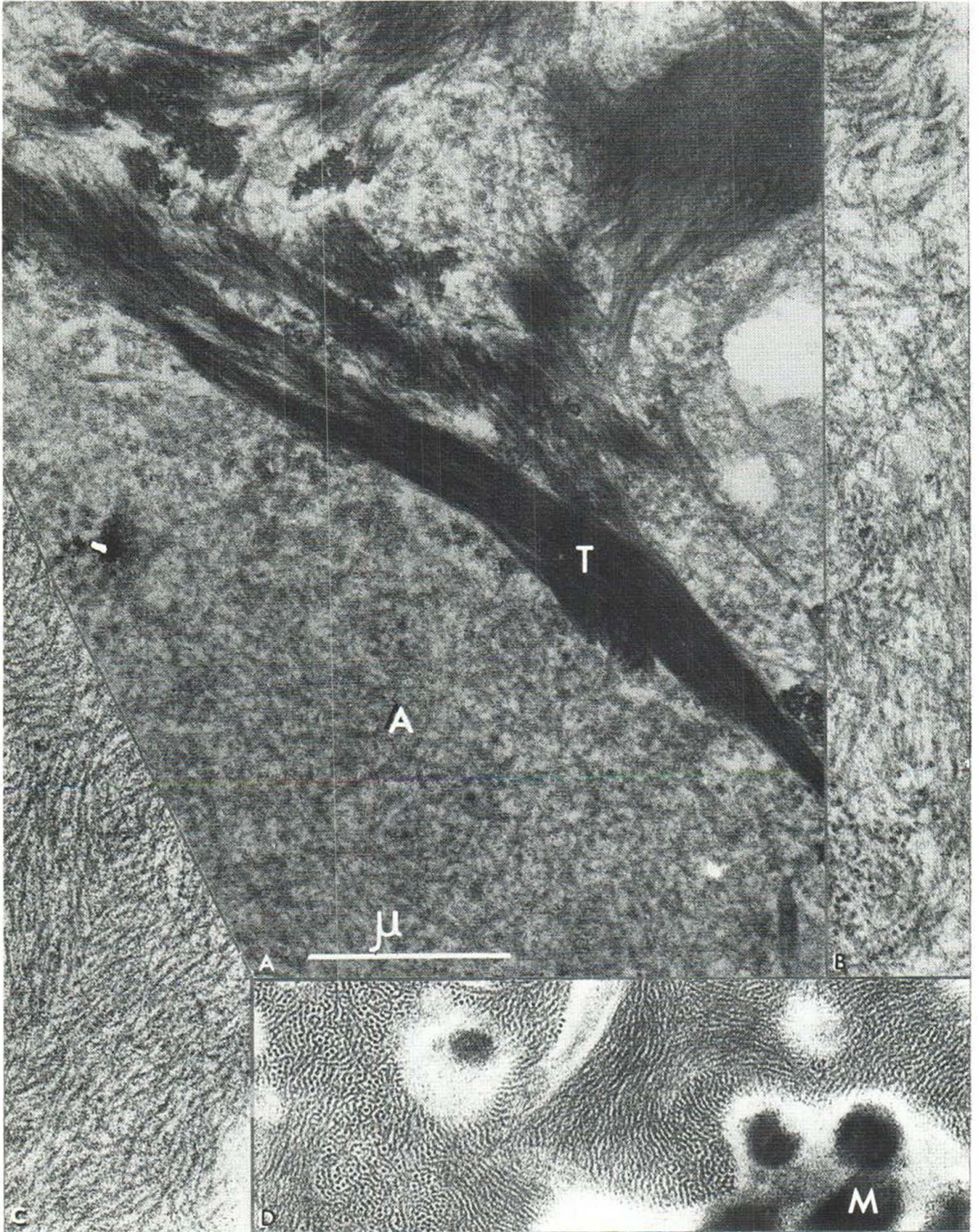
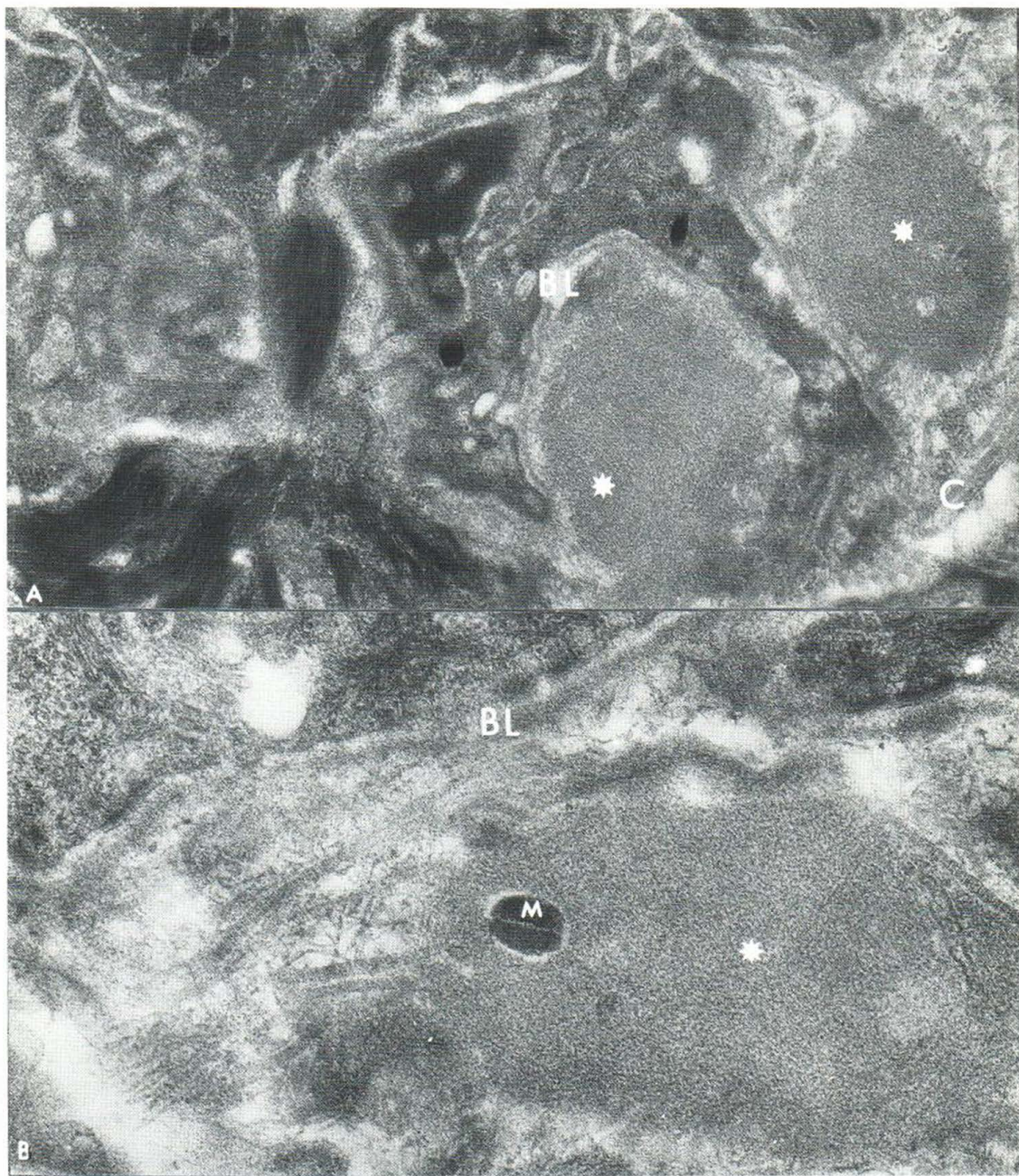


Fig. 13. Lichen amyloidosis. In (A), amyloid-like filaments (A) are surrounded by tonofilaments (T) in a keratinocyte of the epidermis that covered the amyloid deposits in the upper dermis. These filaments are similar in their dimensions (60–100 Å) and their straight, stiff ap-

pearance to the true amyloid filaments in (B). Filamentous aggregations found in other cells (C, D) are identical to those seen in the filamentous cells, or Civatte bodies, of lichen planus (cf. Fig. 10, inset). M: melanosomes. All pictures: $\times 75\,000$.

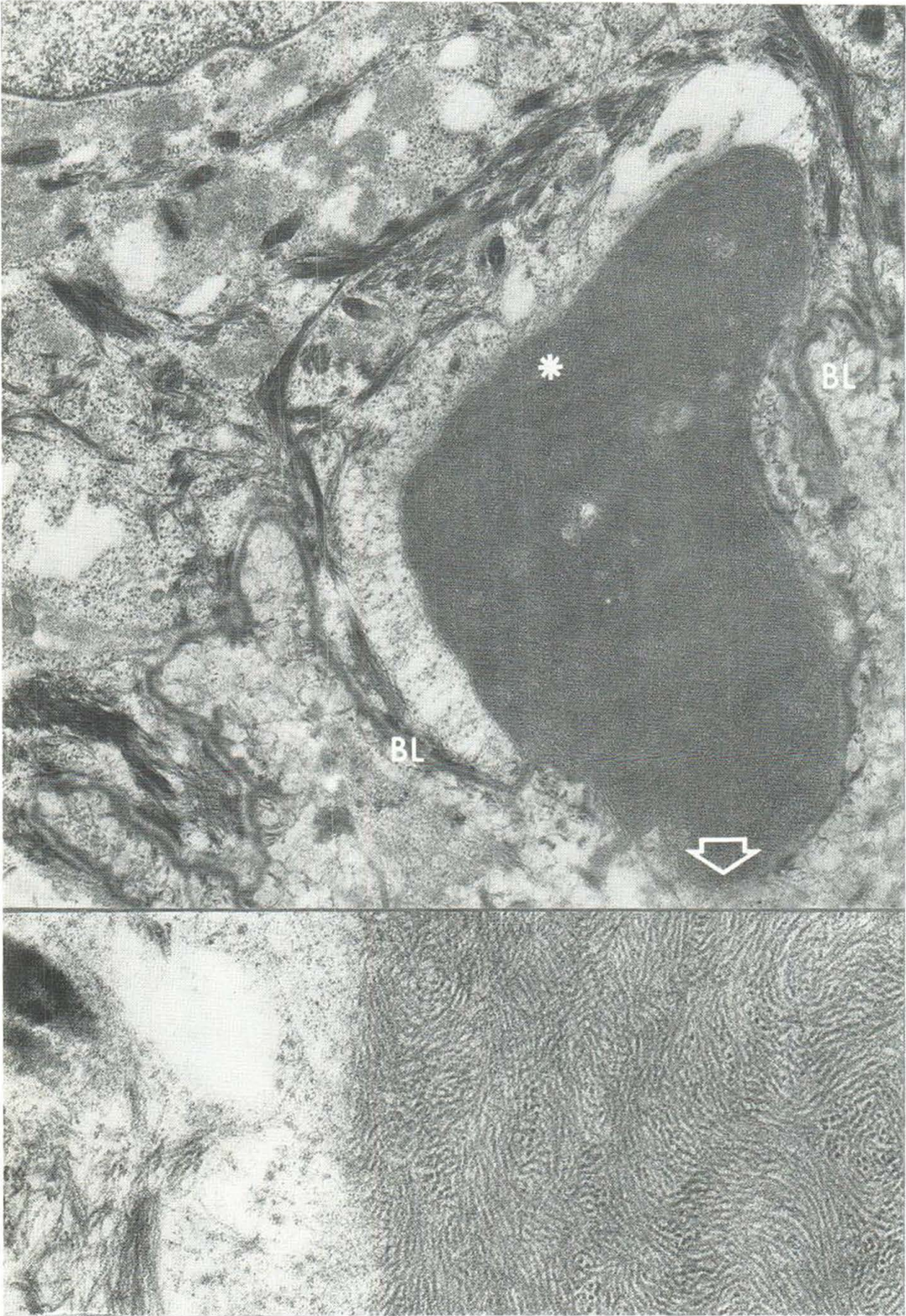

Figs. 14. (A, B) Nevus BCE, the base of a palmar pit. In (A) two filamentous masses are seen below the epidermal basal lamina (BL). In (B) a melanosome-containing (M)

filamentous mass () is located just beneath the basal lamina (BL). C: collagen, (A) $\times 28\,000$, (B) $\times 45\,250$.*

that the major source of the Civatte body is the keratinocytes; this finding supports the finding of El-Labban (8). Ebner & Gebhard (5) have recently published data similar to mine; they described the epidermal origin of Civatte bodies in lichen planus

and lichen amyloidosis. They also demonstrated that there is a distinct ultrastructural difference between Civatte bodies and amyloid. In the present investigation, component filaments constituting these filamentous aggregates were approximately



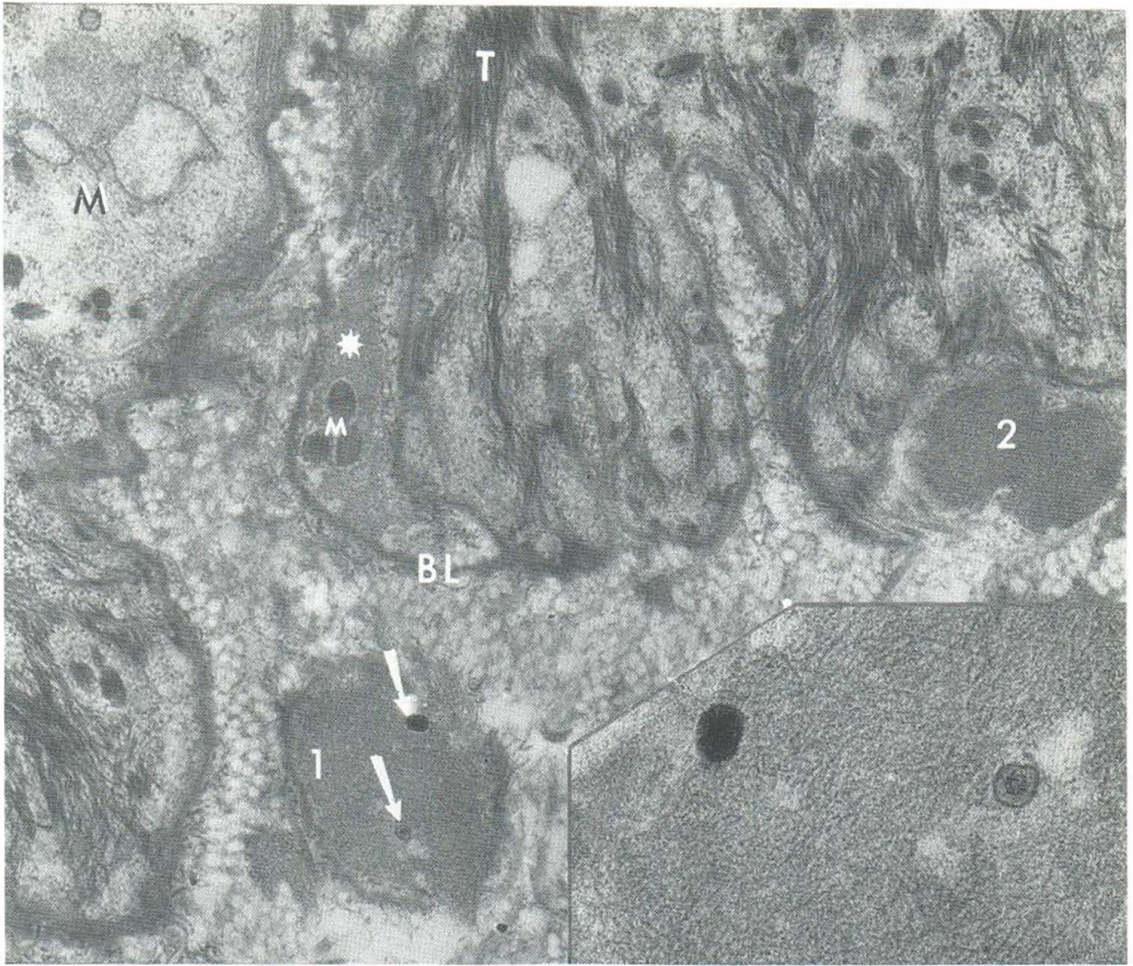


Fig. 16. Balloon cell nevus. A basal cell containing melanosomes (*m*) shows a partial filamentous transformation (*). There are two filamentous masses (1, 2) in the upper dermis. Mass no. 1 contains two melanosomes (ar-

rows) which are enlarged in the inset. *BL*: thickened basal lamina, *M*: melanocyte undergoing ballooning degeneration, *T*: tonofilaments, $\times 23\,800$. Inset: $\times 71\,300$.

60–80 Å in diameter and, therefore, slightly thicker than tonofilaments, but thinner than keratin filaments. They were much less electron-dense than keratin filaments. These filaments may represent a premature transformation of tonofilaments into keratin filaments without sufficient protein synthesis

to provide the thickness and electron-density of mature keratin.

Civatte bodies could be produced experimentally in the guinea pig by injecting foreign protein, i.e. peroxidase. Unlike Langerhans cells which are phagocytes (18), the epidermal keratinocytes were damaged by phagocytosed peroxidase and underwent filamentous degeneration. An early stage of Civatte bodies, which still retains a shadow of nucleus and residual tonofilaments, could be demonstrated within 22 hours after the injection of horse-radish peroxidase.

At the ultrastructural level, Civatte bodies should be called "filamentous cells" as long as such bodies

Fig. 15. Balloon cell nevus. In the lesion a basal cell (*B*) contains a filamentous mass (*). This mass may be formed within this cell or phagocytosed. The lower end of this mass (arrow) is partially dropping into the upper dermis by breaking the basal lamina (*BL*). The lower picture is an enlargement of the area marked by * in the upper picture. Upper: $\times 24\,200$. Lower: $\times 89\,500$.

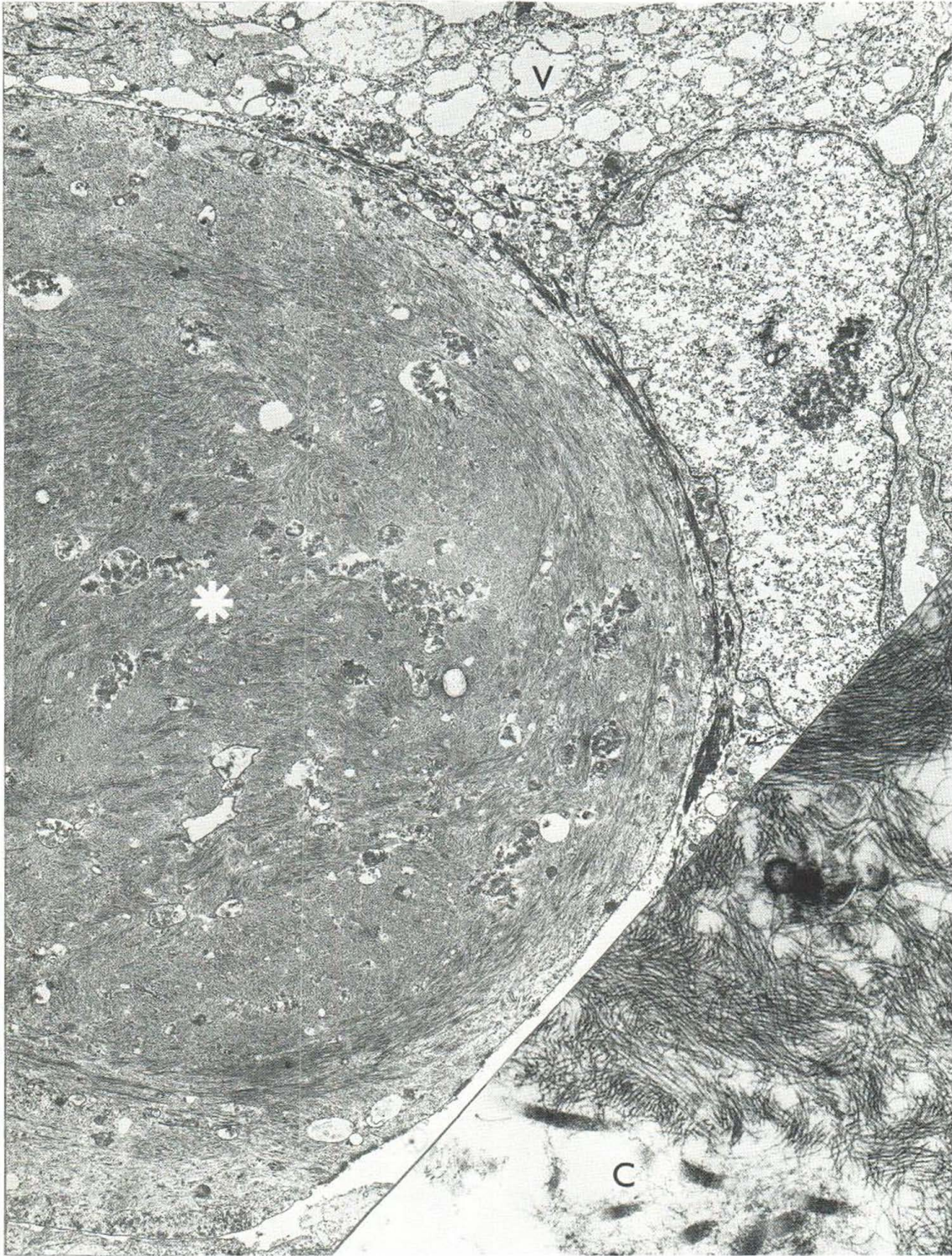


Fig. 17. Squamous cell carcinoma grade III. Among vacuolated (V) tumor cells a typical filamentous cell (*) is seen. This cell still contains a number of degenerated organelles

and vacuoles. *Inset:* filamentous mass found in the upper dermis. C: collagen, $\times 7\ 150$, *Inset:* $\times 40\ 300$.

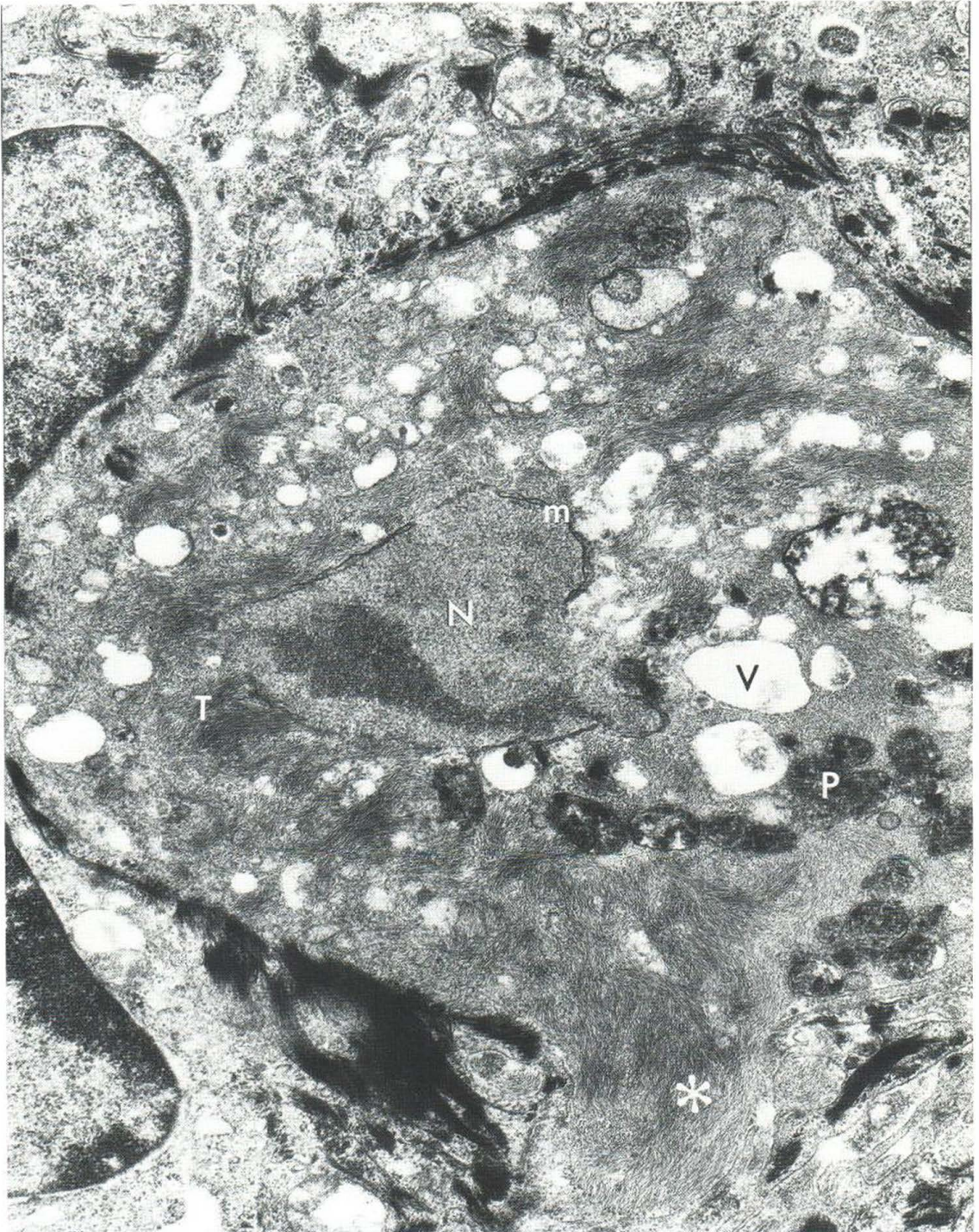

Fig. 18. Peroxidase-injected guinea pig epidermis. Biopsy taken 22 hours after the injection revealed a number of cells of this type. Nucleoplasm (*N*) and nuclear membranes (*m*) are still recognizable. Numerous vacuoles (*V*) and de-

generating organelles are interspersed with partially normal (*T*) and partially fibrous (***) filaments typical of Civatte bodies (cf. Figs. 4, 17). Numerous phagosomes (*P*) contain peroxidase. $\times 19\,500$.

are surrounded by the cytomembrane, and at a later stage as "filamentous masses" when further degradation breaks the cytomembrane and releases the contents. Such filamentous masses may be found in phagocytes. The presence of melanin in these cells or masses can be explained by the filamentous transformation of melanin-containing keratinocytes into filamentous cells. As cited above, many light microscopists including Civatte himself (4) thought that one source of this body was connective tissue cells. It is now apparent that the majority of such dermal Civatte bodies are dropped-off filamentous cells or phagocytosed filamentous masses, although some connective tissue cells might become filamentous cells.

Abnormal aggregations of tonofilaments which are detached from desmosomes have been described in many conditions affecting the epidermis (1, 31, 34, 35). In most of these works, individual tonofilaments appear to be normal in dimensions and density and only the abnormal aggregation is striking. Most of the abnormal tonofilament aggregations described in oral lichen planus by El-Labban (8) and El-Labban & Kramer (7) are of this type and are different from those individually distinct and electron-light filaments reported in the present study. It is believed that Civatte bodies studied by these investigators (7, 8) are either peculiar to the mucous epithelium, where there is usually less filament formation than in the epidermal keratinocytes, or these bodies were at an early stage of formation during differentiation and maturation.

The basal keratinocytes are death-bound; they die purposefully at their highest achievement of differentiation, i.e. keratinization. Do filamentous cells represent a premature keratinization of the basal or lower level Malpighian cell? Unlike normally keratinizing epidermal cells, they produce neither the marginal band (19) nor the cementsome (20). No keratohyalin granules are produced. Filaments in these cells are thinner than keratin filaments. On the other hand, filamentous cells share, in common with keratinized cells, a lack of nucleus and other organelles. Is filamentous degeneration a special form of cell death, or do all premature deaths of keratinocytes take this form? Many vacuolated cells in squamous cell carcinoma were not filamentous cells (Fig. 17). Even in lichen planus, some basal cells could be vacuolated (hydropic) and simply disintegrate (21). In pemphigus vulgaris, acantholytic cells may be like filamentous cells and contain clumped ton-

filaments (34) or be almost entirely vacuolated (22). These observations may allow a conclusion that the filamentous cells are a special type of prematurely dying cells which attained as much differentiation (keratinization) as possible.

The ultrastructure of the epidermal apoptotic cells could be varied. The filamentous cells which Weedon (32) considered to be apoptotic cells are not identical with those illustrated in the present study. All stages of apoptotic degeneration were, however, observed in experimentally induced filamentous cells (Fig. 18). Civatte bodies described by El-Labban (8) and El-Labban & Kramer (7) resemble more closely the apoptotic cells of Kerr et al. (23); I believe that these cells represent an immature stage of filamentous cells.

Keratinocytes with pyknotic, clumped tonofilaments have long been recognized as dyskeratotic cells or "individual cell keratinization" in actinic keratosis, pemphigus vulgaris, Darier's disease (1), ultraviolet-irradiated skin (35), Bowen's disease (31) and others (24, 33). The concept of apoptosis is, however, significant and useful in unifying similar phenomena in various tissues and conditions. In hyperplastic conditions such as actinic keratosis, the balance between mitosis and apoptosis may be important in determining whether it remains benign or progresses into a malignant tumor. Self-cure of some cancers could be explained by apoptotic elimination of malignant cells. Similarly, inability of most of the palmar and plantar pit epithelia of nevoid BCE to grow into a full-blown tumor, in spite of an inherent potentially to do so (14), may be explained by this balance. In inflammatory conditions such as lichen planus, lichenoid and macular amyloidoses and discoid LE, the epidermis may not be able to regulate its own reproductive rate (which is probably determined by mitotic stimuli (25) and destructive noxa of the basic disease processes). However, the epidermis may be able to control the cell population by apoptosis. It is significant that most of the dyskeratosis, namely apoptosis, is observed in hyperplastic conditions or the hyperplastic stage of the disease: Thus, hyperplastic inflammatory conditions such as lichen planus, discoid LE, lichenoid and macular amyloidoses and skin tumors could be typical conditions in which apoptosis regulates the tissue growth.

Pierce and his associates (26) demonstrated in well-differentiated transplantable squamous cell carcinoma of rats that differentiated tumor cells

(non-keratinized horn pearl cells) cannot be transplanted to reproduce the tumor. It is likely that once a malignant stem cell is differentiated fully, it loses oncogenicity. Since filamentous cells described above in various hyperplastic conditions are differentiated cells, i.e. prematurely keratinized cells, they are considered to be drop-outs from the proliferative race among many competitive cells or cell lines. The cure of cancer, for example, may be achieved by elucidating the factors involved in differentiation of immature tumor cells, or by inventing methods to modulate differentiation of tumor stem cells (27).

Whether or not amyloid-like filaments in the keratinocytes of lichen amyloidoses (Fig. 13 A) (2, 3, 6, 12) are variants of apoptotic filamentous degeneration is not yet decided. It is obvious that the following factors influence the characteristics of epidermal apoptotic cells: (i) the stage of maturation at which the degeneration begins; (ii) the degree of cellular damage by the basic disease processes (such as lethal, sublethal and necrobiotic); and (iii) whether or not phagocytosed by other cells. Amyloid-like filaments shown in Fig. 13 are indeed like true amyloid filaments and may represent one of the variants of the apoptotic cell product.

The real significance of apoptosis in the skin diseases should be explored by an extensive survey of the conditions in which they might occur. It seems clear that apoptosis plays a central role in tumor regression, therapeutic involution of the lesion, embryonic organization of tissues, and wound repair (23). In lichen planus, intra-epidermal death of keratinocytes by filamentous degeneration is a prominent feature. Some non-epidermal cells which infiltrated into the epidermo-dermal junction are obviously attracted by the dead cells, i.e. Civatte bodies, and were apparently trying to engulf or exclude Civatte bodies (Fig. 12 A, B).

ACKNOWLEDGEMENTS

This work has been supported by the research projects no. 3499-01 and no. 3499-02 and a Medical Investigatorship Award of the Veterans Administration.

REFERENCES

1. Arai, K.: A comparative electron microscopic study of acantholysis and dyskeratosis in Darier's disease and familial benign chronic pemphigus. *Jap J Der, Series A*, 81: 943, 1971.
2. Black, M. M. & Jones, E. W.: Macular amyloidosis: A study of 21 cases with special reference to the role of the epidermis in its histogenesis. *Br J Dermatol* 84: 199, 1971.
3. Brownstein, M. & Hashimoto, K.: Macular amyloidosis. *Arch Dermatol* 106: 50, 1972.
4. Civatte, A.: Atlas d'histopathologie cutanée. pp. 166-167. Masson et Cie, Paris, 1957.
5. Ebner, H. & Gebhard, W.: Light and electron microscopic differentiation of amyloid and colloid or hyaline bodies. *Brit J Dermatol* 92: 637, 1975.
6. Ebner, H.: Licht- und elektronenmikroskopische Untersuchungen über das Amyloid der Haut. *Z Hautkr* 43: 833, 1968.
7. El-Labban, N. G. & Kramer, I. R. H.: Civatte bodies and the actively dividing epithelial cells in oral lichen planus. *Br J Dermatol* 90: 13, 1974.
8. El-Labban, N. G.: Light and electron microscopic studies of colloid bodies in lichen planus. *J Periodont Res* 5: 315, 1970.
9. Gans, D.: Histologie der Hautkrankheit. Springer, Berlin, 1925.
10. Goltz, R. W. & Holt, A.: Histochemische Natur der Kolloidkörper beim Lichen ruber planus. *Hautarzt* 14: 355, 1963.
11. Gougerot, H. & Civatte, A.: Critères cliniques et histologiques des lichen planus et muqueux: délimitation. *Ann Derm Syph* 80: 5, 1953.
12. Hashimoto, K. & Onn, L. L. Y.: Lichen amyloidosis. *Arch Dermatol* 104: 648, 1971.
13. Hashimoto, K.: Skin function and amyloidosis: An ultra-structural study. *In* Amyloidosis (ed. J. Waldenström & O. Wegelius), (in press). Academic Press, New York, 1975.
14. Hashimoto, K., Howell, J. B., Yamanishi, Y., Holubar, K. & Bernhardt Jr, R.: Electron microscopic studies of palmar and plantar pits of nevoid basal cell epithelioma. *J Invest Dermatol* 59: 380, 1972.
15. Hashimoto, K. & Bale, G. F.: An electron microscopic study of balloon cell nevus. *Cancer* 30: 530, 1972.
16. Hashimoto, K. & King Jr, L. E.: Secondary localized cutaneous amyloidosis associated with actinic keratosis. *J Invest Dermatol* 61: 293, 1973.
17. Hashimoto, K., Yamanishi, Y., Maeyens, E., Dabous, M. & Kanzaki, T.: Collagenolytic activities of squamous cell carcinoma of the skin. *Cancer Res* 33: 2790, 1973.
18. Hashimoto, K.: Langerhans' cell granule. An endocytotic organelle. *Arch Dermatol* 104: 148, 1971.
19. — The marginal band. A demonstration of the thickened cellular envelope of the human nail cell with the aid of lanthanum staining. *Arch Dermatol* 103: 387, 1971.
20. — Cementsome, a new interpretation of the membrane-coating granule. *Arch Derm Forsch* 240: 349, 1971.
21. Hashimoto, K., Dibella, R. J., Shklar, G. & Lever, W. F.: Electron microscopic studies of oral lichen planus. *Gior Ital di Derm* 107: 767, 1966.
22. Hashimoto, K. & Lever, W. F.: An electron microscopic study on pemphigus vulgaris of the mouth and the skin with special reference to the intercellular cement. *J Invest Dermatol* 48: 540, 1967.

23. Kerr, J. F. R., Wyllie, A. H. & Currie, A. R.: Apoptosis: A basic biological phenomenon with wide ranging implications in tissue kinetics. *Br J Cancer* 26: 239, 1972.
24. McNulty, J. R. & Sommers, S. C.: Keratoacanthoma as a surgical pathologic entity. *Surg Gynecol Obstet* 104: 663, 1957.
25. Marks, R., Black, M. & Jones, E.: Epidermal cell kinetics in lichen planus. *Br J Dermatol* 88: 37, 1973.
26. Pierce, G. B. & Wallace, C.: Differentiation of malignant to benign cells. *Cancer Res* 31: 127, 1971.
27. Pierce, G. B. & Johnson, L. D.: Differentiation and Cancer. *In Vitro* 7: 140, 1971.
28. Reynolds, E. S.: The use of lead citrate at high pH as an electron opaque stain in electron microscopy. *J Cell Biol* 17: 208, 1963.
29. Sabouraud, R.: Quelques points d'anatomie pathologique du lichen plan de Wilson. *Ann Derm Syph* 1: 491, 1910.
30. Schneeberger-Keeley, E. E. & Karnowsky, M. J.: The ultrastructural basis of alveolar-capillary membrane permeability to peroxidase used as a tracer. *J Cell Biol* 37: 781, 1968.
31. Seiji, M. & Mizuno, F.: Electron microscopic study of Bowen's disease. *Arch Dermatol* 99: 3, 1969.
32. Weedon, D.: Civatte bodies and apoptosis. *Br J Dermatol* 91: 357, 1974.
33. Weedon, D. & Barnet, L.: Keratoacanthoma centrifugum marginatum. *Arch Dermatol* 111: 1024, 1975.
34. Wilgram, G. E., Caulfield, J. B. & Lever, W. F.: An electron microscopic study of acantholysis in pemphigus vulgaris. *J Invest Dermatol* 36: 373, 1961.
35. Wilgram, G. E., Kid, R. L., Krawczyk, W. S. & Cole, P. L.: Sunburn effect on keratinosomes. A report with special note on ultraviolet-induced dyskeratosis. *Arch Dermatol* 101: 505, 1970.

Received September 1, 1975

K. Hashimoto, M.D.
V A Hospital
1030 Jefferson Avenue
Memphis, Tennessee 38104
USA