

DOUBLE-BLIND TRIAL OF MICONAZOLE IN DERMATOMYCOSIS

Else Svejgaard

From the Department of Dermatology, University of Copenhagen, Rigshospitalet, Copenhagen, Denmark

Abstract. A double-blind study of miconazole (Brentan®) has been performed in 86 patients suffering from dermatomycosis. Of the 65 patients not lost to follow-up, 30 had received the active drug, and 35 placebo. The cure-rate was significantly ($p=0.03$) higher in patients receiving miconazole (70%) than in those on placebo (40%). The higher cure-rate was found in patients suffering from cutaneous candidiasis and tinea versicolor, as well as from dermatophytosis, but was significant only in the latter group, which was the largest.

Miconazole, an imidazole derivate (Fig. 1), has been found to have broad spectrum activity in vitro against pathogenic fungi, a number of saprophytic fungi and gram-positive bacteria (4, 5). The most sensitive pathogens were found to be dermatophytes, yeasts, dimorphous fungi, aspergilli and mycetoma-causing fungi. The drug has been tested on guinea pigs, both orally and topically, against known effective drugs such as griseofulvin, tolnaftate, nystatin, amphotericin B and pimelicin, which has established its effectiveness (4). In man, the drug has been administered topically in dermatophytosis and vulvo-vaginitis caused by *Candida albicans* and has been found to be highly effective and well tolerated (1, 2, 3, 6, 7).

In this paper the clinical effect in a double-blind study of miconazole (Brentan®) for topical treatment against skin infections caused by dermatophytes, *Malassezia furfur* and *Candida albicans* is reported.

MATERIALS AND METHODS

The study comprised 86 out-patients with clinical signs of dermatomycosis. Of the 86 patients 21 were excluded as they were lost to follow-up. Nine of these 21 were treated with the active drug, 12 with placebo. The number of available patients was thus 65, 30 on active drug, 35

on placebo. The age of the patients ranged from 5 months to 70 years with an average of 28 years. The duration of their dermatomycoses ranged from 1 week to more than 10 years with an average of 5 months. The diagnosis was confirmed by mycological examination.

None of the patients had received griseofulvin within 4 weeks prior to the trial, or topical treatment during the last 24 hours.

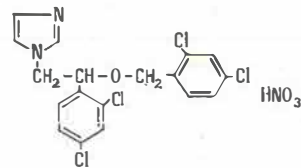
A clinical evaluation was performed before treatment according to the following principles:

1. Small area affected and/or lesions showing erythema, slight infiltration and slight desquamation.
2. Larger area affected and/or erythema, infiltration, desquamation, vesicles and pustules present.
3. Large area affected, and/or erythema, infiltration, desquamation, vesicles, pustules and maceration present.

All the lesions were assessed mycologically first by microscopy of lesion scrapings, cleared by 30% potassium hydroxide, and examined after 15-30 minutes for hyphae and spores. In addition, cultures were set up with the scrapings from the patients with dermatophytosis and cutaneous candidiasis. The former were inoculated on Petri dishes with Sabouraud dextrose agar plus penicillin, streptomycin and actidione, the latter on Sabouraud dextrose agar plus penicillin and streptomycin. The dishes with the material from dermatophytosis were inoculated at 28°C for 1 month and examined weekly. The material from candidiasis was examined after 3 days, and if yeast cultures were present they were transferred to corneal agar for further isolation.

MICONAZOLE

Structural formula:



Empirical formula: $C_{18}H_{14}Cl_4N_2O \cdot HNO_3$ Molecular weight: 479.16
Melting point ~ : 180°C

Chemical formula: 1-[2,4-dichloro-β-(2,4-dichlorobenzoyloxy) phenethyl]imidazole nitrate.

Fig. 1

Table I. Effect of treatment in relation to severity of lesions

Lesions	Active drug		Placebo		Total
	Cured	Not cured	Cured	Not cured	
1. Slight	4	1	8	3	16
2. Moderate	11	3	6	13	33
3. Severe	6	5	0	5	16
Total	21	9	14	21	65

The mycological examination was performed prior to and regularly during treatment. The results of the mycological control together with the clinical appearance were the criteria for the effect of the treatment. "Cure" was defined as negative microscopy and culture and complete disappearance of the clinical affection, while all other patients were considered "not cured".

Miconazole nitrate was used as a 2% cream.

Composition of miconazole nitrate: topical cream 2%

Miconazole nitrate (R 14889)

Tefose 63

Labrafil M 1944 CS

Mineral oil, USP XVII p. 399

Perfume No. 4074

Butylated hydroxyanisole, BP 1968 p. 135

Purified water, USP XVII p. 754

Tefose 63 is an emulsifying agent consisting of a mixture of mono- and distearic esters of ethylene glycol and polyoxyethylene glycols. Labrafil M 1944 CS is an emulsifying agent consisting of polyethylenic oleic glycerides. Perfume No. 4074 is a powdered flavour. (Specifications of raw materials are obtainable from the company.)

The placebo was the vehicle of the cream without miconazole nitrate. The active drug and the placebo were indistinguishable and supplied in identical tubes with consecutive code numbers. The contents of the individual

Table II. Effect of treatment in relation to clinical diagnosis

	Active drug		Placebo		Total
	Cured	Not cured	Cured	Not cured	
Dermatophytosis					
<i>Tinea capitis</i>	2	0	1	0	3
<i>Tinea cruris</i>	2	1	1	4	8
<i>Tinea manuum</i>	1	0	1	0	2
<i>Tinea pedum</i>	4	3	3	6	16
<i>Tinea corporis</i>	4	1	1	3	9
<i>Candidiasis cut.</i>	3	2	1	1	7
<i>Tinea versicolor</i>	5	2	6	7	20
Total	21	9	14	21	65

Acta Dermatovenere (Stockholm) 53

Table III. Effect of treatment in relation to result of mycological examination

	Active drug		Placebo		Total
	Cured	Not cured	Cured	Not cured	
<i>Microsporum canis</i>	2	1	1	3	7
<i>Trichophyton mentagrophytes</i>	1	1	2	2	6
<i>Trichophyton rubrum</i>	3	2	0	6	11
<i>Epidermophyton floccosum</i>	3	1	2	0	6
Dermatophyte (neg. culture)	4	0	2	2	8
<i>Candida albicans</i>	3	2	0	1	6
Yeast (neg. culture)	0	0	1	0	1
<i>Malassezia furfur</i>	5	2	6	7	20
Total	21	9	14	21	65

tubes were unknown to the author until the code was broken.

The cream was used twice daily in small quantities and rubbed into the lesions. Daily washing was permitted. No other topical or systemic medication was used throughout the trial.

The patients were seen regularly at 1, 2 or 3 week intervals, when they were examined clinically and mycologically. The treatment was discontinued if the lesions showed no impairment after 2 weeks, on the occurrence of complications, or at cure.

The effect of the treatment and the exclusion of cases were evaluated before the codes were broken.

The chi-square test with Yates correction was used for comparing the results.

RESULTS

All except one of the microscopies before treatment were positive. Of the pathogens isolated on Petri dishes, 11 were *Trichophyton rubrum*, 7 *Trichophyton mentagrophytes*, 6 *Epidermophyton floccosum*, 6 *Microsporum canis* and 6 *Candida albicans*. Nine patients showed negative cultures.

The effect of the treatment in relation to the severity of the affection, the clinical diagnosis and the mycological examination, are shown in Tables I, II and III.

It appears that for the combined material, there is a higher frequency of cured patients in those receiving the active drug than in those on placebo. This difference is significant at the 3% probability level. For dermatophytoses alone the

difference was significant at the 5% probability level. The differences in the other two groups did not reach significance, although there was a tendency to a higher cure rate in patients receiving the active drug.

Five patients with severe moist and macerated lesions showed aggravation of the affection, which caused discontinuation of the treatment after 3–10 days. Two of these patients were treated with placebo, 3 with the active drug. Three of them suffered from tinea pedis (*Trichophyton rubrum*) and 2 from severe candidiasis.

The duration of the treatment depended primarily on the results of the mycological examination. For the patients cured on the active drug, it lasted 4.2 weeks, on average.

COMMENTS

This double-blind study confirms the observation of Botter, Brugsman, van Cutsem and Thienpont (1, 2, 3, 4) that miconazole is an active drug for treatment of dermatophytoses. In addition, our findings indicated that it is useful in the treatment of cutaneous candidiasis and in tinea versicolor, although further studies are needed to establish these findings. In particular, the results for tinea versicolor were encouraging because previous treatments were often disagreeable and none-too-effective.

The rather high incidence of cure in the placebo was remarkable. However, 6 of these patients suffered from tinea versicolor, which is a superficial dermatomycosis. It is worth noting that the cases cured on placebo had a higher frequency of relapse than the cases on active drug (2). Furthermore, no patient with severe lesions was cured on placebo (Table I).

Most of the 9 patients resistant to the active drug had severe lesions. Four of them were taken out of treatment after 3–10 days because of

aggravation or unsatisfactory results. The remaining 5 showing clinical improvement continuously had positive mycology. Two suffered from tinea versicolor, and one of these admitted that he had not followed treatment schedule regularly. Three suffered from dermatophytoses.

ACKNOWLEDGEMENTS

My thanks are due to Miss Norma Båstrup and Mrs Kirsten Jørgensen for skilful technical assistance.

The tubes of miconazole and the vehicle for this trial were provided by Janssen Pharmaceutica, Beerse, Belgium.

REFERENCES

1. Botter, A. A.: Topical treatment of nail and skin infections with miconazole, a new broad-spectrum antimycotic. *Mykosen* 14 (4): 187, 1970.
2. Brugsman, J., van Cutsem, J. & Thienpont, D. C.: Treatment of longterm tinea pedis with miconazole. *Arch Derm (Chicago)* 102: 428, 1970.
3. Brugsman, J. & van Cutsem, J.: Three-stage clinical evaluation of etonam (R 10100) in the treatment of chronic athletes foot. *Dermatologica* 138: 403, 1969.
4. van Cutsem, J. & Thienpont, D. C.: Miconazole, a broad-spectrum antimycotic agent with antibacterial activity. *Chemotherapy* 17: 392, 1972.
5. Godefroi, E. F., Heeres, J., van Cutsem, J. & Janssen, P. A. J.: The preparation and antimycotic properties of derivatives of 1-phenylimidazole. *J Med Chem* 12: 784, 1969.
6. Godts, P., Vermeyren, P. & van Cutsem, J.: Clinical evaluation of miconazole nitrate in the treatment of vaginal candidiasis. *Arzneimittelforschung* 21: 256, 1971.
7. Thiery, M., Mrozowsky, P. J. & van Kets, H.: Miconazole, a new broad-spectrum antimycotic, in the treatment of vaginal candidosis. *Mykosen* 15 (1): 35, 1972.

Received February 15, 1973

E. Svejgaard, M.D.
Department of Dermatology
Rigshospital
Blegdamsvej 9
DK-2100 Copenhagen Ø
Denmark