

ULTRASTRUCTURE OF GENERALIZED SCLERODERMA

Takasi Kobayasi and Gustav Asboe-Hansen

From the University of Copenhagen Department of Dermatology, Rigshospital, Copenhagen, Denmark

Abstract. Fourteen cases of generalized scleroderma were studied by electron microscopy of ultrathin skin sections. Elastic fibres showed degeneration, appearing as granular material, holes and loss of elastic fibrils. Extraordinarily numerous distinct parallel elastic fibrils were noticed in the deep corium. The granular material contained glycoprotein. In the dermo-epidermal junction, the basal lamina appeared irregularly thickened with altered anchoring fibrils, anchoring filaments and few elastic fibril anchorings. Collagen bundles held three different types of collagen fibrils: 1) Uniformly distributed, 700 Å thick fibrils with a round cut surface. 2) Thin and thick collagen fibrils (about 200 Å and 900 Å in diameter). These fibrils appeared in clusters in various parts of the bundle. 3) Compact bundles of about 1000 Å thick fibrils with a polygonal cut surface. The axial banding of all kinds of collagen fibrils was periodic at a distance of about 550 Å. No twisting figures were found.

Cystic endoplasmic reticulum and partial thickening of the cell membrane of fibroblasts were seen. Around fibroblasts and vessels, fine parallel filaments with repeated dense bands were seen. They may represent fibrogenesis. Mast cells contained mainly mature granules but numerous villi suggest previous degranulation. Between collagen fibrils and altered elastic fibres, considerable amounts of threads with knobs and lattice-like filaments were located. They represent acid glycosaminoglycans.

Electron microscopic studies on dermal changes in scleroderma are few in the recent literature. Porous figures and peripheral destruction of elastic fibers and collagen fibrils about 800 Å thick showing a periodicity of about 600 Å were reported by Bahr (2). Rupec & Braun-Falco (18) demonstrated collagen fibrils thinner than 500 Å in scleroderma, especially in the circumscribed type. Holzmann et al. (7) found thickening of the basal lamina of vessels, nerves and epidermis. Histochemical studies by various authors demonstrated Alcian blue stained, metachromatic material in the interfibrillar space of scleroderma in the edematous phase (1, 3, 8, 20). Biochemical

studies showed an increased content of collagen-bound hexosamines but no increase of acid and neutral glycosaminoglycans in the sclerodermic corium (6).

To obtain further details of ultrastructural changes in the sclerodermic corium, the present study of ultrathin sections was undertaken.

MATERIAL AND METHOD

Fourteen patients with generalized scleroderma of the acrosclerosis type, aged 12 to 77, were studied. Biopsies were taken from the involved, sclerotic skin of arm and trunk. The specimens were fixed in 6% glutaraldehyde in Veronal acetate buffer (pH 7.2) with 7.5% sucrose at 4°C. After osmification, the specimens were dehydrated in a series of alcohols of increasing strength, and embedded in Epon 812. Ultrathin sections were stained with uranyl acetate and lead citrate and studied with an electron microscope (Siemens Elmiskop 1A). Some sections were stained using the periodic acid-silver proteinate technique after Théry (19, 21) and by Ruthenium red (14).

OBSERVATIONS

The ultrastructural changes of the connective tissue in the deep corium were generally more pronounced than those in the upper corium. In the deep corium, a fine granular material was seen coating the surface of broad elastic fibres and occurring in strips inside the fibres (Fig. 1). Occasionally, the granular material of the strips appeared denser than that coating the fibre surface. The homogeneous elastic matrix was often seen as narrow bands separated by granular material and holes. The granular material contained fine threads with knobs and scarce, indistinct elastic fibrils (Fig. 1). No round dense bodies or

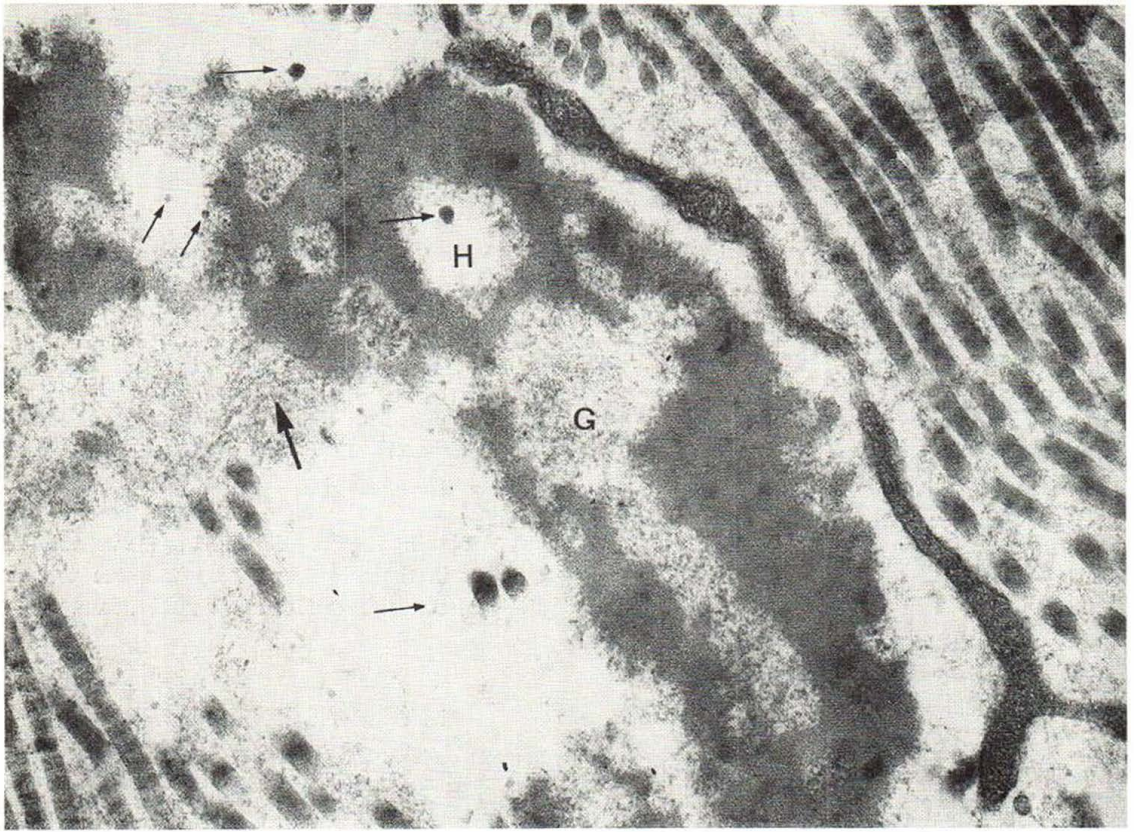


Fig. 1. An elastic fibre of deep corium shows holes (H) and granular material (G). The holes were partly filled up by granular material. A thick arrow indicates indistinct

elastic fibrils and thin arrows threads with knobs around fibres and inside holes. Collagen fibrils are uniformly thick. $\times 46\ 000$.

myelin figures as in sun-exposed and senile skin, were found. Threads with knobs appeared distinctly in the spaces together with a little granular material (Fig. 1). The knobs were stained with Ruthenium red which stains acid glycosaminoglycans (14) (Fig. 2 b). The granular material gave a slightly positive reaction by PAS staining for electron microscopy (Fig. 2 a). Coexisting with the above-described figures, two patients had elastic fibres consisting of distinct fine networks with few and faint elastic fibrils and pieces of homogeneous matrix (Fig. 3). Two other patients had overwhelming amounts of granular material in the broad elastic fibres and complete lack of elastic fibrils. Two of the fourteen cases studied showed none of the mentioned changes, only scarce granular material, distinct elastic fibrils and considerable amounts of threads with knobs around the fibres. Beside the changed elastic

fibrils seen in the deep corium, half of the examined cases showed distinct parallel elastic fibrils intermingling with disperse bundles of thin collagen fibrils (Fig. 4) or between compact collagen bundles and the changed elastic fibres. In the upper corium, elastic fibrils were seen close to the basal lamina, but elastic fibril anchorings were rarely seen (Fig. 5). The basal lamina was approximately 300 to 500 Å and showed irregular thickness in some places. In the case of thick basal lamina, distinct anchoring fibrils were seen on the dermal side, and in addition distinct anchoring filaments to the half-desmosome. Occasionally anchoring fibrils appeared disarranged (Fig. 5). The anchoring fibrils and filaments in the thinner basal lamina were indistinct.

The collagen bundles appeared extraordinarily thick in the deep corium. Most were uniformly made up of about 700 Å thick collagen fibrils

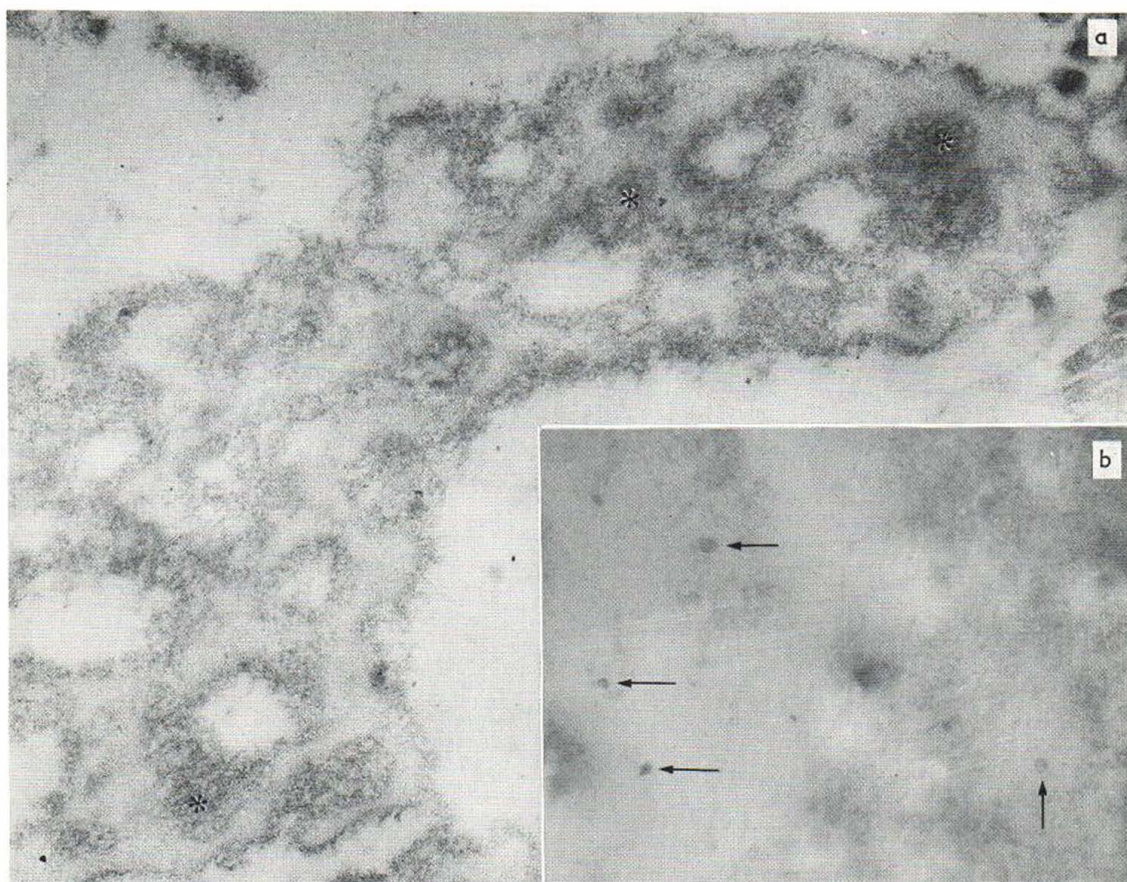


Fig. 2 *a* and *b*. In Fig. 2 *a*, granular material inside an elastic fibre gives a positive reaction by the periodic acid silver proteinate technique (*). In Fig. 2 *b* the knobs are

stained with Ruthenium red indicating acid glycosaminoglycans. $\times 48\,000$.

with a round cut surface and an axial periodicity of about 550 \AA (Fig. 1). No twisting was observed. Such large bundles often included the above-described changed elastic fibres. Other bundles consisted of thick collagen fibrils ranging from 200 to 900 \AA in diameter. Such different types were found in clusters at multiple locations within one bundle (Fig. 6). All fibrils were characterized by round cut surfaces and an axial periodicity of about 550 \AA . Thin collagen fibrils were often found in the vicinity of fibroblasts (Fig. 7). Lattice-like filaments were seen in considerable numbers between neighbouring collagen fibrils (Fig. 6). The third type of collagen bundle showed extremely dense packing of thick fibrils which were about $1\,000\text{ \AA}$ in diameter, showing a polygonal cut surface and an axial periodicity of

about 550 \AA (Fig. 10). The fibril bundles were densely packed and also lay close to the elastic fibres. Threads with knobs and lattice-like filaments were rare between these fibrils and the elastic fibres. In areas surrounding fibroblasts and vessels, sparse bundles of very fine filaments were seen (Fig. 7). These filaments were parallel to the neighbouring collagen fibrils. Their diameter was less than 20 \AA , and they were seen to continue in collagen fibrils of about 300 \AA in thickness. Repeating dense bands could be seen in such bundles. The widths and the intervals of the dense bands were about 300 \AA (Fig. 7 and inset).

The collagen fibrils in the upper dermis were about 600 \AA thick without great variations, and with an axial periodicity of about 550 \AA . No twisting phenomena were seen. Many lattice-like

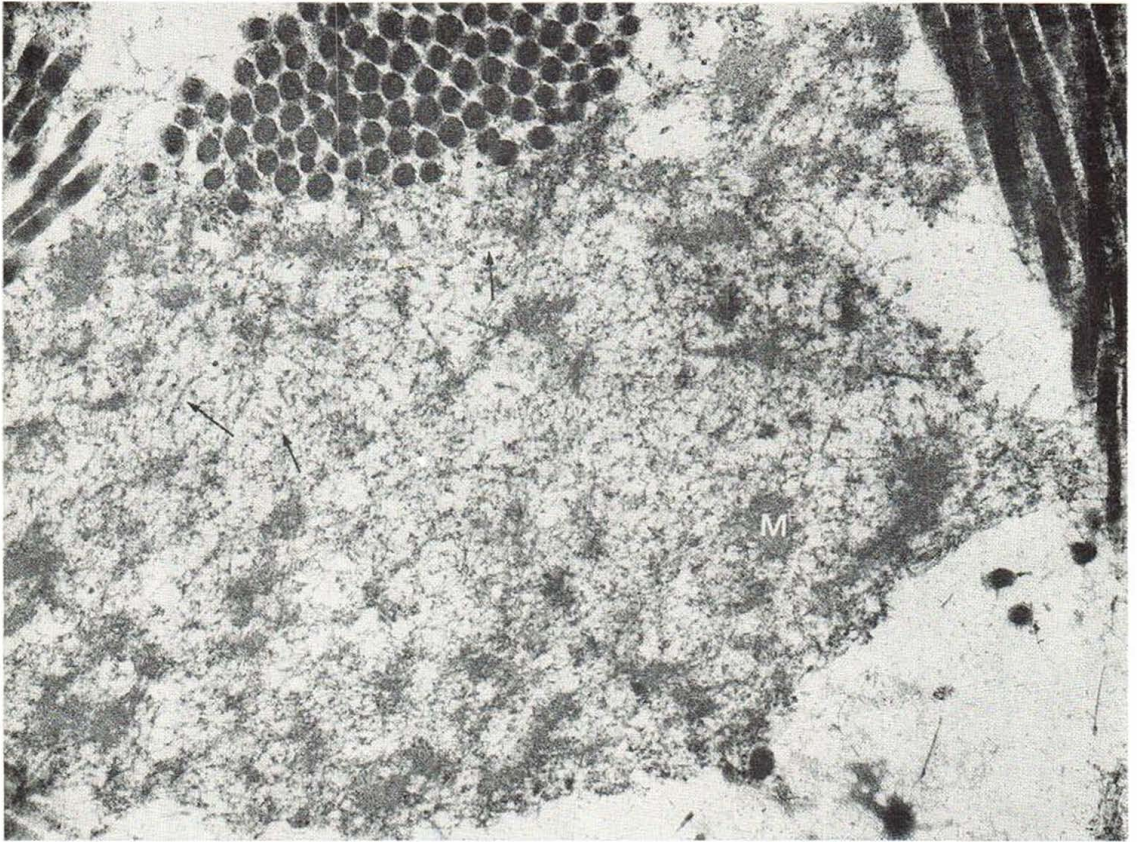


Fig. 3. Elastic fibre of deep corium showing fine networks and pieces of the homogeneous matrix (M). Arrows indicate indistinct elastic fibrils. $\times 46\ 000$.

filaments covered the collagen fibrils, while threads with knobs were found in the spaces between the collagen fibrils (Fig. 5). The dermal vessels showed a thickened basal lamina, often in indistinct multiple layers.

Macrophages were seen to engulf pathological elastic fibres (Fig. 11) and collagen fibrils (Fig. 12). The fibroblasts repeatedly showed a cystic endoplasmic reticulum and partial thickening of the cell-membrane (Fig. 8). Several mast cells were found in the dermis. Their granules were mainly mature, but a few were disintegrating (10). Numerous microvilli protruded from their surface. In the mast cells of one tissue specimen, all intracytoplasmic granules were grainy with fragments of scrolls and indistinct granule-boundaries (Fig. 9), while no extracellular granules and occasional short villi were seen.

DISCUSSION

Degenerated elastic fibres have been described in senile and light-exposed skin as well as in pseudoxanthoma elasticum (4, 5). The pathological findings, i.e. granular material, holes, lack of elastic fibrils, were identical with those found in this study. However, in most scleroderma patients, the changes in the deep corium were more evident than in normal skin of the same age. No myelin figures were found, which is in contrast to pseudoxanthoma elasticum and senile elastosis. Neither could calcium deposits be seen in scleroderma. It cannot be excluded, however, that the dense strips in the elastic fibres may represent minimum calcium precipitation. Parallel arranged, distinct elastic fibrils are rare in the normal deep corium (11). Those found in scleroderma are probably young and newly formed (17). The

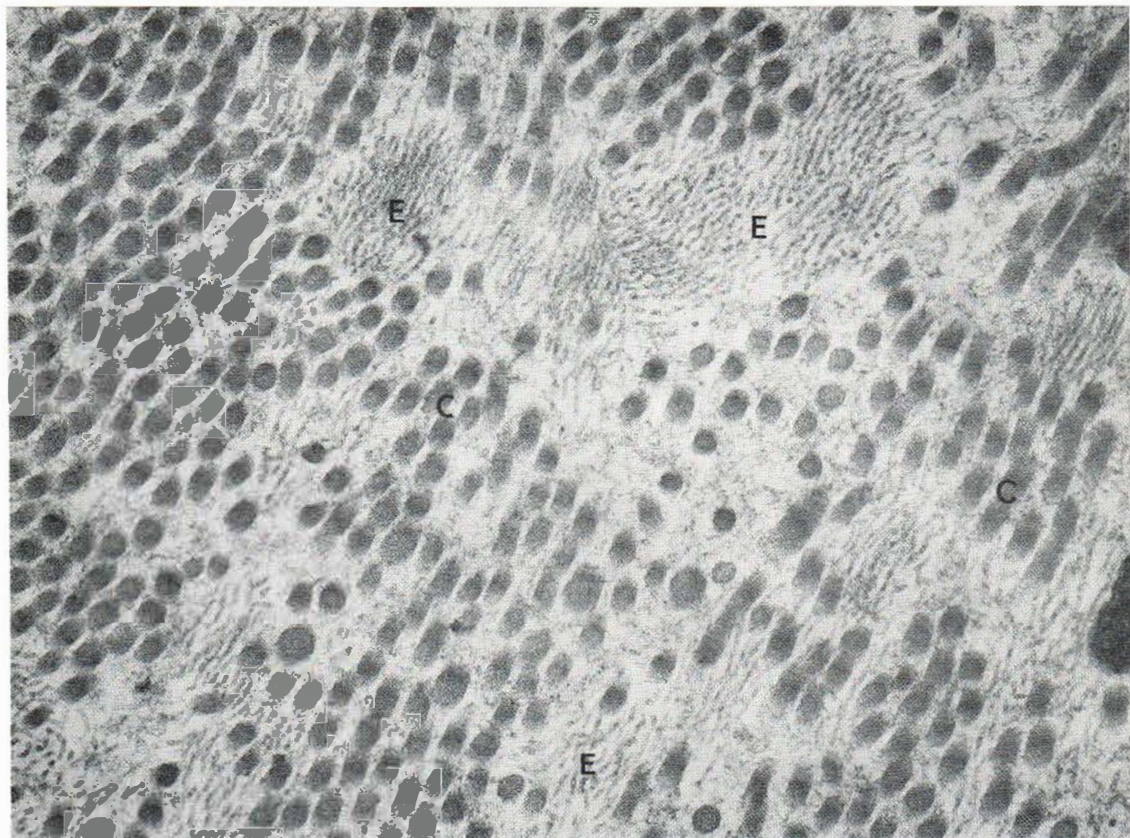


Fig. 4. Numerous parallel-arranged elastic fibrils (E) intermingling with thin collagen fibrils (C). $\times 46\,000$.

changes of the dermo-epidermal junction were interpreted as a result of both disintegration and reconstruction. The threads with knobs and lattice-like filaments represent acid glycosaminoglycans (13, 15). Our findings indicate a high content of acid glycosaminoglycans in the sclerodermic corium and thus confirmed earlier histochemical studies (1, 3, 8, 20).

Individual collagen fibrils showed no pathological figures in scleroderma, whereas both the variation in thickness and the distribution within the bundles are abnormal. The partial thickening of the cell membranes and the dilated endoplasmic reticulum in the fibroblasts indicate fibrogenesis (9, 16, 22). Very fine filament bundles, as shown in Fig. 7, probably represent aggregation of a collagen precursor substance.

Although mast cells contain mostly mature and a few disintegrating granules, numerous villi suggest that degranulation had taken place (12).

Acid glycosaminoglycans of the ground substance seem to be intimately involved in the sclerodermic process.

ACKNOWLEDGEMENTS

The authors express thanks to Mrs Nancy Hansen, Miss Jean A. Sage, Miss Lise Fredbo and Mr John Winther for their technical assistance.

REFERENCES

1. Asboe-Hansen, G.: Some systemic connective tissue disorders pertaining to dermatology. *In* *Connective Tissue in Health and Disease* (ed. G. Asboe-Hansen), p. 274. Munksgaard, Copenhagen, 1954.
2. Bahr, G. F.: Elektronenmikroskopische Untersuchungen bei Sklerodermie. *Aerztl Forsch* 10: 255, 1956.
3. Braun-Falco, O.: Über das Verhalten der interfibrillären Grundsubstanz bei Sklerodermie. *Derm Wschr* 136: 1085, 1957.

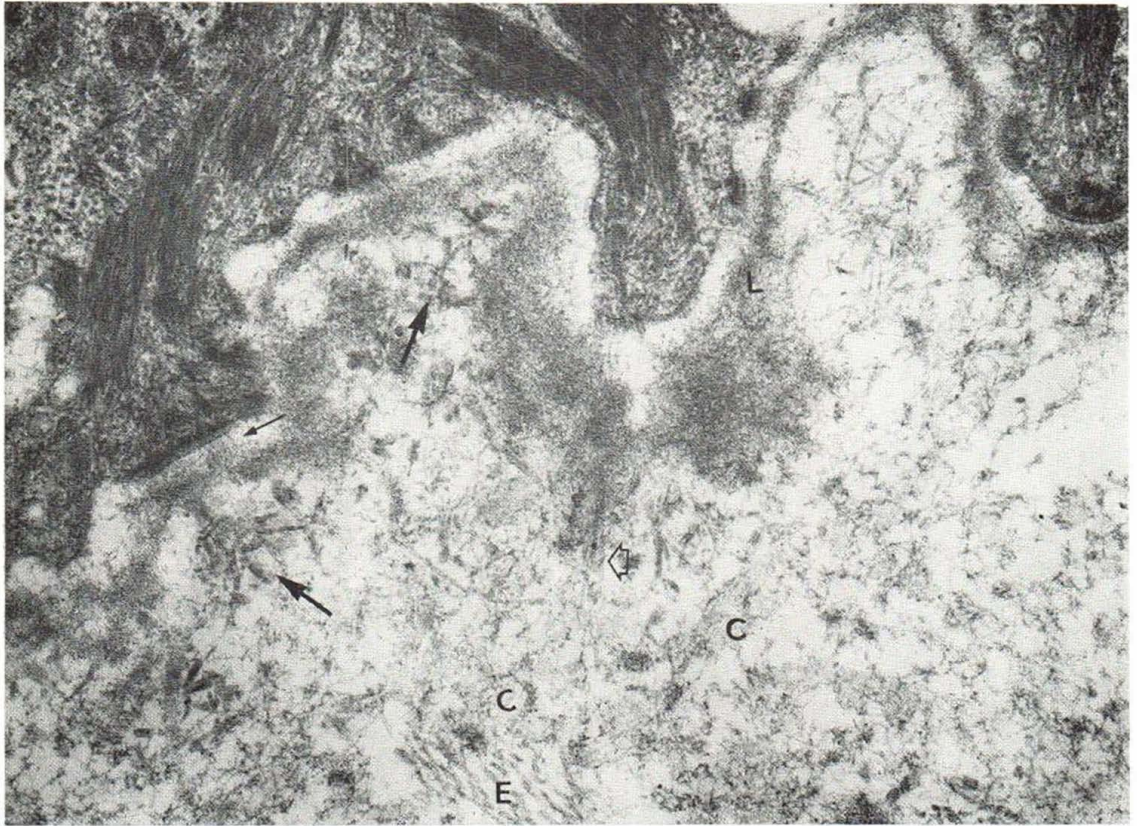


Fig. 5. Basal lamina of epidermis (L) shows an irregular thickness. Distinct anchoring filaments (thin arrow), disarranged distinct anchoring fibrils (thick arrows), and one elastic fibril anchoring (framed arrow) are seen. Many

threads with knobs and lattice-like filaments are seen close to the basal lamina and in the vicinity of faint collagen fibrils (C). Elastic fibrils (E). $\times 46\ 000$.

4. Danielsen, L., Kobayasi, T., Larsen, H. W., Midtgaard, K. & Christensen, H. E.: Pseudoxanthoma elasticum. A clinico-pathological study. *Acta Dermatovener (Stockholm)* 50: 355, 1970.
5. Danielsen, L. & Kobayasi, T.: Degeneration of dermal elastic fibres in relation to age and light exposure. Preliminary report on electron microscopic studies. *Acta Dermatovener (Stockholm)*. In press.
6. Fleischmajer, F. & Krol, S.: Chemical analysis of the dermis in scleroderma. *Proc Soc Exp Biol Med* 126: 252, 1967.
7. Holzmann, H., Korting, G. W. & Forssmann, W. G.: Elektronenmikroskopische Untersuchungen der Haut bei der circumscripiten Sklerodermie. *Arch Klin Exp Derm* 228: 227, 1967.
8. Ishikawa, H., Thies, W., Schumacher, W. & Klaschka, F.: Vergleichende Untersuchungen über das Verhalten der sauren Mucopolysaccharide bei Sklerose der Haut nach Betatron-Bestrahlung, bei Sklerodermie und einigen sklerosierenden Dermatosen. *Hautarzt* 18: 174, 1967.
9. Kobayasi, T.: Development of fibrillar structures in human fetal skin. *Acta Morph Neerl Scand* 3: 257, 1966.
10. Kobayasi, T., Midtgaard, K. & Asboe-Hansen, G.: Ultrastructure of human mast cell granules. *J Ultrastruct Res* 23: 153, 1968.
11. Kobayasi, T.: Electron microscopy of the elastic fibres and the dermal membrane in normal human skin. *Acta Dermatovener (Stockholm)* 48: 303, 1968.
12. Kobayasi, T. & Asboe-Hansen, G.: Degranulation and regranulation of human mast cells. *Acta Dermatovener (Stockholm)* 49: 369, 1969.
13. Kobayasi, T., Danielsen, L. & Asboe-Hansen, G.: Hyaluronate (?) microfibrils in human dermis. *Acta Dermatovener (Stockholm)* 51: 27, 1971.
14. Kobayasi, T. & Asboe-Hansen, G.: Ruthenium Red staining of ultrathin sections of human mast cell granules. *J Micr* 93: 55, 1971.
15. — Electron microscopy of dermal mucopolysaccharides. In preparation.
16. Ross, R. & Benditt, E. P.: Wound healing and collagen formation. IV. Distortion of ribosomal patterns of fibroblasts in scurvy. *J Cell Biol* 22: 365, 1964.

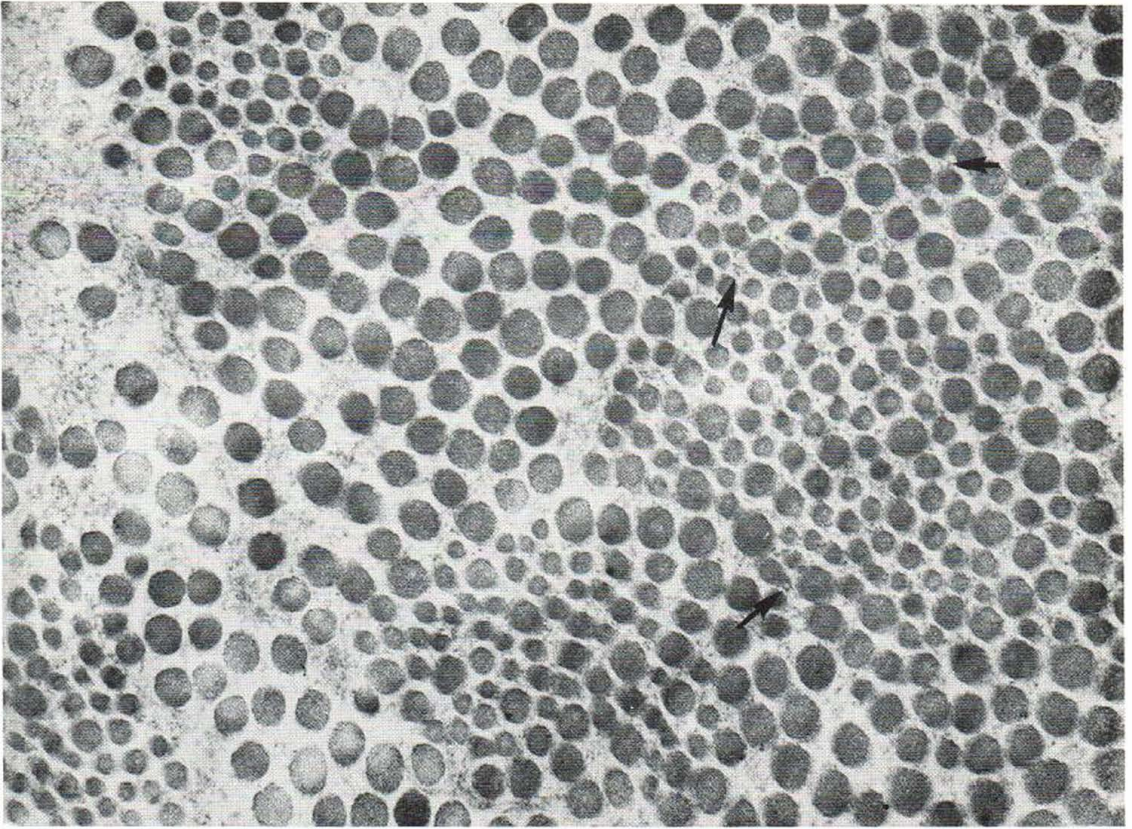


Fig. 6. Areas of both thin and thick collagen fibrils within one bundle. Arrows indicate lattice-like filaments between collagen fibrils. $\times 46\,000$.

17. Ross, R.: The smooth muscle cell. II. Growth of smooth muscle in culture and formation of elastic fibres. *J Cell Biol* 50: 172, 1970.
18. Rupec, M. & Braun-Falco, O.: Elektronenmikroskopische Untersuchungen über das Verhalten der Kollagenfibrillen der Haut bei Sklerodermie. *Arch Klin Exp Derm* 218: 543, 1964.
19. Sage, J. A. & Jersild, A., Jr: Comparative distribution of carbohydrates and lipid droplets in the Golgi apparatus of intestinal absorptive cells. *J Cell Biol*. In press.
20. Szodoray, L. & Tuza, C.: Über die Histochemie der Sklerodermie. *Hautarzt* 11: 63, 1960.
21. Théry, J. P.: Mise en évidence des polysaccharides sur coupes fines en microscopie électronique. *J Microscopie* 6: 987, 1967.
22. Zelikson, A. S.: Fibroblast development and fibrogenesis. *Arch Derm (Chicago)* 88: 497, 1963.

Received September 17, 1971

Takasi Kobayasi, M.D.
 Department of Dermatology
 Rigshospital
 DK-2100 Copenhagen Ø
 Denmark

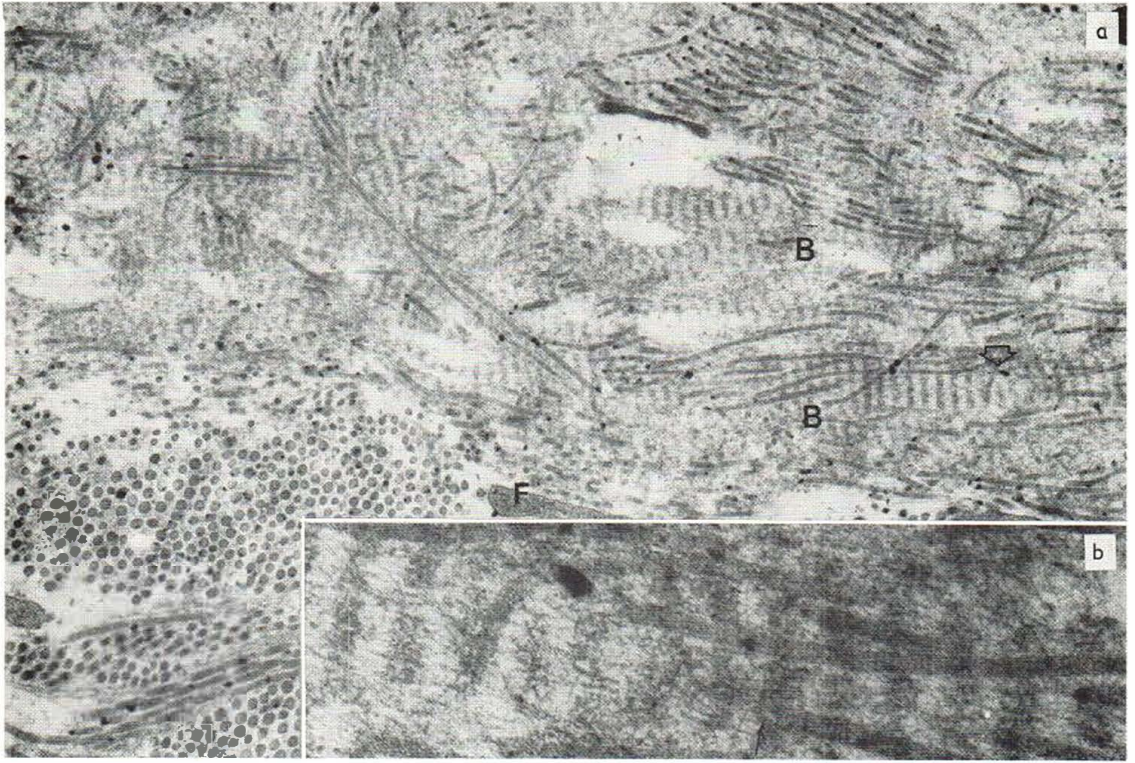


Fig. 7. Surroundings of a vessel with thin collagen fibrils and parallel-arranged straight filament bundles (*B*) showing repeated dense bands. *F* indicates a cytoplasmic pro-

trusion of a fibroblast. The inset shows framed arrow pointed area at higher magnification. $\times 9\,200$; inset $\times 92\,000$.

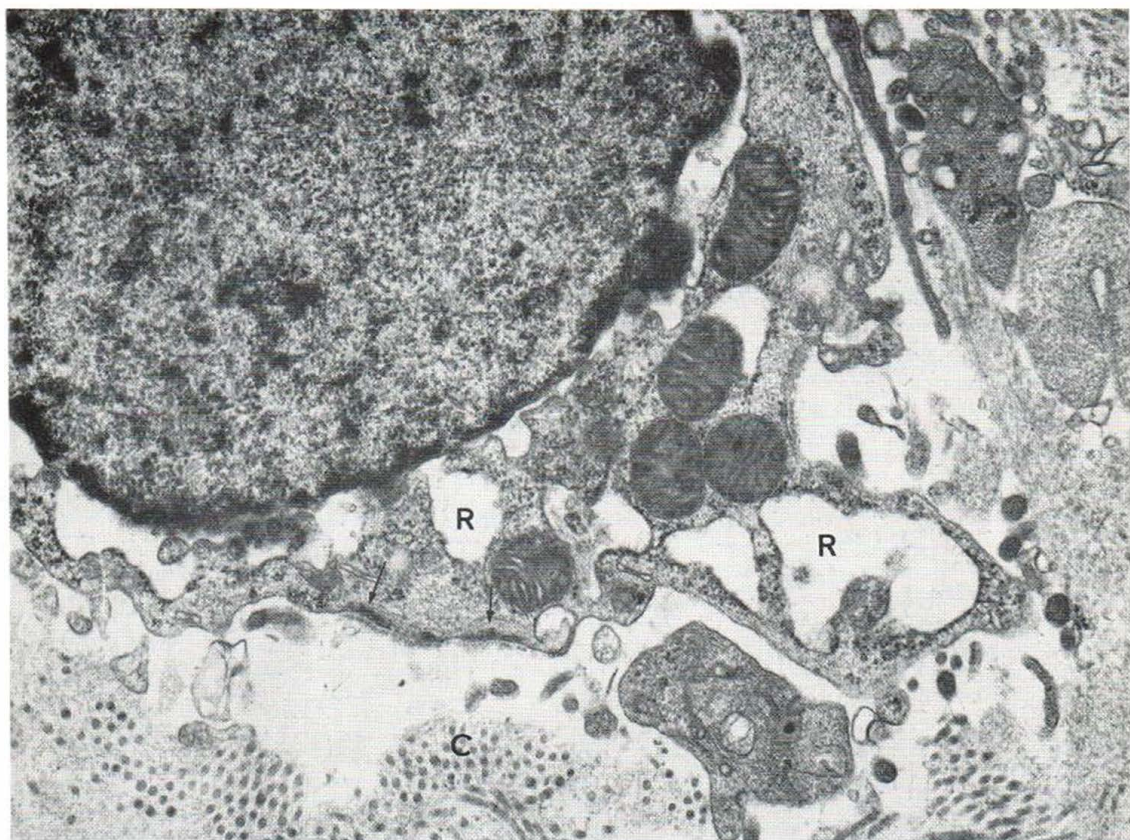


Fig. 8. A fibroblast showing cystic endoplasmic reticulum (R), and partial thickening of the cell-membrane (arrows). Thin collagen fibrils (C). $\times 23\ 000$.

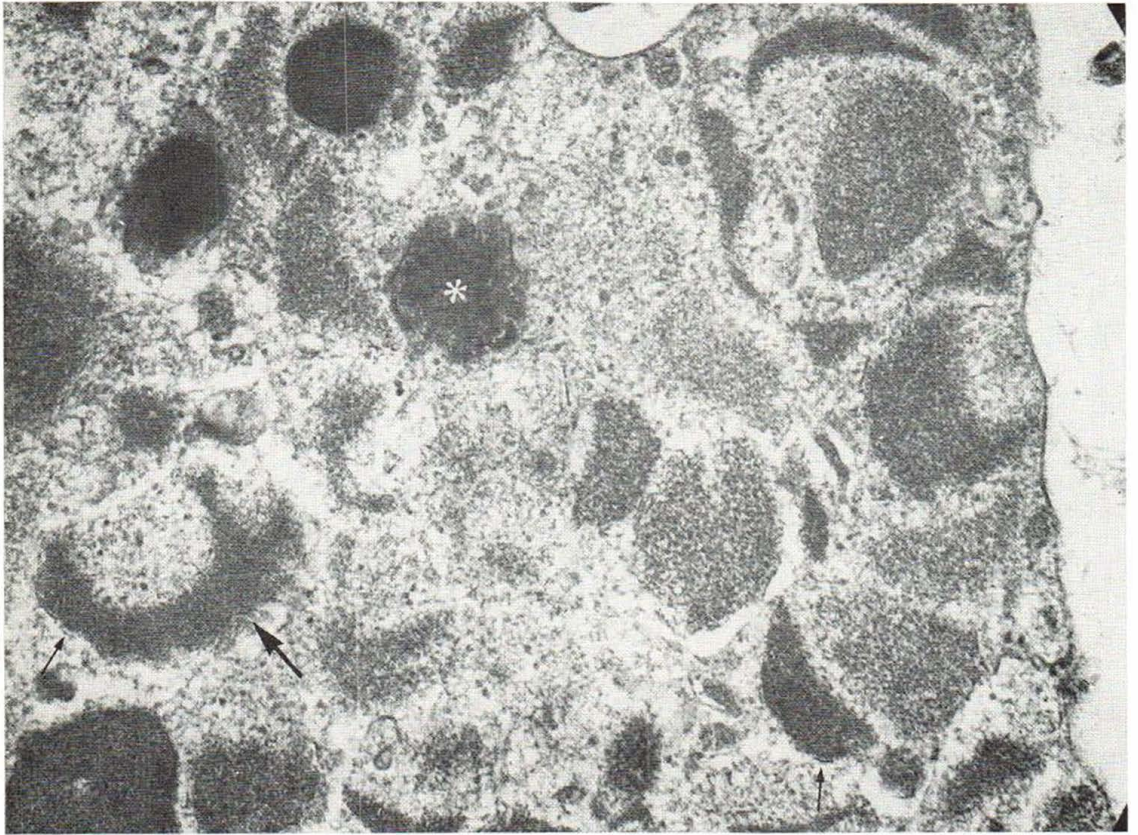


Fig. 9. Mast-cell granules. A few granules (*) are mature. Individual granules show indistinct borders, fragments of scrolls (arrows) and coarse granular patterns in half-

moon shapes (thick arrows). Cytoplasmic villi are few. $\times 46\ 000$.

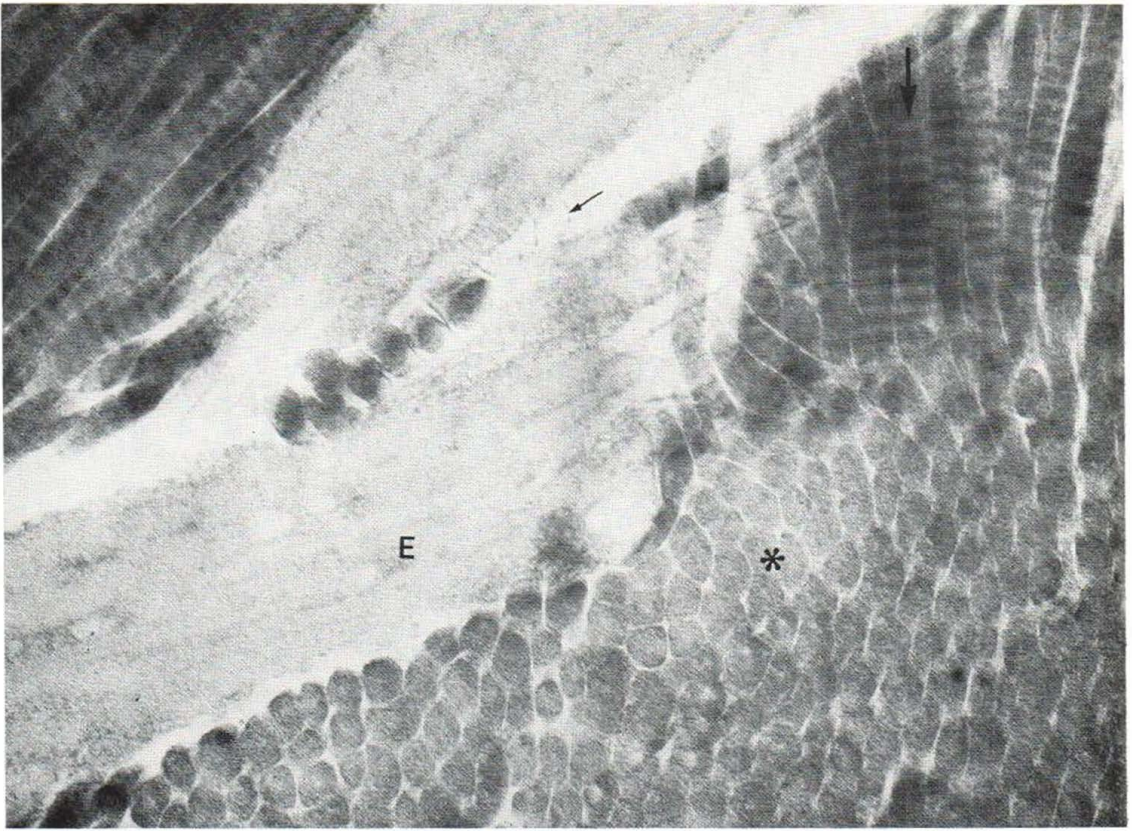


Fig. 10. Compact bundles of collagen fibrils located close to elastic fibres. A collagen fibril shows a polygonal cut surface (*) and an axial periodicity of about 550 Å (thick

arrow). Elastic fibres (*E*) show slight changes. Threads with knobs are rare (thin arrow). $\times 46\ 000$.

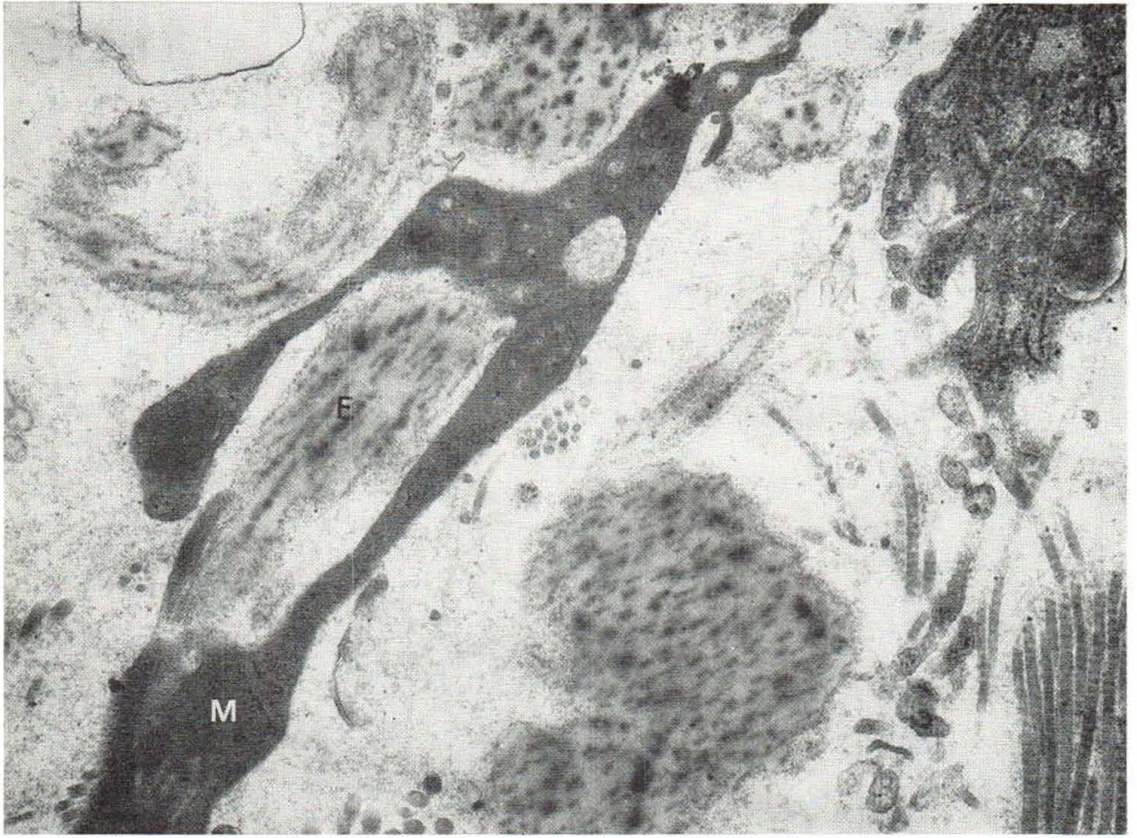

Fig. 11. Altered elastic fibre (*E*) is engulfed by a macrophage. $\times 23\ 000$.

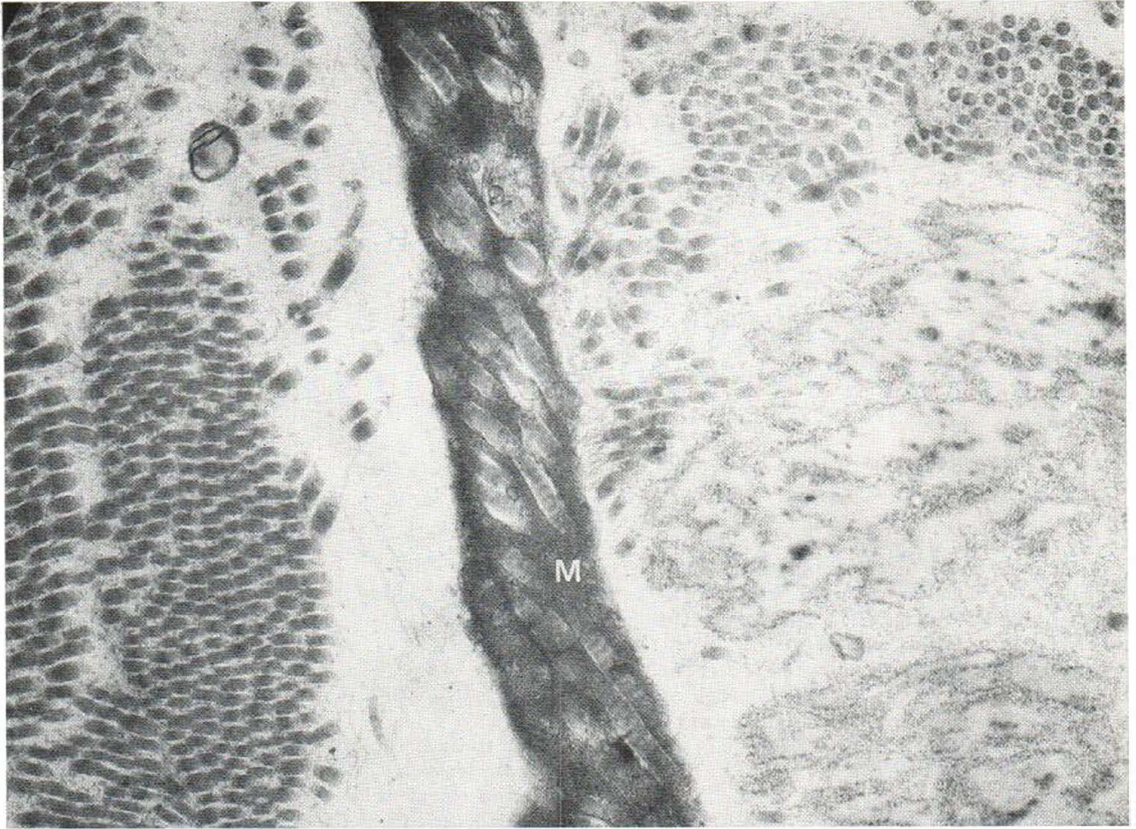


Fig. 12. Collagen fibrils are engulfed by a macrophage (M). $\times 23\ 000$.