

## ACNE AESTIVALIS—MALLORCA ACNE

N. Hjorth, K.-E. Sjølin, B. Sylvest and K. Thomsen

*From the Department of Dermatology, Gentofte Hospital, Department of Pathology Sundby Hospital, Horsens Skin Clinic, Department of Dermatology, Finsen Institute, Denmark*

**Abstract.** This eruption, localized in the acne areas, is common and clinically distinct. The primary lesions are hard, dome-shaped papules 1 to 3 mm in size, pale or pink and with a narrow red halo. Pustules and comedones are rare. 37/40 of the patients were women, nearly all between 20 and 40 years of age. Two only had a past history of acne vulgaris. The eruption starts in spring or summer and lasts for 3 to 6 months. It is little influenced by conventional acne therapy. Histologically the changes are dominated by follicular keratosis with formation of a keratinous cyst which may rupture into the dermis. Heavy sun exposure, but not the use of sunscreens, was invariably implicated and the aetiology remains unknown.

Most Scandinavian patients with acne vulgaris benefit greatly from a fortnight's Mediterranean holiday in the spring. During the last few years, however, patients have presented themselves to us because of an acneiform eruption which developed shortly upon their return to this country. We called it "Mallorca acne", but once the clinical pattern was recognized it appeared that sunbathing in Scandinavia could cause a similar eruption.

### MATERIAL.

The material consists of 40 patients seen at three dermatological clinics. Twenty-four were consecutive cases collected during the summer of 1970, while those seen in previous years were retrieved from a biopsy register and notes of "unusual cases".

#### *Clinical study*

**Sex and age.** 37 of the 40 patients were women. The age groups are shown in Fig. 1.

**Months of onset.** The eruption starts in spring or during the sunny Scandinavian summer months (Fig. 2).

**Clinical features.** The eruption is symmetrical, localized to the face, the sides of the neck, the upper part of the

chest and/or the shoulders. Sometimes the malar and the deltoid regions are the only ones affected (Fig. 3).

The primary lesions are 1 to 3 mm large, hard, dome-shaped papules, either pink or pale, with a narrow red halo. Punctures of the papules yield no pus, and pustules are exceptional. Comedones are not a common feature. The papules may be closely set as in a severe case shown in Fig. 4, but sometimes they are sparse. They tend to itch, especially after sun exposure. Scratch-marks, however, are rare.

**Histopathology.** Biopsies have been performed in 10 out of the 40 cases and examined by one of us (K.-E. S.). The essential changes were a cystic dilatation with hyperkeratosis of the hair follicle, caused by stenosis of the follicular orifice. The corresponding sebaceous gland was always atrophic, probably due to pressure from the cyst. The accompanying inflammatory reaction was slight and consisted of a modest perivascular lymphocytic infiltrate. In a few cases the dilated follicle was ruptured and keratin displaced into the dermis leading to a histiocytic reaction with fibrosis.

**Other characteristics.** Treatment as usually employed for acne is remarkably ineffective. Tetracycline, various local applications, UV light and Grenz rays have all been tried. Puncture of the cysts was of benefit to some patients.

Ten patients were followed until complete clearance of

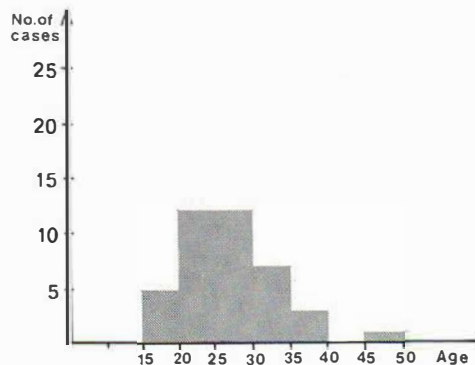


Fig. 1

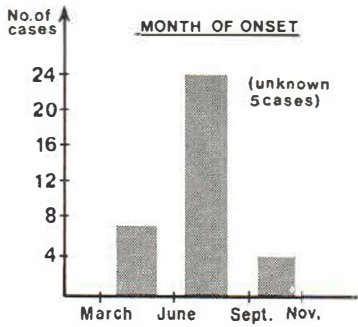


Fig. 2

the eruption which occurred after 3 to 6 months. Scarring was negligible.

Only 2 of the patients had a history of acne vulgaris, which, however, had been quiescent for years. Three other patients had in previous summers been treated by us for identical eruptions, at that time diagnosed as acne vulgaris.

Twenty-four out of 30 patients questioned had used sunscreens; 12 had used one particular brand. The patients had not been systematically questioned about gestagens, but they had not been taken by all.

### COMMENTS

The summer acne here described represents a new entity with clinically distinctive features. It occurs mainly in women and in a slightly higher age group than is usual in acne vulgaris. The lesions are relatively uniform in contrast to the variety seen in acne vulgaris.

Yaffee (3) reported an apparently similar case

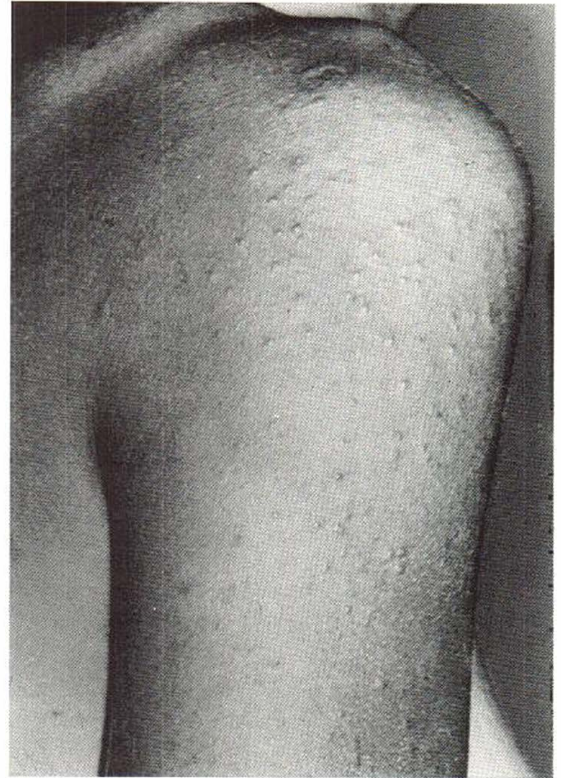


Fig. 3

in the United States a year ago, but whether the disorder is common outside Scandinavia is not known.

Through its relationship to sunbathing the erup-

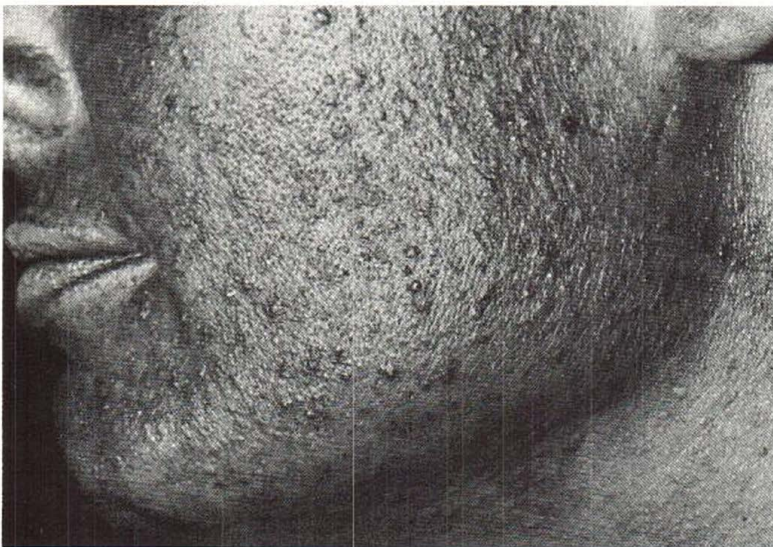

Fig. 4

tion resembles an epidemic follicular keratosis reported from Switzerland (2) and Norway (1). This was provoked by a chemical sunscreen, a benzoxazole derivative, Uvisorb 1414®. The dominant lesions were dark, comedo-like, follicular keratoses, not seen in our cases.

The condition described above is certainly associated with heavy sun exposure and possibly with some other additive factors. The preponderance of women suggests that cosmetics or perfumes are involved in the causation. Because of the Swiss and Norwegian experiences sunscreens were suspected. Six patients, however, stubbornly denied the use of any, and the remainder had used a variety of sunscreens of international brands. Twelve out of 24 had used one particular brand, which, however, according to the manufacturer, covers 50% of the Danish market. On the present evidence we must consider the causative role of sunscreens as unproved. This doubt is supported by later observation of relapses in patients who have been warned against the use of any cosmetics in connection with sunbathing.

The itching is an unexplained feature. Patients associate it with sweating, sometimes with heat,

and sometimes with sun exposure. Miliaria rubra was not observed.

We doubt whether our treatment influenced the spontaneous course of this self-limited disorder. In view of the long duration of the observed cases the short-term prognosis given to the patients must be guarded.

The aetiology awaits clarification.

## REFERENCES

1. Bjørnstad, R. Th.: Comedoid keratosis follicularis faciei. Proc 18th Meeting Scand Dermat Ass, pp. 149-153, 1967.
2. Jadassohn, W., Paillard, R., Hunziker, N., Lozeron, H. & Maggiora, A.: Kératose folliculaire "épidémique". *Dermatologica* 127: 153, 1963.
3. Yaffee, H. S.: Lichen pilaris actinica. *Arch Derm (Chicago)* 101: 254, 1970.

*Received August 2, 1971*

Niels Hjorth, M.D.  
Department of Dermatology  
Gentofte Hospital  
DK-2900 Hellerup  
Denmark