

## ELECTRON MICROSCOPY OF HISTIOCYTIC DISEASES OF THE SKIN

Stewart G. Carrington and R. K. Winkelmann

*From the Mayo Clinic and Mayo Foundation, Rochester, Minnesota, USA*

*Abstract.* Electron microscopic study of three cases of histiocytosis X, three cases of granuloma annulare, two cases each of sarcoidosis, necrobiosis, and nodular subepidermal fibrosis, and one case each of generalized eruptive histiocytoma, allergic granulomatosis, and xanthoma tuberosum has delineated the histiocyte as a large cell with a reniform or lobulated nucleus, exaggerated plasma membrane activity, and numerous cytoplasmic vacuoles. In two of the three cases of histiocytosis X, histiocytes contained Langerhans granules. Tubular cytoplasmic structures were rarely observed; in generalized eruptive histiocytoma.

The term "histiocyte" simply means tissue cell. Whatever else it may be or become, the histiocyte is phagocytic. Phagocytosis has been studied by many methods but is still defined as incorporation of extracellular materials into cell cytoplasm. Many names such as "clasmatocyte", "wandering cell", and "macrophage" have also been used for such phagocytic cells.

Studies of the macrophage system are usually thought to have originated from the systematic work of Metchnikoff in the late 19th century. As early as 1863, it was recognized by von Recklinghausen (26) that, in the inflamed cornea and omentum of different animals, there were ameboid cells that were different from ordinary leukocytes. Later, through the work of Metchnikoff, Maximow, Aschoff, and many others, it became apparent that there was a whole system of specialized cells having the ability to phagocytize matter (14).

This system of cells became known through the work of Aschoff as the "reticuloendothelial system", although the term had been coined earlier by Kiyono (quoted by Doan) (9). Aschoff conceived it as a pluripotential system of mesenchymal cells, with its members represented in the

blood, lymph, sinuses, liver, marrow, connective tissue, and other organs, which had the ability to remain static or to differentiate or dedifferentiate to other forms.

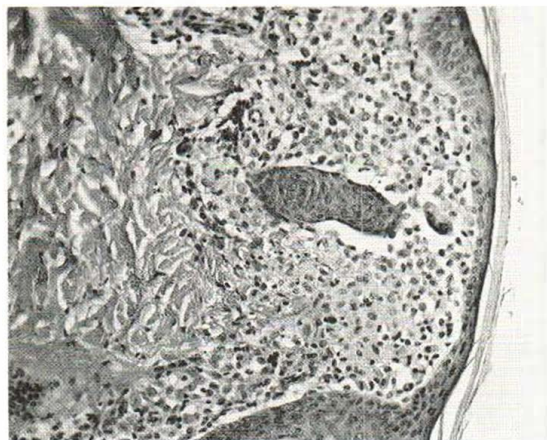While the earlier workers were to a large degree classifying the histiocyte on a functional level, recent workers have endeavored to establish the histiocyte's ultrastructure. The earlier studies by Tanaka (21), Bernhard & Leplus (3), Karrer (12), Novikoff et al. (16), and others provided excellent information regarding cellular detail of the monocyte of human peripheral blood and marrow and macrophages of rat connective tissue, peritoneal fluid, lymph nodes, and thymus, human normal and malignant lymph nodes, mouse lung, and rat liver.

In 1965 Turiaf & Basset (25) added another intriguing aspect of the histiocyte's fine structure. In cells of unmistakably histiocytic proliferation were tubular and racquet-shaped granules identical with the characteristic granules of epidermal Langerhans cells. They, as well as numerous other workers, have since confirmed their original observations (2, 7, 11, 22).

It was the purpose of our study to examine the ultrastructural characteristics of the histiocyte in various human skin diseases and to search for distinguishing or comparative features.

### MATERIALS AND METHODS

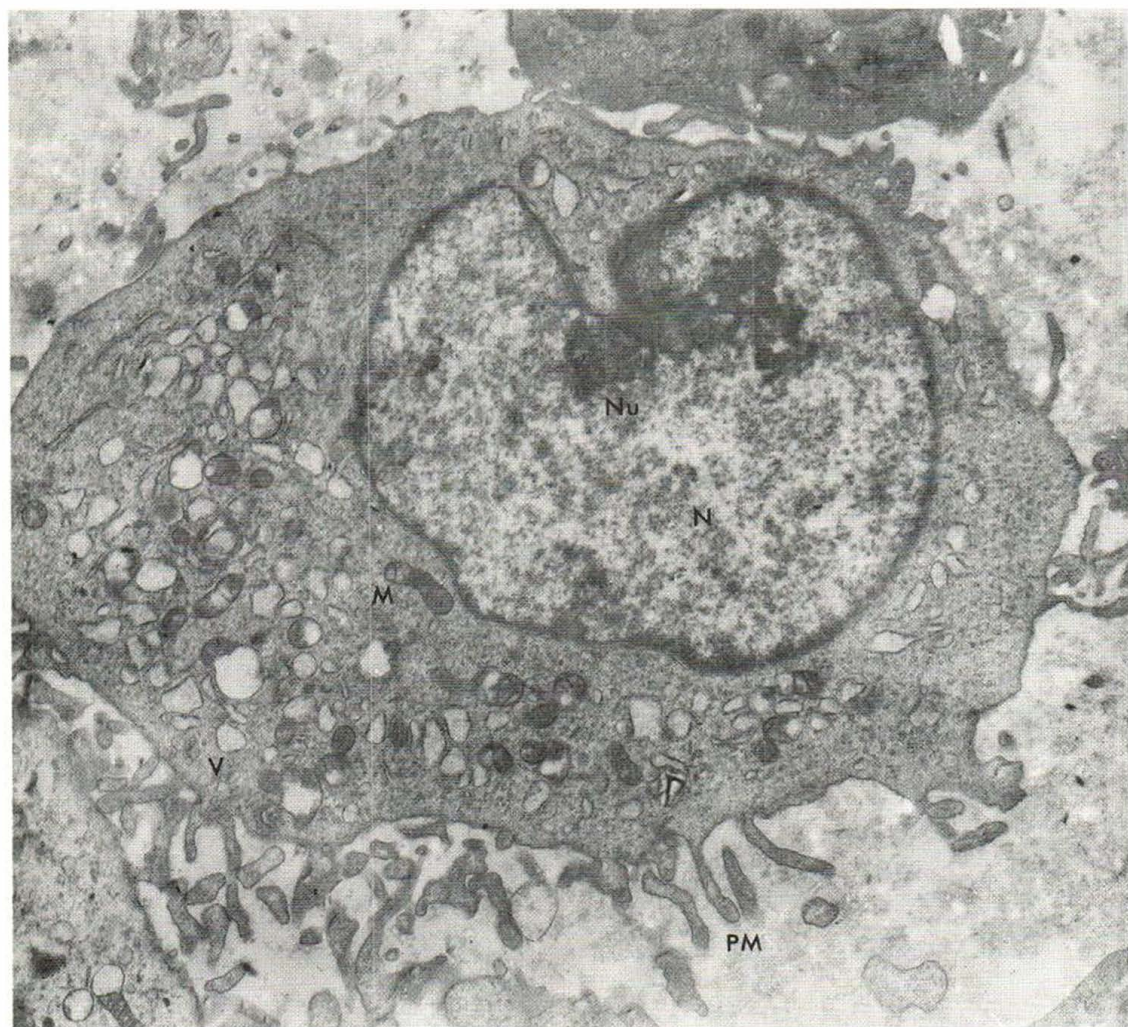Biopsy specimens were taken from a total of 15 patients with the following diseases: histiocytosis X, 3; granuloma annulare, 3; sarcoidosis, 2; nodular subepidermal fibrosis, 2; necrobiosis lipoidica diabetorum, 2; generalized eruptive histiocytoma, 1; allergic granulomatosis, 1; and xanthoma tuberosum, 1.



At least two skin specimens were obtained from each patient, one for light microscopy and one for electron microscopy. The specimen for light microscopy was placed in 10% formalin and subsequently stained with hematoxylin and eosin; in most instances, special stains also were used for fat, mucin, elastic tissue, and microorganisms.

Specimens for electron microscopy were immediately trimmed into approximately 1 mm cubes and placed in either buffered glutaraldehyde fixative for 3 hours or Dalton's solution for 2 hours. After graded dehydration in ethanol, the specimens were postfixed with osmium

*Fig. 1.* Histiocytosis X, showing monomorphic dermal infiltrate composed of histiocytes. (Hematoxylin and eosin,  $\times 155$ .)



*Fig. 2.* Histiocytosis X. Histiocyte, showing active plasma membrane (PM), numerous pinocytotic vesicles (V), mitochondria (M), typical reniform nucleus (N), prominent

nucleoli (Nu), and heavy nuclear membrane. Note voluminous cytoplasm. ( $\times 12\ 750$ .)

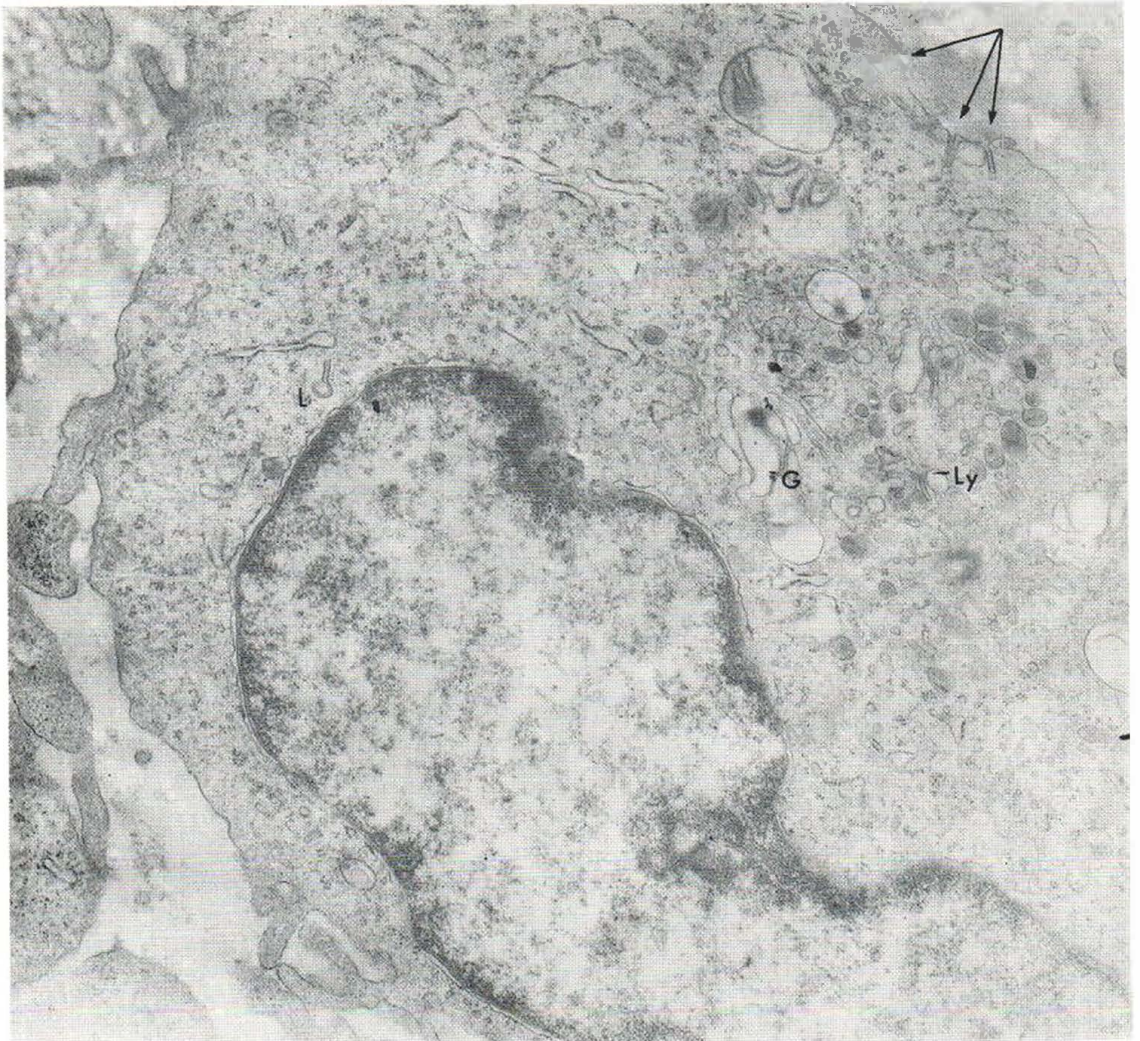

Fig. 3. Histiocytosis X. Histiocyte, showing various intracytoplasmic organelles, including lysosomal granules (Ly), Golgi vesicles (G), and Langerhans granules (L). Three

Langerhans granules apparently are connected to plasma membrane (arrows). ( $\times 18\,130$ .)

tetraoxide, embedded in epoxy resin, and sectioned with an ultramicrotome according to the technique described by Luft (13). Specimens were examined as sectioned, and some material was further stained with lead or uranyl acetate solutions in each case. All tissue sections were examined in the RCA EMU3 electron microscope at 50 kV.

## RESULTS

*Histiocytosis X.* Hematoxylin- and eosin-stained sections of lesions from all three patients studied showed essentially the same histopathologic characteristics (Fig. 1). There was a band-like mono-

morphous infiltrate of histiocytes in the upper dermis and some epidermal thinning overlying the dermal infiltrate.

Ultrastructurally, the histiocytes were characterized by an irregular plasma membrane with numerous folds and villous processes. The nucleus was round or elongated but nearly always had indentations or lobulations and invariably had a thick membrane (Fig. 2). One or more prominent nucleoli were present. Cytoplasm was abundant with varying numbers of apparently normal mitochondria; numerous clear vesicles were present in the cytoplasm, some representing Golgi vesicles

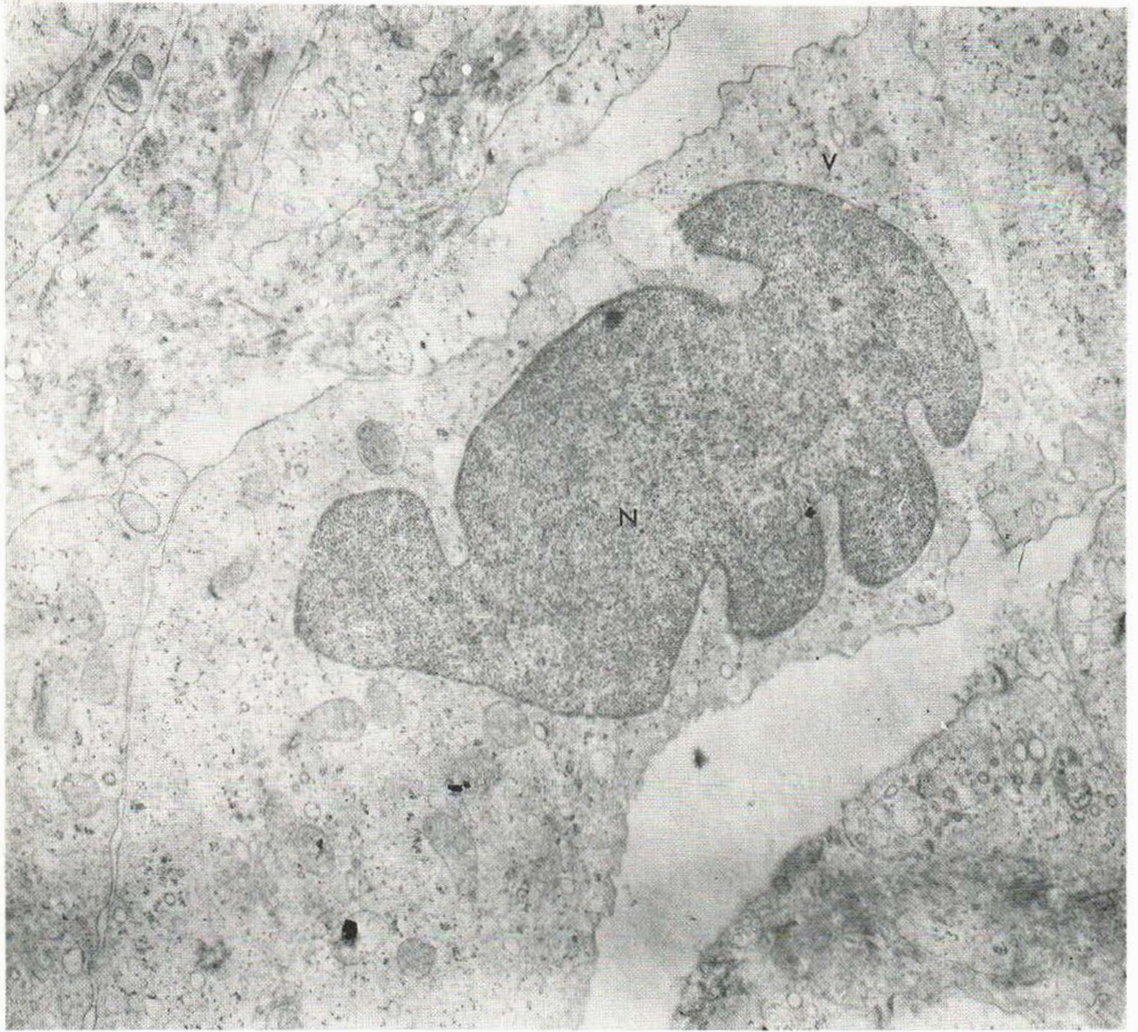


Fig. 4. Granuloma annulare. Histiocyte, showing small, flask-shaped vesicle (V) above nucleus (N). ( $\times 3\ 140$ .)

(Fig. 3). Endoplasmic reticulum was usually "smooth", and free ribosomal particles were regularly seen in the cytoplasm.

In two of the three cases of histiocytosis X, many distinct Langerhans granules were seen in many of the histiocytes (no attempt was made to estimate the percentage of histiocytes containing such granules). The granules were not observed in any other cell type in the dermis. In some instances the Langerhans granules seemed to be attached at one end of the plasma membrane. These structures had the same morphology as the granules within the cytoplasm and were

probably the same. The granules were never seen extracellularly.

Pure storage-type lysosomal granules were numerous in the cytoplasm, especially around the nucleus and the Golgi apparatus.

*Granuloma annulare.* Hematoxylin- and eosin-stained sections from lesions of all three patients showed the typical palisading granulomata composed of central necrobiotic masses surrounded by histiocytes, lymphocytes, and giant cells. Special stains revealed moderate amounts of mucin.

The histiocytes of this lesion were different in several respects from those of histiocytosis X.

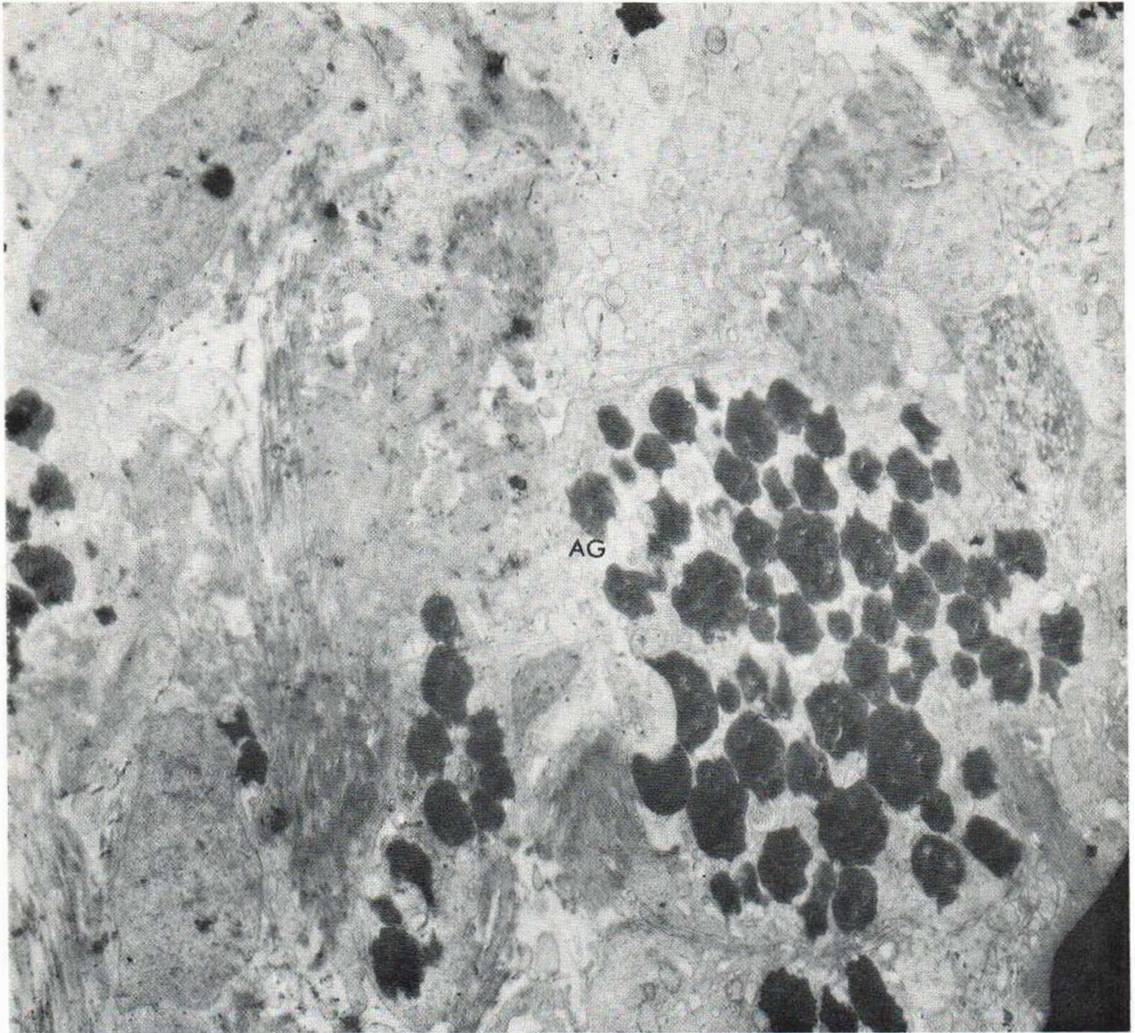


Fig. 5. Granuloma annulare. Histiocyte with very electron-dense amorphous granules (AG) in cytoplasm. ( $\times 8\ 850$ .)

First, none showed Langerhans granules; however, in the cytoplasm, rarely, were curious flask-shaped vesicles reminiscent of Langerhans granules but without the expected internal structure (Fig. 4). Second, in the cytoplasm there were occasional electron-dense granules, generally oval or round, with no apparent external limiting membrane and having an amorphous appearance with occasional slit-like spaces in their centers (Fig. 5); the nature of these granules is not known. Third, plasma membrane activity was present but minimal.

In other respects, the histiocytes of granuloma annulare were similar to those of histiocytosis X,

with indented lobulate nucleus, thick nuclear membrane, and profuse cytoplasmic vacuoles, organelles, and ribosomal particles.

*Sarcoidosis.* The specimens from both patients showed the expected picture of multiple dermal epithelioid ("naked") tubercles. Lymph node biopsy in one case and liver biopsy in the other showed practically identical granulomata. Acid-fast stains were negative in all sections.

The histiocytes in this lesion seemed particularly active, on the basis of the numerous villi of the plasma membrane and numerous cytoplasmic organelles (Fig. 6). Numerous mitochondria were present, and both the pure storage granules and

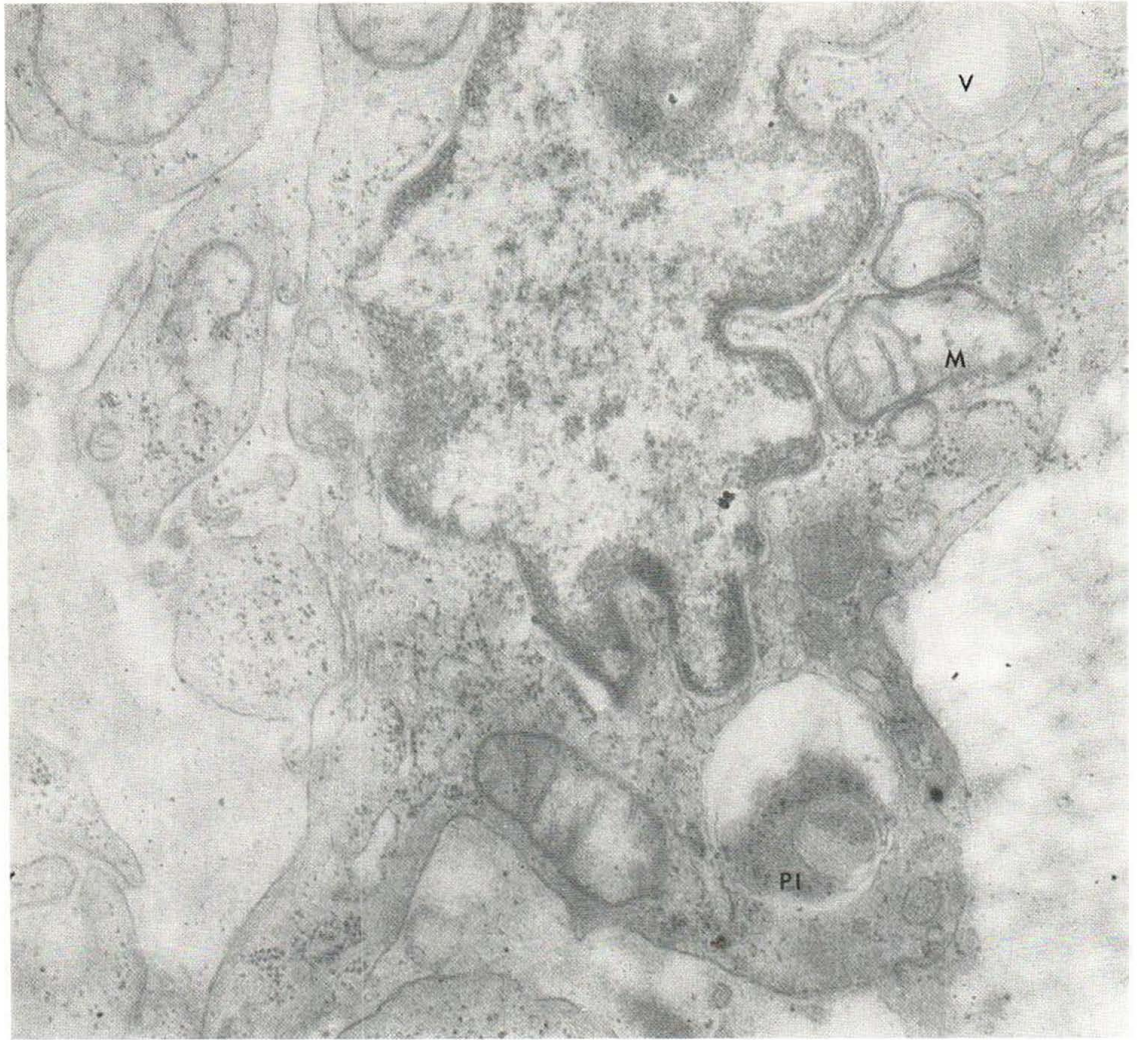


Fig. 6. Sarcoid. Histiocyte with numerous mitochondria (M), membrane-bound vesicle (V), and phagolysosome (Pl). ( $\times 35\ 280$ .)

the residual lysosomal vacuoles were observed. Many small, clear vacuoles were present (presumably pinocytic vacuoles because they resembled those at the plasma membrane). Prominent Golgi saccules were present in most of the histiocytes studied. In Fig. 7 can be seen a large membrane-bound inclusion in the cytoplasm, probably representing phagocytized material. Fig. 8 also illustrates the profuse cytoplasmic organelles, pinocytic vacuoles, and abundant plasma membrane activity.

*Nodular subepidermal fibrosis.* The hematoxylin- and eosin-stained sections from both pa-

tients showed characteristic features for this entity—a histiocytic proliferative reaction accentuated by formation of considerable amounts of fibrous tissue (Fig. 9). Fat and iron stains were positive.

The histiocytes in this lesion had irregular plasma membranes, although villi and pseudopods were minimal. The nucleus was oval with numerous indentations and a very thick membrane (Fig. 10); some nuclei showed “blebs” and reduplications of the membrane. As in the hematoxylin- and eosin-stained sections, numerous lipid and hemosiderin inclusions were present.

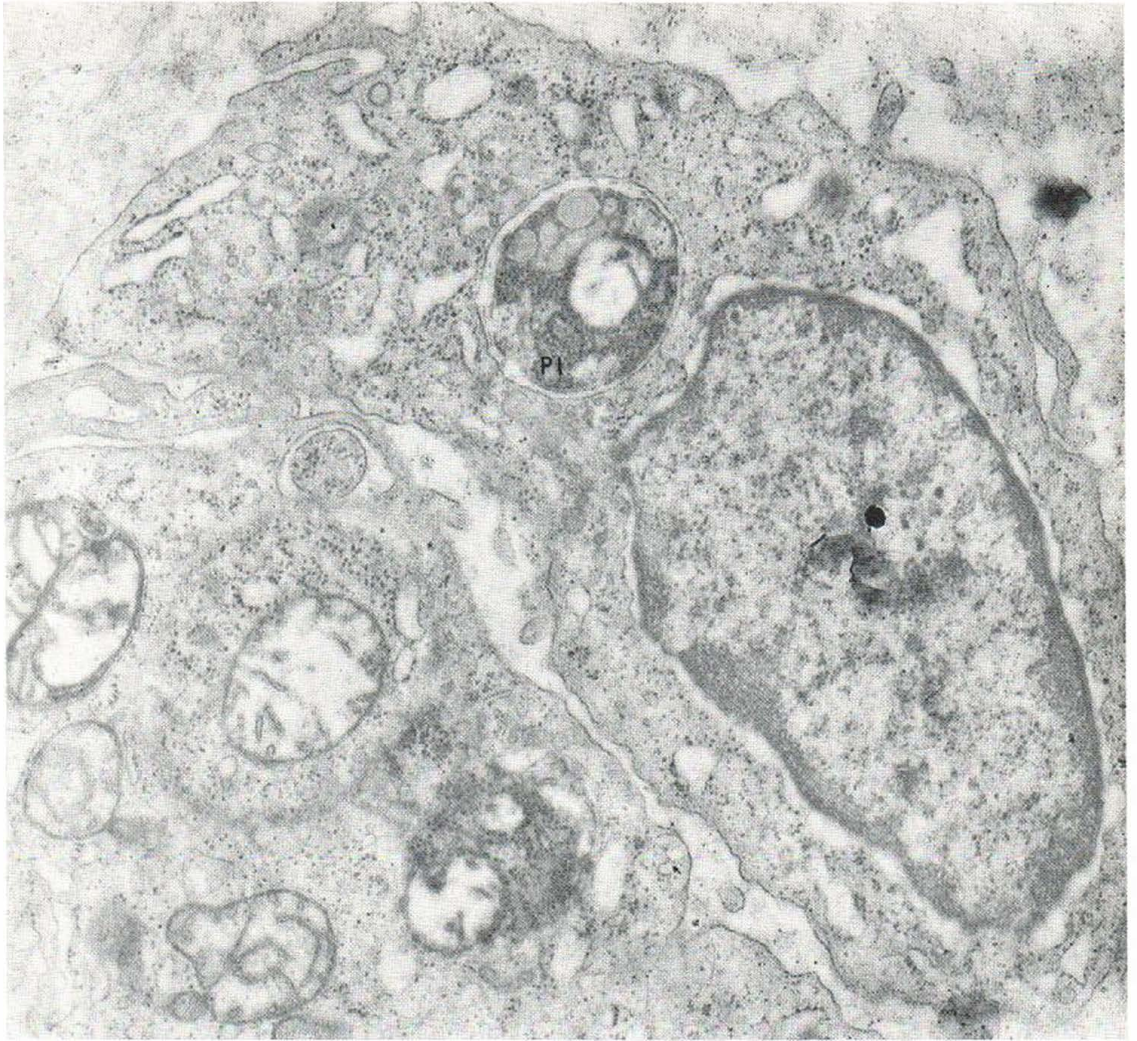

Fig. 7. Sarcoid. Histiocyte, showing large phagolysosome (Pl). ( $\times 26\ 030$ .)

Endoplasmic reticulum and lysosomes were not prominent, but numerous ribosomal particles were seen free in the cytoplasm. Many clear vesicles were seen in the cytoplasm.

Langerhans granules could not be seen in any of the histiocytes of nodular subepidermal fibrosis.

In many sections, the histiocytes of this lesion often resembled fibroblasts, having more of an oval nucleus, prominent rough endoplasmic reticulum, and, in some, perinuclear fibrillar structures.

*Necrobiosis lipoidica diabetorum.* Sections from both patients showed the typical histopathologic features, with scattered foci or irreg-

ular areas of necrobiosis admixed with and surrounded by lymphocytes, histiocytes, and epithelioid cells. Special mucin and lipid stains were confirmatory.

Ultrastructurally, the histiocytes presented a typical picture having the characteristic indented nucleus, thickened nuclear membrane, cytoplasmic organelles, and plasma membrane activity (Figs. 11 and 12). Fig. 12 shows odd, electron-dense, rod-shaped structures (curved, straight, or branching) with no internal structure in the cytoplasm of a histiocyte.

Multinucleated giant cells were frequently encountered (Fig. 13). The cytoplasm of the giant

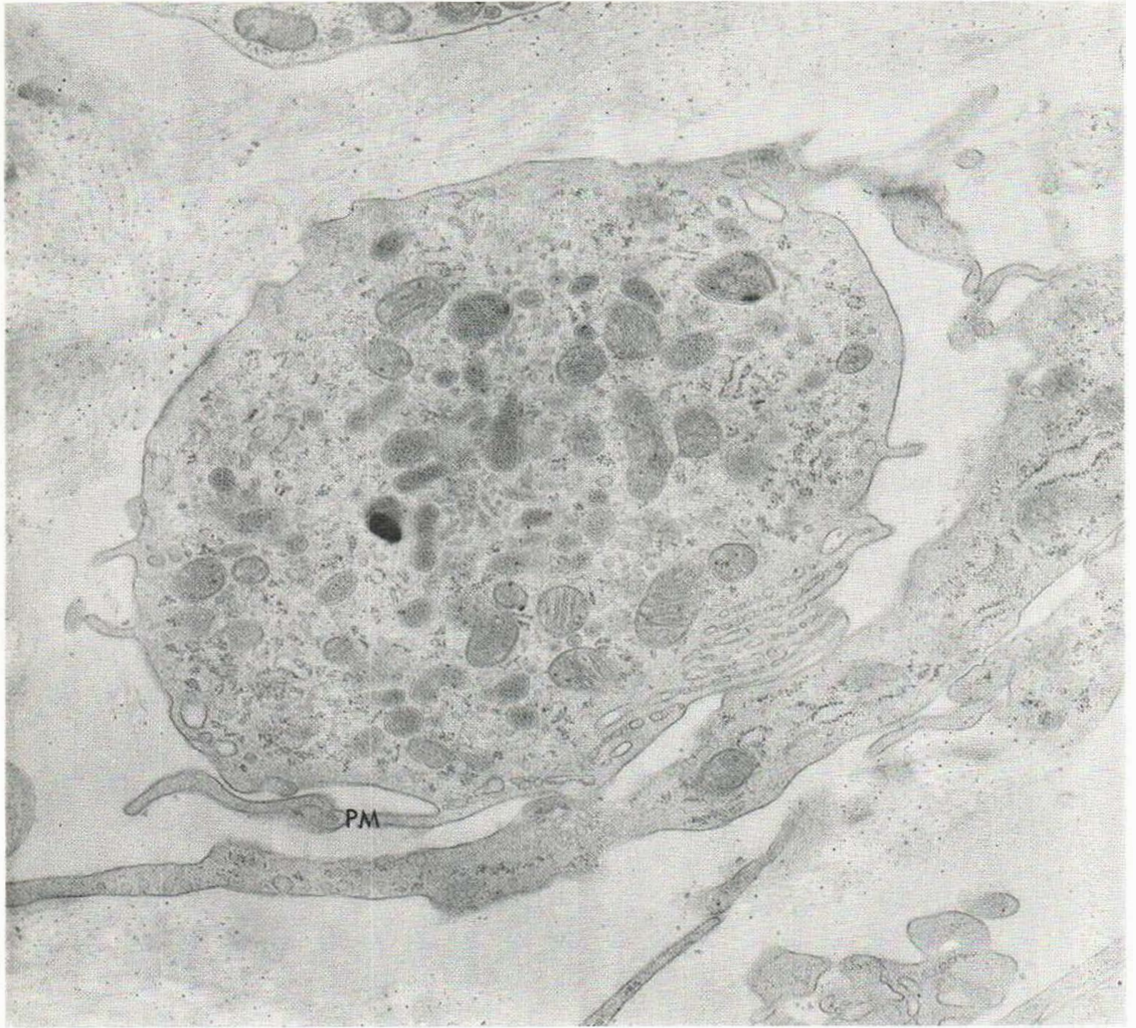


Fig. 8. Sarcoid. Histiocyte, showing plasma membrane activity (PM) and numerous cytoplasmic organelles. ( $\times 17\,930$ .)

cells was literally packed with organelles of various kinds, especially lysosomal structures, vacuoles, and small mitochondria. Intricate plasma membrane interdigitations of adjacent cells were seen.

Langerhans granules could not be found in either the histiocytes or the giant cells of this lesion despite extensive searching.

*Generalized eruptive histiocytoma.* Hematoxylin- and eosin-stained sections revealed vast numbers of histiocytic cells in discrete masses filling most of the dermis, with little if any inflammatory reaction present.

The fine structure of these histiocytes is shown in Fig. 14. Numerous infoldings and indentations of the plasma membrane were present, but rarely were there villi or pseudopods. The nucleus was typically indented with a thick membrane (Fig. 15).

The cytoplasm contained varying numbers of mitochondria and Golgi vesicles; endoplasmic reticulum and free ribosomes were numerous. Storage-type lysosomes and pinocytic vacuoles were abundant. Langerhans-type granules could be seen in some of the histiocytes. Figs. 16 and 17 show a tubular structure with a dense inner



line; these structures were observed rarely and could represent plasma membrane structures as proposed by Hashimoto & Tarnowski (11).

*Allergic granulomatosis.* The hematoxylin- and eosin-stained sections showed scattered dermal granulomata consisting of central masses of necrotic and necrobiotic tissue mixed with acute inflammatory cells and surrounded by epithelioid cells, polymorphonuclear leukocytes, eosinophils, and lymphocytes. Occasional giant cells were seen. Pronounced granulomatous involvement of vessel walls was seen in many of the vessels. Renal biopsy showed a similar picture.

Histiocytic ultrastructure in this lesion was not remarkably different from that in other diseases with active macrophages. One exception was that more histiocytes seemed to have delicate perinuclear fibrils, suggesting a more active role in collagen formation (Fig. 18). Other typical histiocytic features were present, such as the plasmalemmal processes, storage granules, and residual lysosomal vacuoles.

None of the histiocytes contained Langerhans granules.

*Xanthoma tuberosum.* A typical xanthoma was seen on hematoxylin- and eosin-stained sections. Electron microscopy of foam cells, or lipid-laden histiocytes, revealed no unique features. As expected, the cytoplasm of these histiocytes contained numerous small and large membrane-bound lipid inclusions. Otherwise, these histiocytes can be regarded as typical phagocytically active macrophages. None showed Langerhans granules.

## DISCUSSION

The ultrastructure of histiocytes in skin diseases remains remarkably constant, as illustrated by this study. This does not necessarily imply lack of variation in function but rather that the histiocyte is apparently able to accomplish diverse tasks in different pathologic milieu and yet retain its structural identity. Nor does this mean that there are not significant variations in the ultrastructure of the histiocyte in various processes; this variation has been amply documented by the work of Parker & Odland in xanthomata (17), Sarbacker and associates' (19) and Wanstrup and Christensen's (27) studies of sarcoidosis, Muller and co-workers' (15) study of generalized eruptive

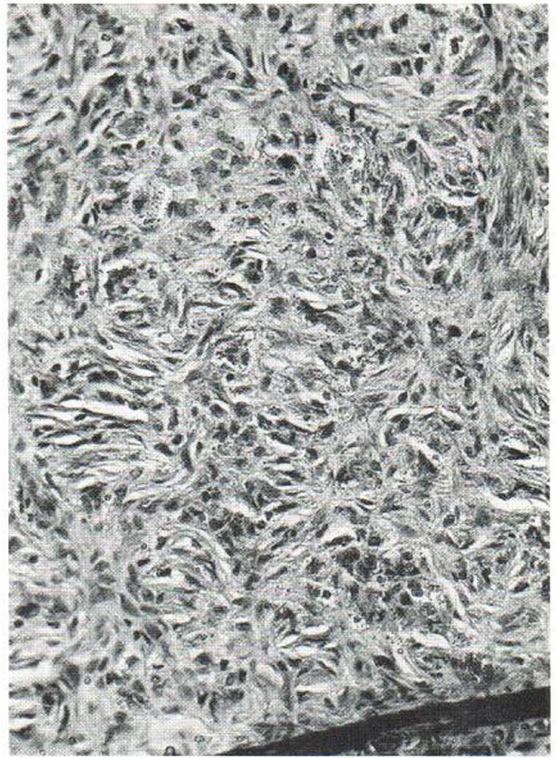


Fig. 9. Nodular subepidermal fibrosis. Proliferative reaction is accentuated by compact masses of fibrous tissue and iron- and lipid-laden histiocytes. (Hematoxylin and eosin,  $\times 195$ .)

histiocytoma, the work of Cohn et al. (8) on the in vivo differentiation of mononuclear phagocytes, the study by Cancilla et al. (7) on histiocytosis X, and the study by Epstein (10) on allergic granulomata. It is possible to characterize the histiocyte ultrastructurally on a morphologic basis in the skin diseases comprising this study.

First, the nuclear morphology remains constant. The typical lobulated nuclear form, or indented contour, and heavy nuclear membrane are nearly always apparent.

Second, the cytoplasm of histiocytes in these lesions, as in normal skin, contains various types of lysosomes and many vacuoles. Such structures are recognized as a constant component of histiocytes and contain numerous hydrolytic enzymes. Many histiocytes contain ultramicroscopic fat (as in generalized eruptive histiocytoma). Therefore, some degree of fat accumulation or formation may be considered a normal evolution.

Third, the histiocytes from all forms of histio-

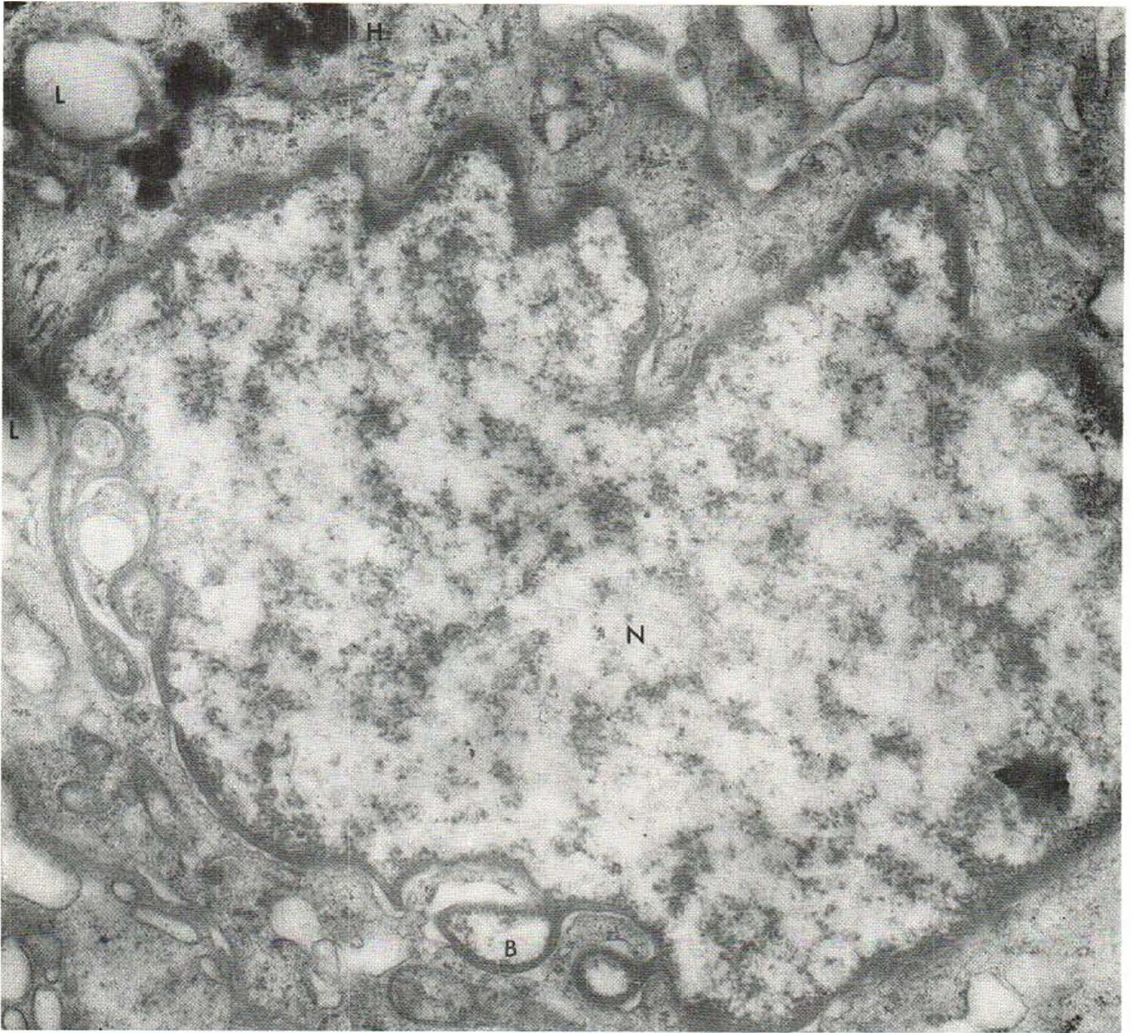


Fig. 10. Nodular subepidermal fibrosis. Histiocyte nucleus (N), showing numerous convolutions, thick nuclear membrane, and reduplications with "blebs" (B) of mem-

brane. Intracytoplasmic lipid (L) and hemosiderin (H) inclusions are visible in upper left corner. (x 26 200.)

cytic disease observed in this study have definite but varying degrees of plasma membrane activity. This is in keeping with the general character of histiocytes in normal situations.

Fourth, on the basis of this study it would seem that histiocytes of histiocytosis X are characterized in addition by Langerhans granules [this has been adequately demonstrated by other workers (2, 7, 10, 11, 25)]. Various theories have been proposed to explain their origin (2, 10, 20, 28); however, a logical explanation at the present time is that they represent primarily the cell's own phagocytized plasma membrane (22, 24) or at

least derive from the cell's phagocytic action (18). In addition to being in histiocytes of histiocytosis X, Langerhans granules have been reported in benign as well as malignant tissue (23), epidermal as well as dermal cells (28), and in humans as well as lower animals (4, 5). This implies that there may be a unique cell line, one possibly as distinct as the mast cell or the fibroblast. The cells that contain Langerhans granules all display the function of phagocytosis. However, other phagocytic cells, such as polymorphonuclear leukocytes, Schwann cells, melanocytes, prickle cells of the epidermis, and renal tubular cells have not been

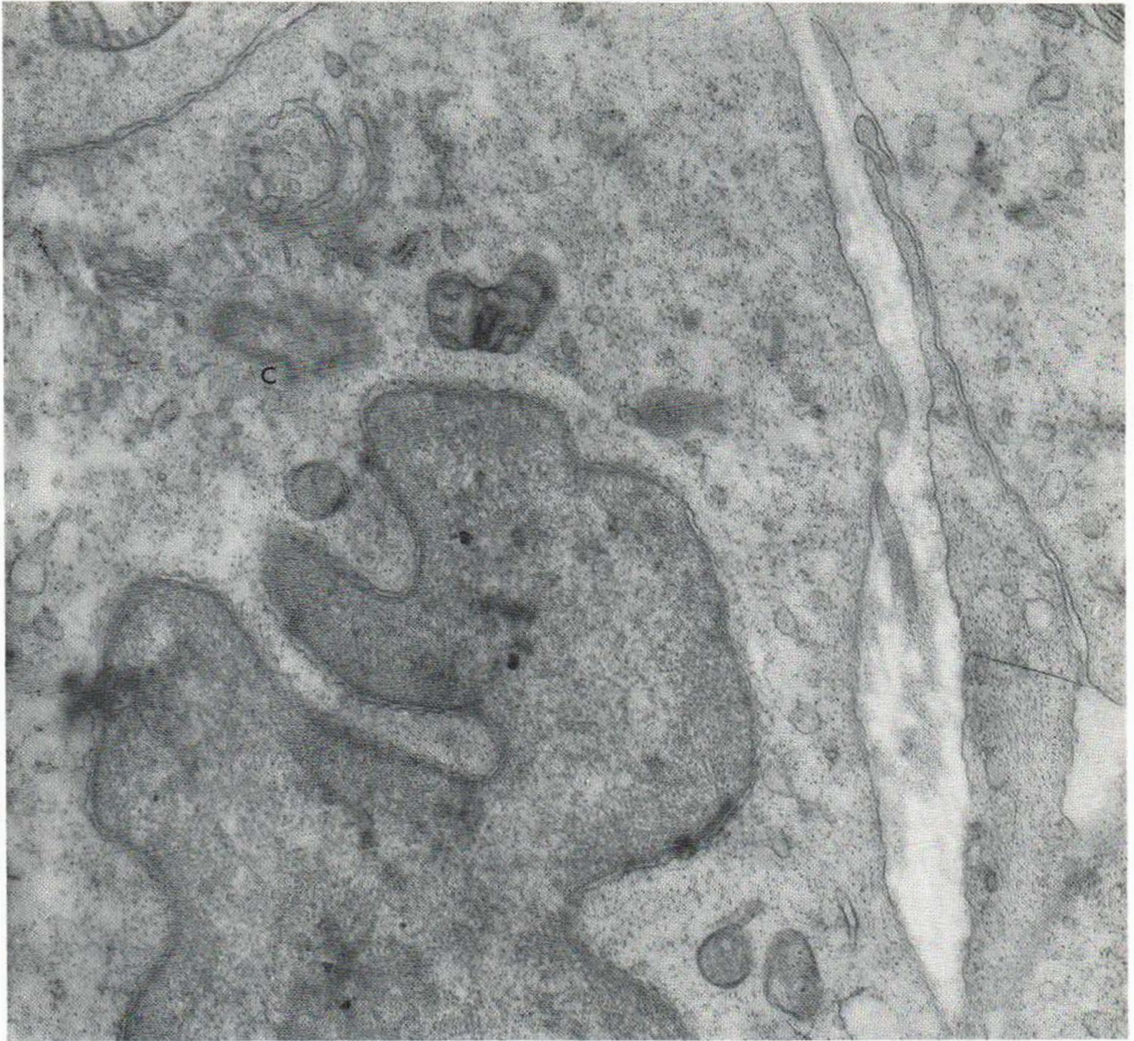


Fig. 11. *Necrobiosis lipoidica diabetorum*. Histiocyte, showing centriole (C) above nucleus. ( $\times 25\ 930$ .)

reported to contain Langerhans granules. Thus, at present it appears that histiocytosis X and profuse pulmonary interstitial fibrosis (1) are the only diseases in which there is proliferation of Langerhans granules. Eruptive histiocytoma must be studied further.

The question of the relationship of histiocytes to Langerhans cells of the epidermis naturally arises because identical or apparently identical organelles are found in each. To imply a common cytogenetic origin on the basis of similar organelles is perhaps superficial thinking; many diverse cells have similar nuclear or cytoplasmic organelles (Golgi zone centrioles, nucleoli) which simply

means that certain basic cellular functions may not necessarily be unique for one cell line. However, histiocytes and Langerhans cells share other features such as nuclear morphology, lysosomes, hydrolytic enzymes, and ATP-ase activity, as well as both being phagocytic. Therefore, as Campo-Aasen & Pearse (6) and Tarnowski & Hashimoto (22) pointed out, such evidence taken together does tend to strengthen the monophyletic concept of these two cell types.

On the basis of our studies, we believe that the histiocyte in human diseases is a distinct cell line, having features that separate it from the fibroblast, the mast cell, the endothelial and

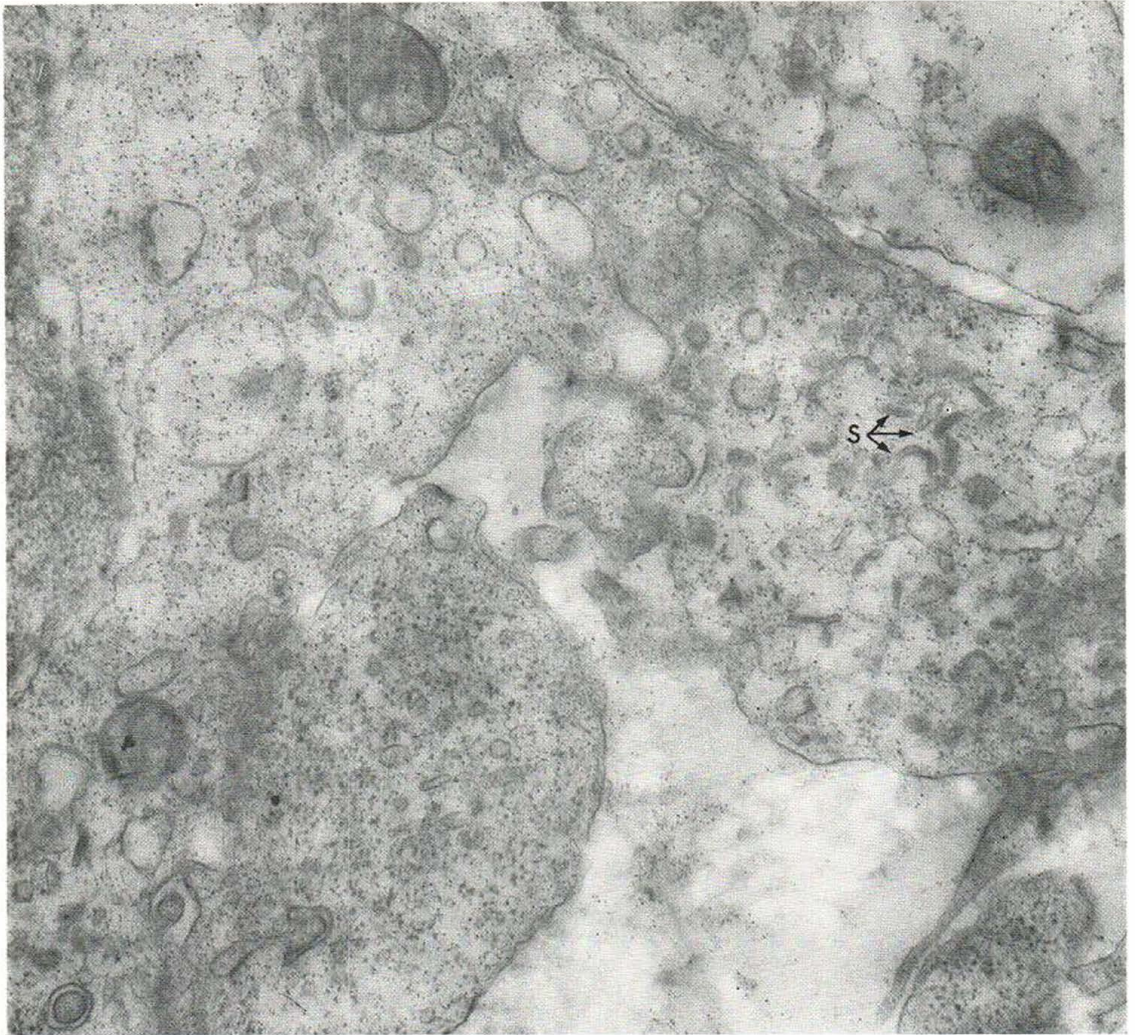


Fig. 12. Necrobiosis lipoidica diabetorum. Cytoplasm of histiocyte, showing numerous straight, rod-like structures (S) having no apparent internal structure. ( $\times 35\ 200$ .)

perithelial cells, the Schwann cell, and other cells found in the dermis. The uniqueness of the histiocyte is not due to any one particular feature but rather is derived from a composite picture of

plasma membrane activity, nuclear morphology, and cytoplasmic contents (Table I); this identity is retained from one disease state to the other and may on occasion be augmented by the presence of distinctive Langerhans granules, as in the case of histiocytosis X and, rarely, eruptive histiocytoma or pulmonary interstitial fibrosis.

Table I. Ultrastructural characteristics of histiocytes

Nucleus	Lobulated or reniform
Plasma membrane (active)	Convolutd with villi or pseudopods
Cytoplasm	Numerous vacuoles (phagosomes, pinosomes, Langerhans granules, lysosomes, lipids)

REFERENCES

1. Basset, F.: Personal communication to the authors.
2. Basset, F. & Nézelof, C.: Présence en microscopie électronique de structures filamenteuses originales dans les lésions pulmonaires et osseuses de l'histio-

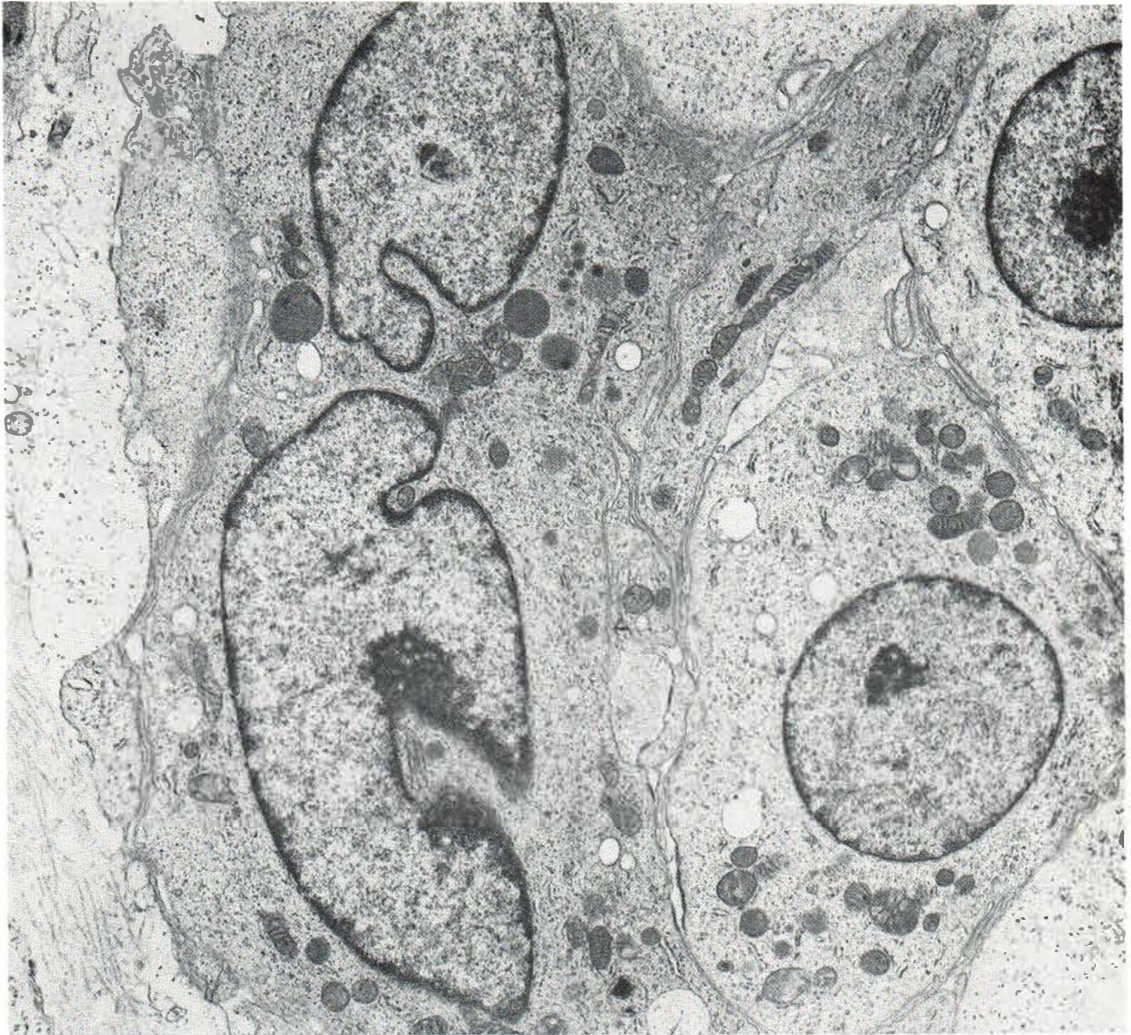

Fig. 13. Necrobiosis lipoidica diabetorum. Multinucleated giant cell. ( $\times 12\,700$ .)

- cytose X: Etat actuel de la question. Soc Med Hop (Paris) 117: 413, 1966.
3. Bernhard, W. & Leplus, R.: Structure fine du ganglion humain normal et malin, p. 44. The Macmillan Company, New York, 1964.
  4. Breathnach, A. S.: Observations on cytoplasmic organelles in Langerhans cells of human epidermis. J Anat 98: 265, 1964.
  5. — The cell of Langerhans. Int Rev Cytol 18: 1, 1965.
  6. Campo-Aasen, I. & Pearse, A. G. E.: Enzymology of cells of Langerhans. Med Cut 1: 35, 1966.
  7. Cancilla, P. A., Lahey, M. E. & Carnes, W. H.: Cutaneous lesions of Letterer-Siwe disease: electron microscopic study. Cancer 20: 1986, 1967.
  8. Cohn, Z. A., Hirsch, J. G. & Fedorko, M. E.: The in vitro differentiation of mononuclear phagocytes. IV. The ultrastructure of macrophage differentiation in the peritoneal cavity and in culture. J Exp Med 123: 747, 1966.
  9. Doan, C. A.: The reticulo-endothelial cells in health and disease. In Physiopathology of the Reticulo-endothelial System (ed. B. N. Halpern, B. Benacerraf & J. F. Delafresnaye), p. 290. Thomas, Springfield, Ill., 1957.
  10. Epstein, W. L.: Granulomatous hypersensitivity. Progr Allerg 11: 36, 1967.
  11. Hashimoto, K. & Tarnowski, W. M.: Ultrastructural studies of racket-bodies in epidermal Langerhans cells and in histiocytosis-X (abstract). Fed Proc 26: 370, 1967.
  12. Karrer, H. E.: The ultrastructure of mouse lung: the alveolar macrophage. J Biophys Biochem Cytol 4: 693, 1958.

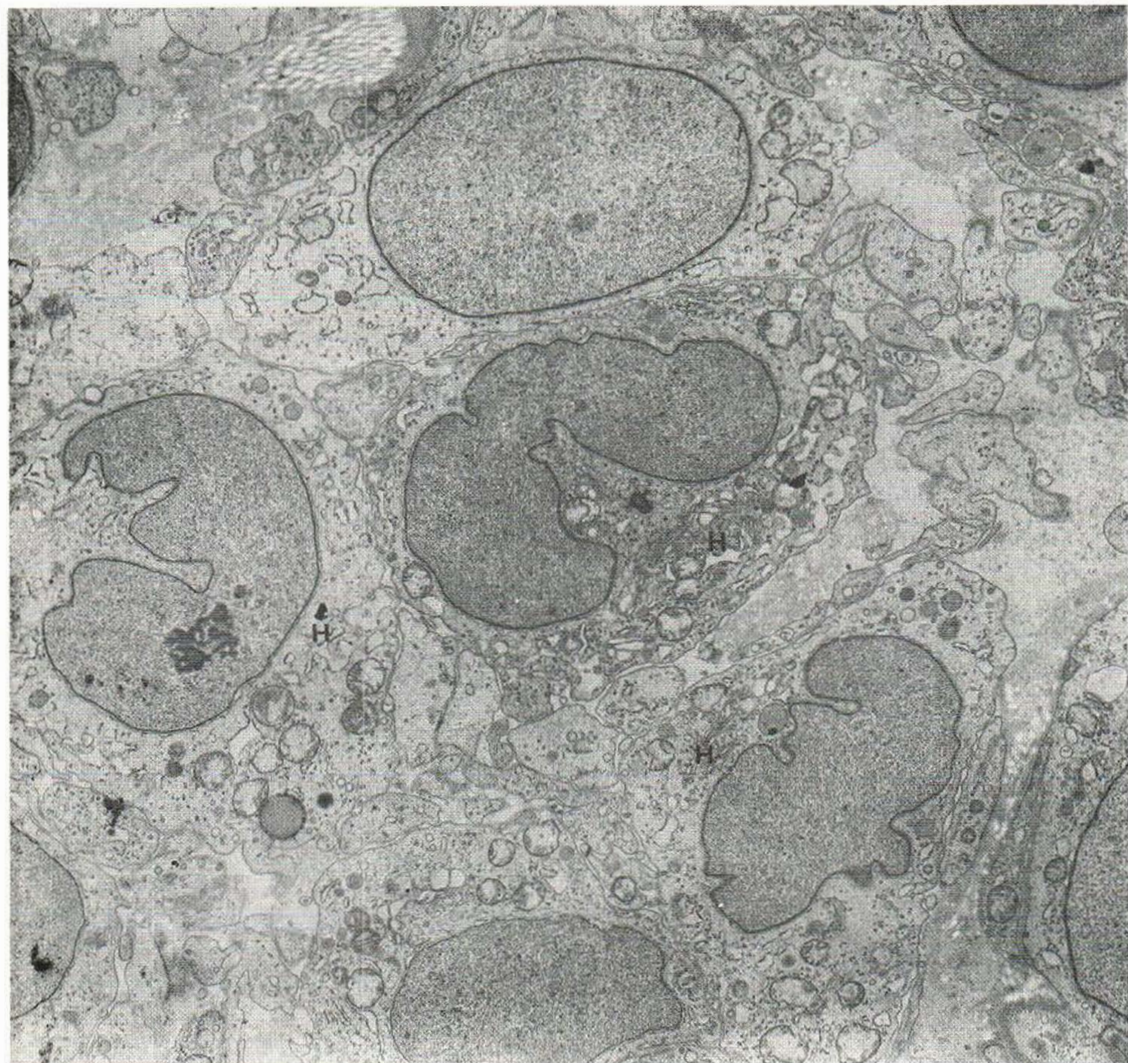


Fig. 14. Generalized eruptive histiocytoma. Low-power view, showing typical histiocytes (H). ( $\times 9\ 100$ .)

13. Luft, J. H.: Improvements in epoxy resin embedding methods. *J Biophys Biochem Cytol* 9: 409, 1961.
14. Metchnikoff, Maximow, A. & Aschoff, L.: Cited by Klemperer, P.: Reticuloendotheliosis. *Bull NY Acad Med* 30: 526, 1954.
15. Müller, S. A., Wolff, K. & Winkelmann, R. K.: Generalized eruptive histiocytoma: enzyme histochemistry and electron microscopy. *Arch Derm (Chicago)* 96: 11, 1967.
16. Novikoff, A. B., Beaufay, H. & DeDube, C.: Electron microscopy of lysosome-rich fractions from rat liver. *J Biophys Biochem Cytol* 2: 179, 1956.
17. Parker, F. & Odland, G. F.: Electron microscopic similarities between experimental xanthomas and human eruptive xanthomas. *J Invest Derm* 52: 136, 1969.
18. Prunieras, M.: Interactions between keratinocytes and dendritic cells. *J Invest Derm* 52: 1, 1969.
19. Sarbacher, J. D., Michelson, H. E. & Zelickson, A. S.: Tubular cytoplasmic organelle in sarcoidosis. *Acta Dermatoven (Stockholm)* 48: 53, 1968.
20. Slaughterback, D. B.: Coated vesicles in absorptive cells of *Hydra*. *J Cell Sci* 2: 563, 1967.
21. Tanaka, H.: Comparative Cytologic Studies by Means of an Electron Microscope on Monocytes, Subcutaneous Histiocytes, Reticulum Cells in the Lymph Nodes and Peritoneal Macrophages. Annual Report, Institute of Virus Research, Kyoto University s.A., vol. 1, p. 87, 1958.

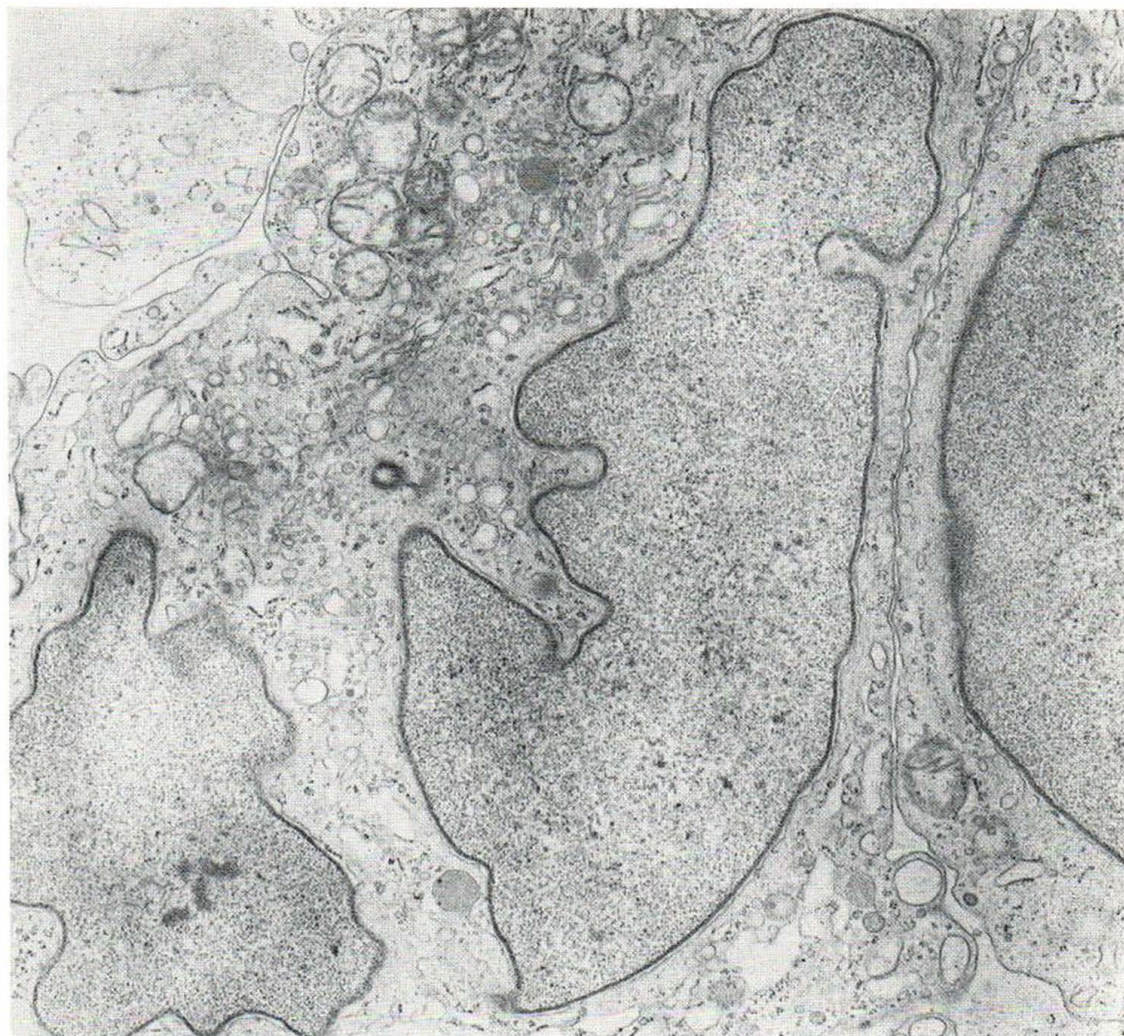


Fig. 15. Generalized eruptive histiocytoma. Characteristic histiocyte. ( $\times 13\ 030$ .)

22. Tarnowski, W. M. & Hashimoto, K.: Langerhans' cell granules in histiocytosis X: the epidermal Langerhans' cell as a macrophage. *Arch Derm (Chicago)* 96: 298, 1967.
23. — Cited by Tarnowski, W. M. & Hashimoto, K. (22).
24. — Newly recognized mode of intracellular transport (abstract). *Clin Res* 15: 255, 1967.
25. Turiaf, J. & Basset, F.: Histiocytose "X" pulmonaire : identification de particules de nature probablement virale dans un fragment pulmonaire prélevé pour biopsie. *Bull Acad Natl Med (Paris)* 149: 674, 1965.
26. Von Recklinghausen, F.: Cited by Cohn, Z. A.: The Metabolism and Physiology of the Mononuclear Phagocytes. *In The Inflammatory Process* (ed. B. W. Zweifach, L. Grant & R. T. McCluskey), p. 323. Academic Press, New York, 1965.
27. Wanstrup, J. & Christensen, H. E.: Sarcoidosis: 1. Ultrastructural investigations on epithelioid cell granulomas. *Acta Path Microbiol Scand* 66: 169, 1966.
28. Zelickson, A. S.: The Langerhans cell. *J Invest Derm* 44: 201, 1965.

Received October 14, 1971

R.K. Winkelmann, M.D.  
 Mayo Clinic  
 Rochester, Minnesota 55901  
 USA

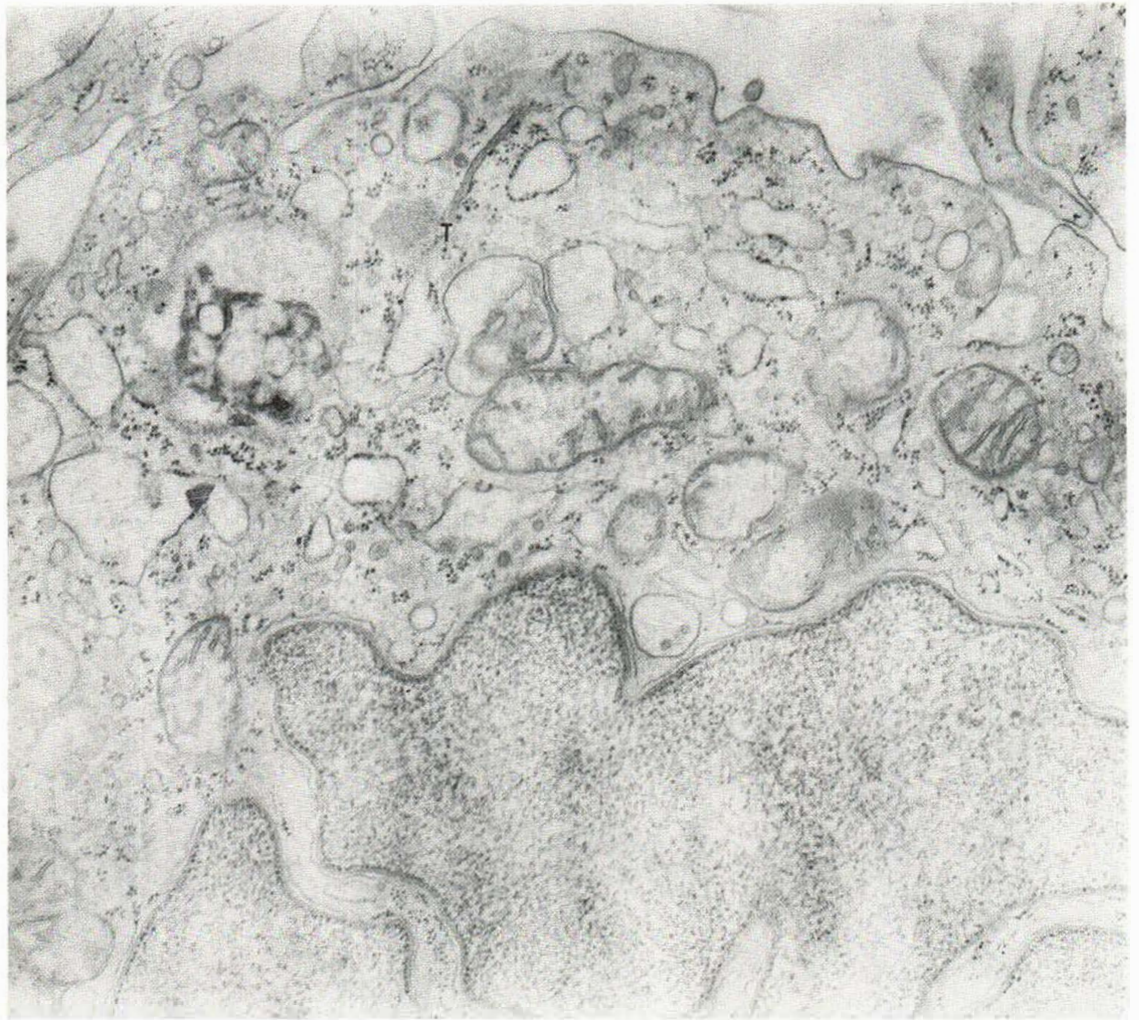


Fig. 16. Generalized eruptive histiocytoma. Histiocyte, showing tubular structure (T) in cytoplasm, with inner electron-dense line. ( $\times 24\ 800$ .)



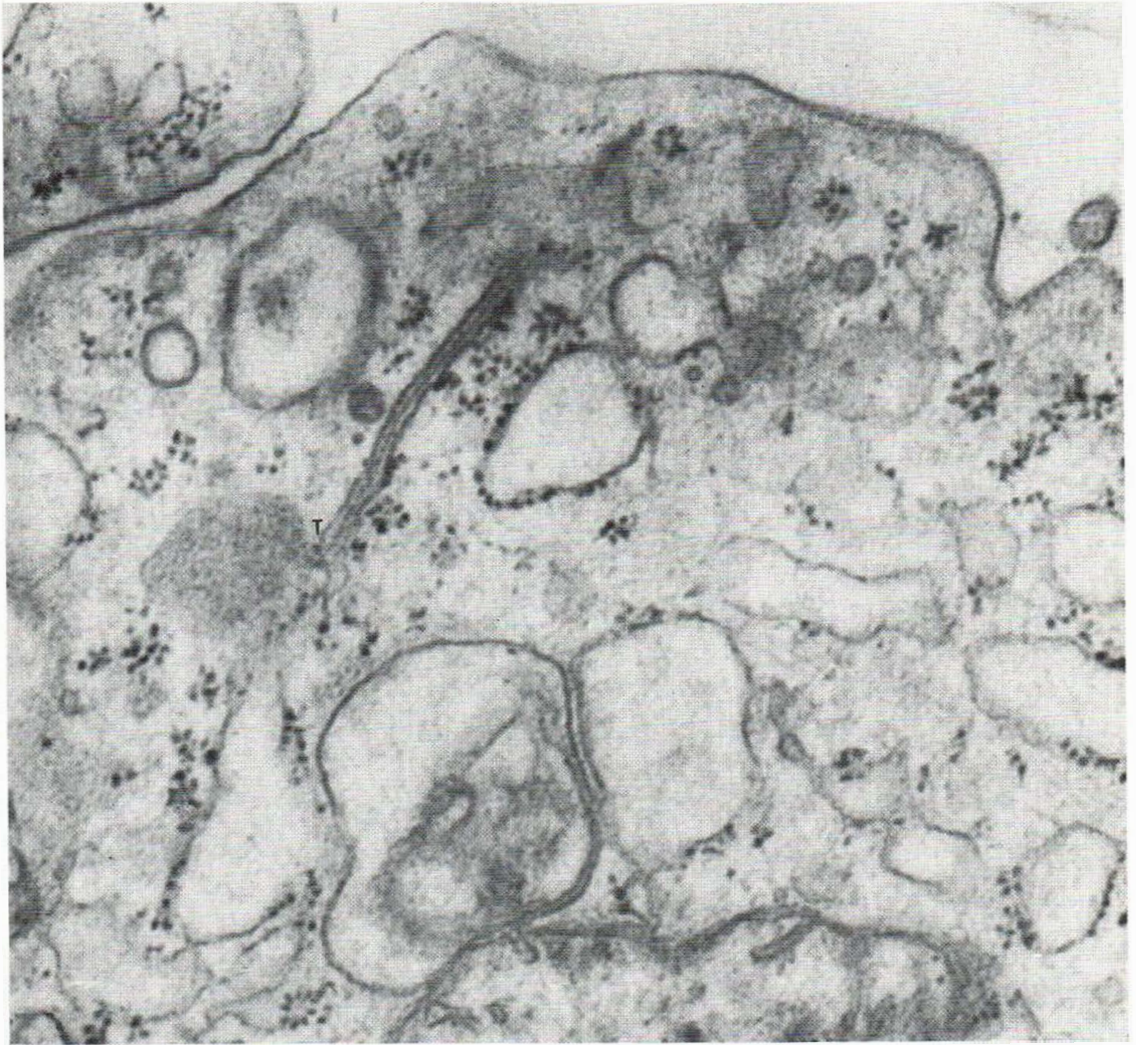
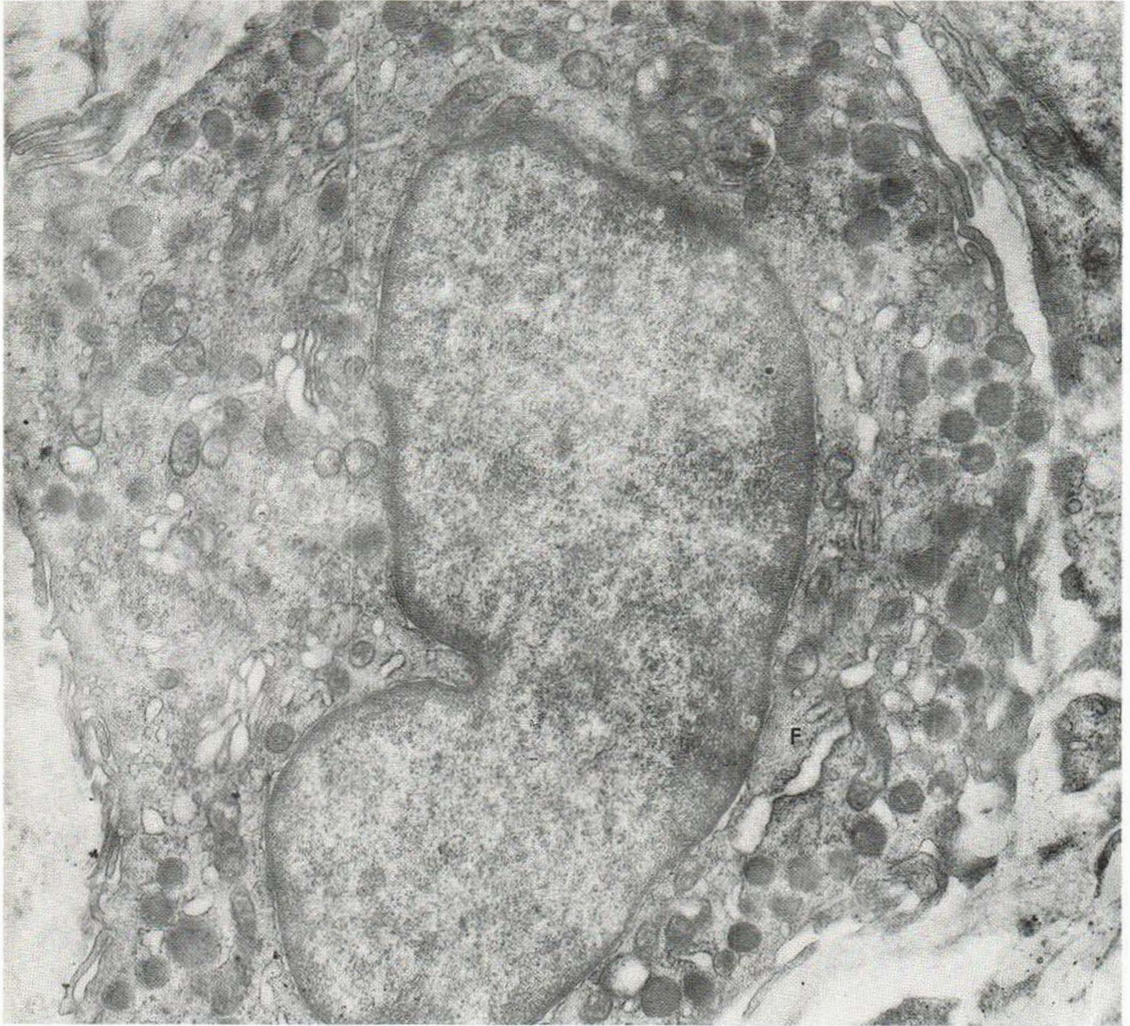


Fig. 17. Generalized eruptive histiocytoma. Higher magnification of Figure 16, showing detail of laminated tubular structure (T). ( $\times 56\ 720$ .)



*Fig. 18.* Allergic granulomatosis. Active histiocyte with perinuclear fibrillar structures (F) which suggest an active role in collagen formation. ( $\times 12\ 825$ .)