

THE SURFACE STRUCTURE OF THE STRATUM CORNEUM

R. Marks and T. Saylan

From the Institute of Dermatology, St. John's Hospital for Diseases of the Skin, London, England

Abstract. A method for the detailed examination of the intact stratum corneum is described, termed "skin surface biopsy". In this technique a cyanoacrylate adhesive is used to remove a sample of the horny layer that retains its *in vivo* structure. This manoeuvre does not disturb the underlying skin, and is simple and quick. Using the skin surface biopsy method the detailed structure of the surface of the horny layer of 14 subjects in 17 sites has been examined. It was also possible to examine the functional anatomy of the stratum corneum by demonstrating the presence of sebum, sweat and melanin in skin surface biopsies.

There have been few systematic studies of the surface structure of the stratum corneum. The usual histological methods of investigation fail to help in this respect as they examine a vertical cross section of skin in which the stratum corneum has been grossly distorted by fixation. Attempts have been made to study the details of skin surface anatomy using close-up photography (6) but a more notable advance was made by Sarkany (7) in using a replica method. A method in which the stratum corneum itself is examined microscopically and in which the *in vivo* interrelationships are perfectly preserved has obvious advantages. Such a method has been described under the term "skin surface biopsy" by Marks & Dawber (4). This technique, which employs cyanoacrylate adhesives, has been used to study the microbiology of the stratum corneum (5), the histochemistry of the horny layer (3), and the scanning electron microscopic ultrastructure of horny squames in the scaling dermatoses (1). This communication describes our studies on the surface structure of the stratum corneum using the skin surface biopsy technique.

MATERIAL AND METHODS

The cyanoacrylate adhesive used in this investigation was ethyl cyanoacrylate (PermaBond-Staident Ltd., Staines,

Mdx, England). To take skin surface biopsies, a drop of the adhesive was placed on the skin to be examined and then overlaid with a dampened glass slide. Light pressure was applied to the slide for 15-20 sec. When the slide was removed it took with it a coherent sheet of stratum corneum some five or six cells thick. The resulting skin surface biopsies were inspected and photographed, using a Leitz SM photomicroscope or a Watson Stereomicroscope.

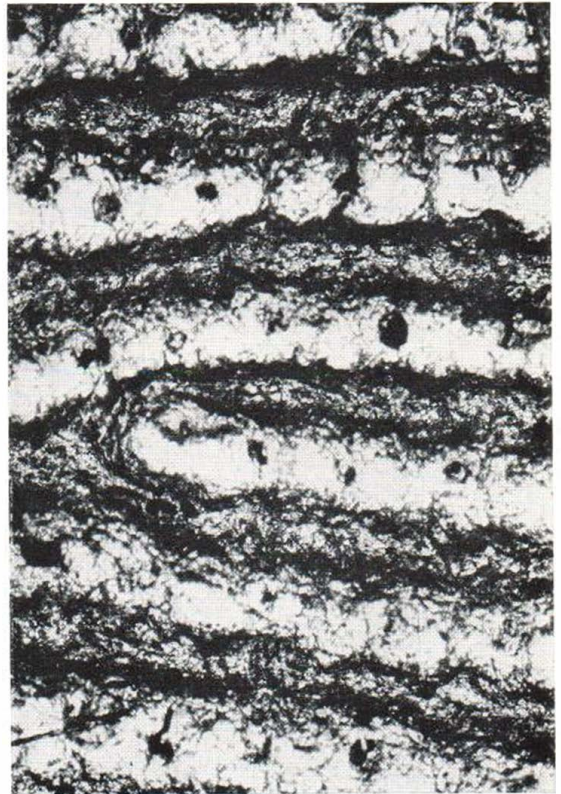
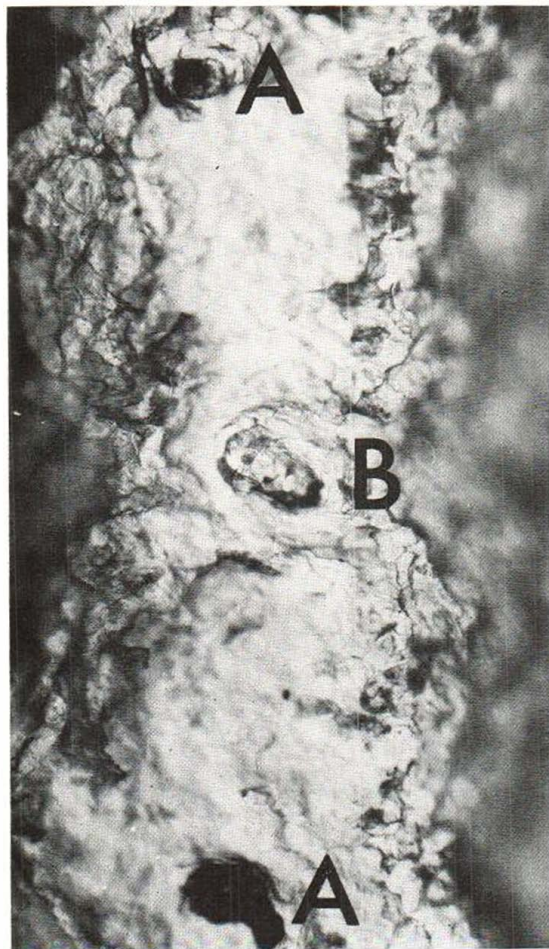


Fig. 1. Caucasian male aged 36. Photomicrograph of skin surface biopsy from palm a few moments after dusting the area with quinizarin powder. Functioning eccrine sweat duct units are easily recognized as regular rows of black dots ($\times 27$).



Skin surface biopsies were taken from multiple sites in 14 volunteers (nine white Caucasians, three dark-skinned individuals from the Indian subcontinent and two negroes). The following sites were sampled: forehead, cheek, chin, neck, upper arm, elbow, forearm, wrist, back of hand, palm, back, chest, breast, calf, shin, dorsum of foot and sole. Six specimens from individuals of differing skin colour were examined for the presence of melanin particles by staining with silver nitrate for 1 hour followed by sodium thiosulphate solution for 20 min. The hair follicles in six specimens were examined for sebum using the following method: The forehead was vigorously wiped clean with ether. After 30 min, skin surface biopsies were taken on cover slips. The unfixed specimens were then stained with Sudan IV for 15 min. After staining the skin surface biopsies, they were mounted in glycerine jelly on glass slides.

Slides with skin surface biopsies were usually examined microscopically in the conventional way with the cover slip nearest to the objective lens. This inspected the *undersurface* of the specimen and the epidermal ridges appeared as grooves and vice versa. This did not seem to be of material importance but could be rectified when required by reversal of the slide so that the microscope slide was nearest the objective lens. To outline eccrine sweat duct orifices from the palms of four individuals, the palms were carefully dried and then quinizarin powder was brushed on to the area, as described by Guttman (2). As soon as mauve dots appeared a skin surface biopsy was taken from the site.

Fig. 2. Caucasian male aged 36. Detail of an area of Fig. 1, showing 2 sweat duct orifices that have taken up the quinizarin (A) and one that has not (B) ($\times 120$).



Fig. 3. Caucasian female aged 34. Photomicrograph of skin surface biopsy taken from the *side* of the lower part of the neck showing a characteristic pattern of closely set interlacing grooves ($\times 28$).



Fig. 4.

Figs. 4 and 5. Caucasian female aged 34. Photomicrographs of skin surface biopsies from the upper arm (4) and the forearm (5). Hair follicles are well displayed (H) ($\times 26$).




Fig. 5.

OBSERVATIONS

The surface structure of the stratum corneum was seen in detail in all the sites examined. Many areas had a distinctive pattern that could be recognised without reference to the source of the specimen. The palm and sole skin surface biop-

sies were easily identifiable, and the regular openings of the eccrine sweat ducts were readily recognised (Figs. 1 and 2). Sweat function, as tested by the quinizarin method described, gave a permanent record of the activity of the eccrine sweat units. Most other sites showed some variation on a repeated pattern of interlacing grooves and furrows which often formed "parallelogram figures". The grooves were close together on the neck (Fig. 3) and over the female breast, but diamond or star shaped on the rest of the trunk and limbs (Figs. 4 and 5). The pattern of skin surface markings around the joints changed according to whether the limbs were extended or flexed.

On the face the pilosebaceous orifices were much larger than elsewhere, relatively close together and readily seen (Figs. 6 and 7). This was especially true for the male beard area where the entire pattern was dominated by the large follicular openings (Fig. 8). The arrangement of the cuticular scale around the larger hair follicles was often in the form of a collar (Fig. 9). In addition, in some sites there was a complex arrangement of grooves and furrows that seemed to radiate from many pilosebaceous orifices. Staining specimens for lipid with a Sudan dye, as described above, demonstrated functional pilosebaceous units, even to the naked eye.

Melanin granules were easily seen intracellularly in those specimens stained with silver nitrate. They were regularly shaped and sized and there sometimes appeared to be an accumulation

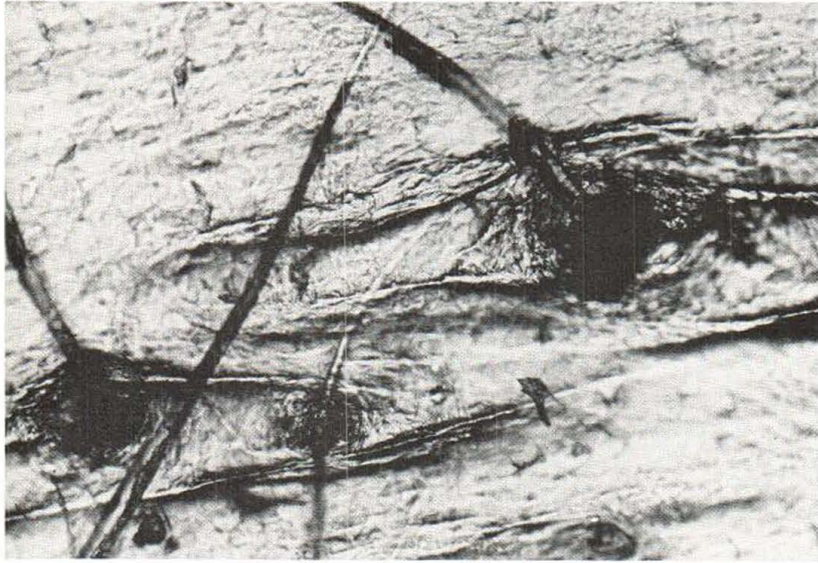


Fig. 6. Caucasian female aged 34. Photomicrograph of skin surface biopsy from forehead to show large, closely set, hair follicles ($\times 64$).

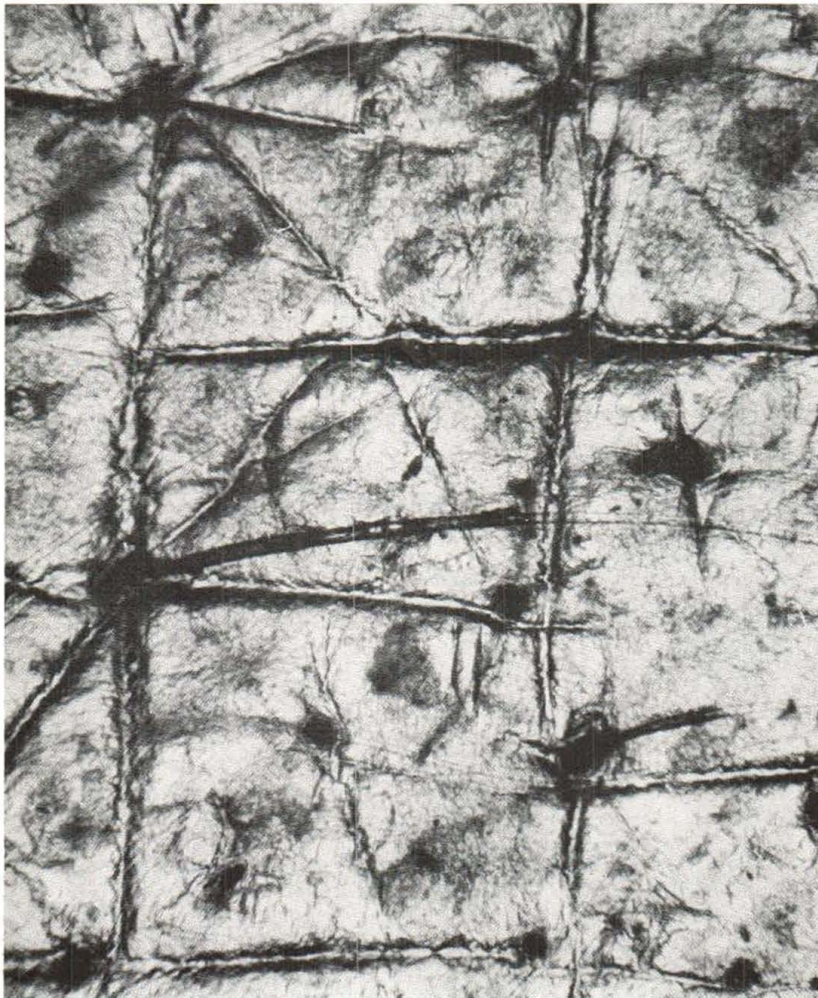

Fig. 7. Caucasian female aged 34. Photomicrograph of skin surface biopsy from forehead to show hair follicles, from which radiate grooves in the horny layer, and sweat duct orifices ($\times 27$).



Fig. 8. Caucasian male aged 36. Photomicrograph of skin surface biopsy from the chin of a man to show the many very large hair follicles ($\times 26$).

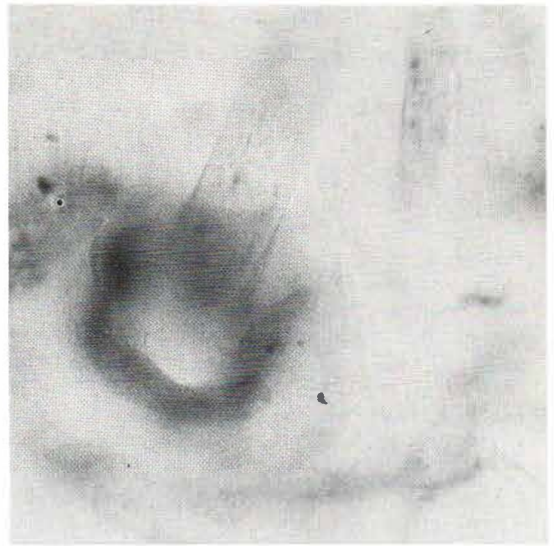

Fig. 9. Caucasian female aged 28. Photomicrograph of skin surface biopsy from the forehead to show the cuticular collar around a hair follicle ($\times 67$).

of granules centrally. The number of granules increased with increasing depth of skin colour (Fig. 10).

COMMENT

The skin surface biopsy method provides a rapid and convenient method for the study of the surface structure of the stratum corneum. It was possible to see considerable detail in skin surface biopsies; there appeared to be a complex arrangement of cuticular scale around the hair follicle orifices. The arrangement of horny squames around the mouths of the sweat duct orifices was also well visualized. Fine detail of the stratum corneum can be seen with the replica technique of Sarkany (7). However, replicas are more difficult to take than skin surface biopsies and, furthermore, as the horny layer itself is examined with this technique, it is possible to investigate the functional anatomy of the horny layer by demonstrating the production of sebum, sweat and melanin. No ethnic differences were noted in the

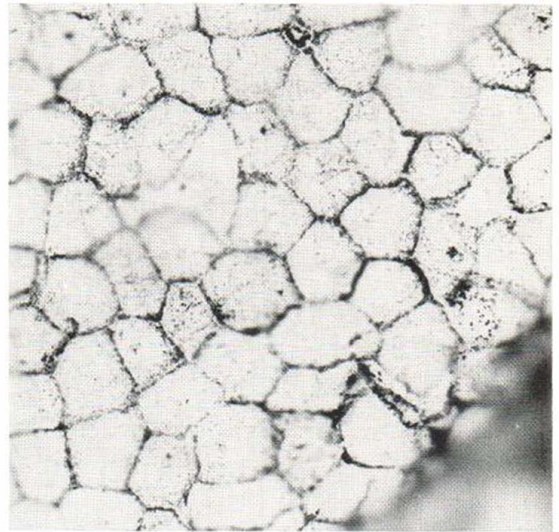


Fig. 10. Indian male aged 20. Photomicrograph of skin surface biopsy from forearm of Indian subject stained with silver nitrate to show melanin granules within the keratinocytes ($\times 85$).

small number of subjects investigated, but clearly it would be of interest and importance to know whether all individuals possessed similar skin surface patterning or whether certain individuals possessed hereditary differences. This and other applications of the skin surface biopsy method are now under investigation.

ACKNOWLEDGEMENTS

We are grateful to Mr B. Bhogul for invaluable technical assistance.

R. M. is in receipt of a grant from the Medical Research Council.

REFERENCES

1. Dawber, R. P. R., Marks, R. & Swift, J. A.: Scanning electron microscopy of the stratum corneum. *Brit J Derm* 1971. In press.
2. Guttman, L.: A demonstration of the study of sweat secretion by the Quinizarin method. *Proc Roy Soc Med* 35: 77, 1941.
3. Marks, R.: Histochemistry of the Stratum Corneum: Observations in the Horizontal Dimension. Paper read at British Association of Dermatology, Edinburgh, July 1971.
4. Marks, R. & Dawber, R. P. R.: Skin surface biopsy: An improved technique for the examination of the horny layer. *Brit J Derm* 84: 117, 1971.
5. — In situ Microbiology of the Stratum Corneum. Paper read at European Society for Dermatological Research, Holland, April, 1971.
6. Moynahan, E. J. & Engel, C. E.: Photomacrography of the normal skin. *Med Biol Illustr* 12: 72, 1962.
7. Sarkany, I.: A method for studying the microtopography of the skin. *Brit J Derm* 74: 254, 1962.

Received September 9, 1971

R. Marks, M.D.
The Institute of Dermatology
St. John's Hospital for Diseases of the Skin
Lisle Street
Leicester Square
London, WC2H 7BJ
England