

DEGENERATION OF DERMAL ELASTIC FIBRES IN RELATION TO AGE AND LIGHT-EXPOSURE

Preliminary Report on Electron Microscopic Studies

Lis Danielsen and Takasi Kobayasi

*From the University of Copenhagen Department of Dermatology, Rigshospital, Copenhagen,
Denmark*

Abstract. Specimens from slightly sun-exposed or unexposed skin of children and adults of different ages, and from chronically sun-exposed skin of adults, were examined. Normal figures of the elastic fibres were seen in the children's skin. The slightly exposed or unexposed skin of adults showed changes of some elastic fibres in the dermis. The changes were slight in young adults and moderate in elderly individuals. The chronically exposed adult skin showed changes of the same type as in the unexposed skin, but they were far more pronounced in the outer part of the dermis than in the unexposed skin. The lesions of the elastic fibres were (i) masses of dense grains, and (ii) round holes in the matrix of the elastic fibres. Both were arranged in lines along the axis of the fibres. The holes contained (a) granular material, (b) thin banded rings, (c) round electron-dense bodies, (d) myelin figures, or (e) thin filaments with knobs. Elastic fibrils were absent or very scarce inside the holes. The chronically exposed adult skin showed minor alterations of collagen, possibly secondary to the alterations of elastic fibres. The lesions of the elastic fibres are interpreted as degeneration. These changes seemed to be related to age as well as to light-exposure.

were taken from the abdominal region of four individuals aged 1-2 years and four aged 24-74 years, one biopsy from the skin of the back of one individual aged 10 months. Ten biopsies were taken from the axillary region of ten individuals aged 19-92 years, four biopsies from the antecubital region of four aged 29-41 years, three biopsies from the extensor surface of the upper arm of three individuals aged 39-41 years, and four biopsies from the sacral region of four aged 21 to 73 years. The biopsied areas were not, or only slightly influenced by sunlight. In addition five biopsies were taken from the back of the neck of five individuals aged 68-84 years and two from the side of the neck of two persons aged 68 and 70 years. Throughout life the areas of the neck had been influenced by sunlight.

The biopsies from children were taken from the skin around urticaria pigmentosa papules. Clinically, the biopsied area of the back of the neck of adult persons showed cutis rhomboidalis nuchae. The remaining material was biopsied from areas appearing normal or slightly atrophic. These individuals were healthy or suffering from localized skin diseases.

Only slight structural changes of ageing dermal elastic fibres have been described previously (1, 15, 17). The appearance of so-called elastotic fibres in sun-exposed skin has been related to chronic actinic irradiation rather than to age (12, 16, 19). Elastotic fibres have been described as changes in elastic fibres (1, 4), changes in collagen fibres (18) or as a result of changes of both collagen and elastic fibres (17).

MATERIAL

The material consists of 37 biopsies from 30 individuals of both sexes aged 10 months to 92 years. Eight biopsies

METHODS

The specimens were fixed in a 6% glutaraldehyde solution with 7.5% sucrose, buffered at pH 7.4 with 0.1 mol Veronal acetate buffer, for 1 hour at 4°C. For afterfixation 1% osmic acid solution in 0.1 M Veronal acetate buffer at pH 7.4 was used. After stepwise dehydration in increasing concentrations of ethanol, the specimens were embedded in epoxy resin, and ultrathin sections were cut by a Reichert OM 2 ultramicrotome. The sections were stained by a combined technique using uranyl acetate and lead citrate and studied by an electron microscope (Siemens Elmiskop 1A.) operated at 80 kV with double condensers.

Some biopsies were used for light microscopic study and stained with Alizarin Red S for demonstration of calcium.

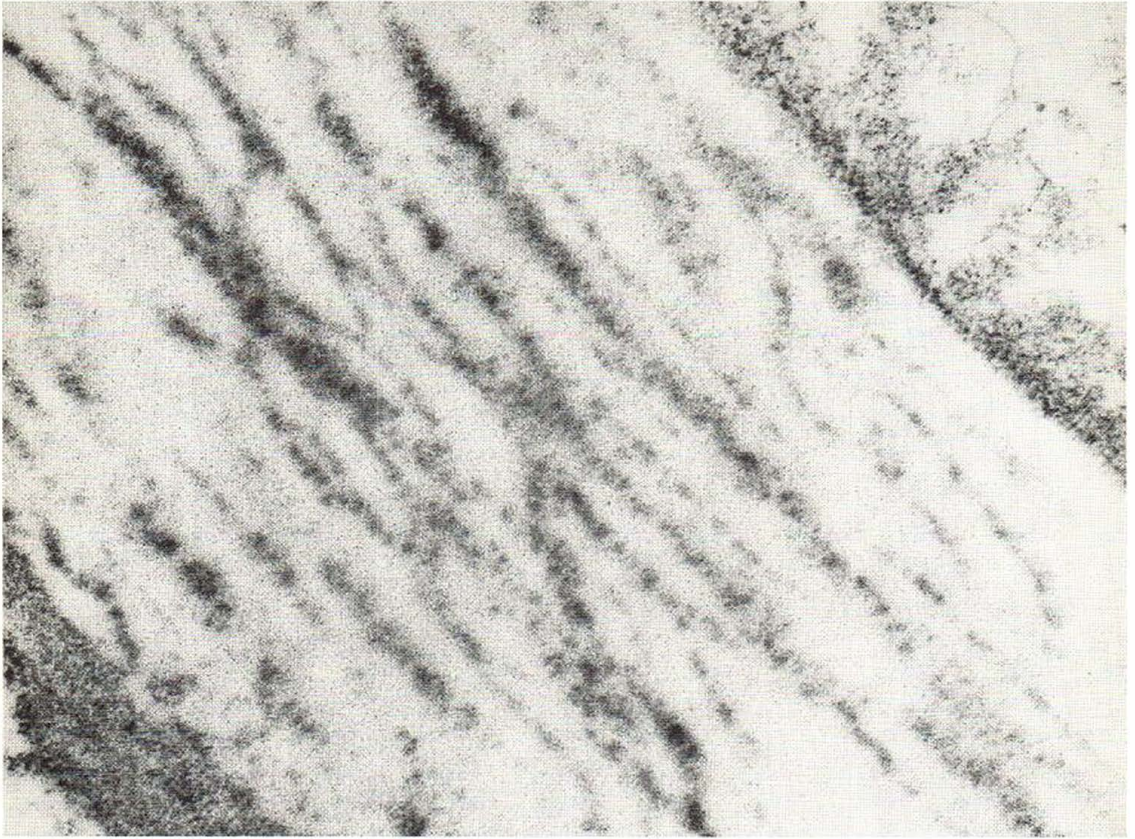


Fig. 1. Elastic fibre showing homogeneous matrix and masses of dense grains in lines along the axis of the fibre. Armpit of an 84-year-old individual. $\times 56\ 000$.

OBSERVATIONS

Normal figures of the elastic fibres were seen in the children's skin. The fibres showed homogeneous matrix and distinct fibrils. The slightly exposed or unexposed skin of adults showed changes of some elastic fibres in the dermis. The changes were slight in young adults and moderate in elderly individuals. The chronically exposed adult skin showed changes of the same type as in the unexposed skin, but they were far more pronounced in the outer part of the dermis than in the unexposed skin, particularly in skin of the back of the neck. The lesions of the elastic fibres were (i) masses of dense grains (Figs. 1 and 2), and (ii) round holes in the matrix of the elastic fibres (Figs. 3 and 4), both arranged in lines along the axis of the fibres. The holes contained (a) granular material (Figs. 4, 5 and 6), (b) thin

banded rings (Fig. 5), (c) round, electron-dense bodies (Figs. 7 and 8), (d) myelin figures (Figs. 5 and 9) or (e) thin filaments with knobs (Fig. 4). Elastic fibrils were absent or very scarce inside the holes (Figs. 3, 4 and 5). The dense grains now and then surrounded round holes. The holes were often confluent, forming oblong lakes (Figs. 4 and 5). Occasionally, the granular material inside the holes contained pieces of homogeneous matrix. The dense bodies were composed of granules or thin needles, the latter simulating calcium apatite crystals (Figs. 7 and 8). The granules were either evenly distributed, arranged like concentric rings with a dark or lucent centre, or radially arranged (Fig. 7). The needles were observed in radial or in random arrangements (Figs. 7 and 8). The myelin figures showed a lamellar structure and appeared either as round uniform figures or as

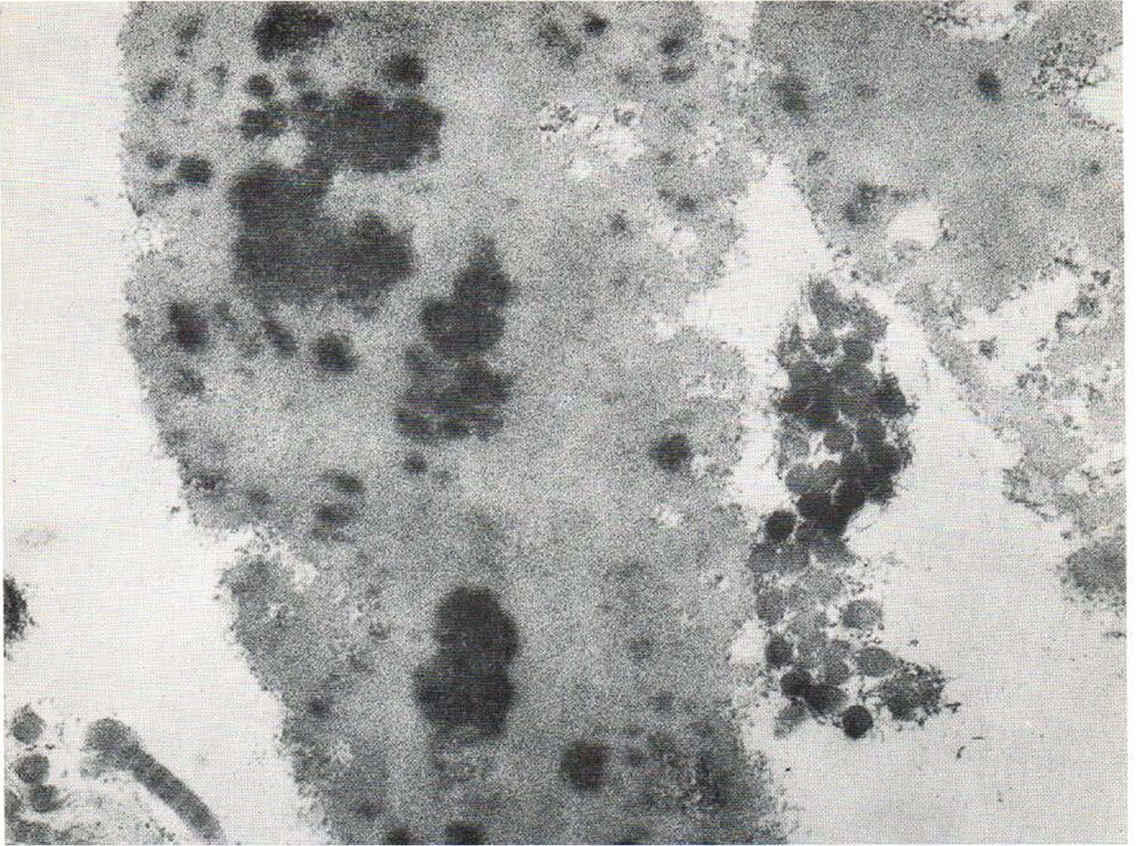


Fig. 2. Elastic fibre showing homogeneous matrix and masses of dense grains partly in lines along the axis of

the fibre. Back of the neck of an 84-year-old individual. $\times 56\,000$.

annular or irregular figures with a lucent centre or enclosing granular material (Figs. 5 and 9). The most severely altered elastic fibres, observed in the chronically exposed skin, were extremely widened containing many large holes and only thin strips of matrix (Fig. 4). In some fibres all the holes were filled up with granular material (Fig. 6). Some strips of matrix presented a fine granular structure (Fig. 4), and some fibres consisted mainly of granular material with strips of matrix in the periphery. Now and then these granular fibres contained lines of dense grains. Occasionally, a light granular material confluent with the intra-fibrous granular material was observed in the extra-fibrous space (Fig. 6).

In chronically exposed skin collagen fibrils were rare and occasionally seen gathering in clumps surrounded by wide elastic fibres and apparently compressed by these (Fig. 10). Another change

consisting of increased diameter and twisting of collagen fibrils was observed in the unexposed skin (Fig. 11). One child and five of the adult persons showed few altered collagen fibrils, while two of the adults showed many collagen fibrils changed. The cut-surface was flower-like with a normal round collagen fibril in the centre and an irregular periphery apparently split into subunits. In the longitudinal sections, wire-like figures appeared twisted along the axis of the fibrils.

Histochemical stainings for calcium salts were negative.

DISCUSSION

The elastic fibres in the children's skin were identical with the normal elastic fibres previously described by Kobayasi (13). The lesions of the elastic fibres of adult skin are interpreted as de-

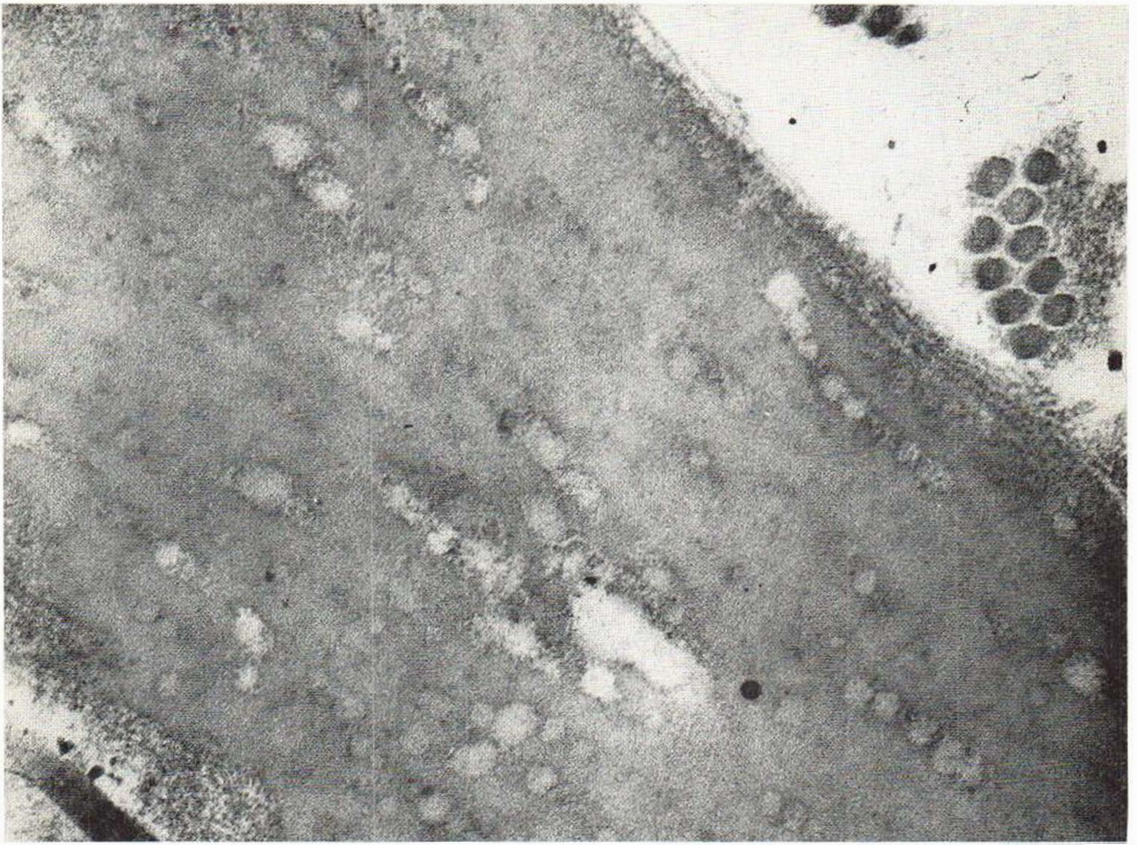


Fig. 3. Elastic fibre showing round holes in the matrix in lines along the axis of the fibre. No elastic fibrils are

seen in the holes. Armpit of an 80-year-old individual. $\times 56\ 000$.

generation of the fibres. The findings of wide elastic fibres with linear masses of dense grains, holes and lighter granular material and with disappearance of elastic fibrils correspond to earlier findings in exposed skin (1). In aged skin an "increased density of the elastic fibrils" has been reported (1). The question whether the dense grains represent altered elastic fibrils, as posed by some authors (1, 4, 17) is, however, unanswered. The holes probably represent defects of the matrix after disintegration. The circular outline of the spaces suggests that a liquid is formed inside the elastic fibres. This liquid might well cause the pronounced widening of the fibres observed in the chronically exposed skin. The granular material inside the holes is presumably degenerated elastic matrix since areas of homogeneous matrix were observed inside areas of granular material. The origin of the extra-fibrous

granular material has hitherto been unknown. The thin banded rings, dense round bodies, myelin figures and thin filaments with knobs inside degenerated elastic fibres of the skin have not previously been reported. The origin of the thin banded rings is unknown. The dense bodies possibly represent accumulations of calcium salts, the amount of which may well be too little for histochemical detection. Similar bodies in human aged (11, 20) and arteriosclerotic (21) aortae were interpreted as calcification. A different type of calcification showing thin needles or granules located in the normal elastic fibre matrix and forming large uniform areas or areas with bizarre patterns has previously been observed in skin lesions of pseudoxanthoma elasticum (6) and in arteriosclerosis (8). It seems likely that the difference between the round bodies observed in the present study and the calcification observed in pseudo-

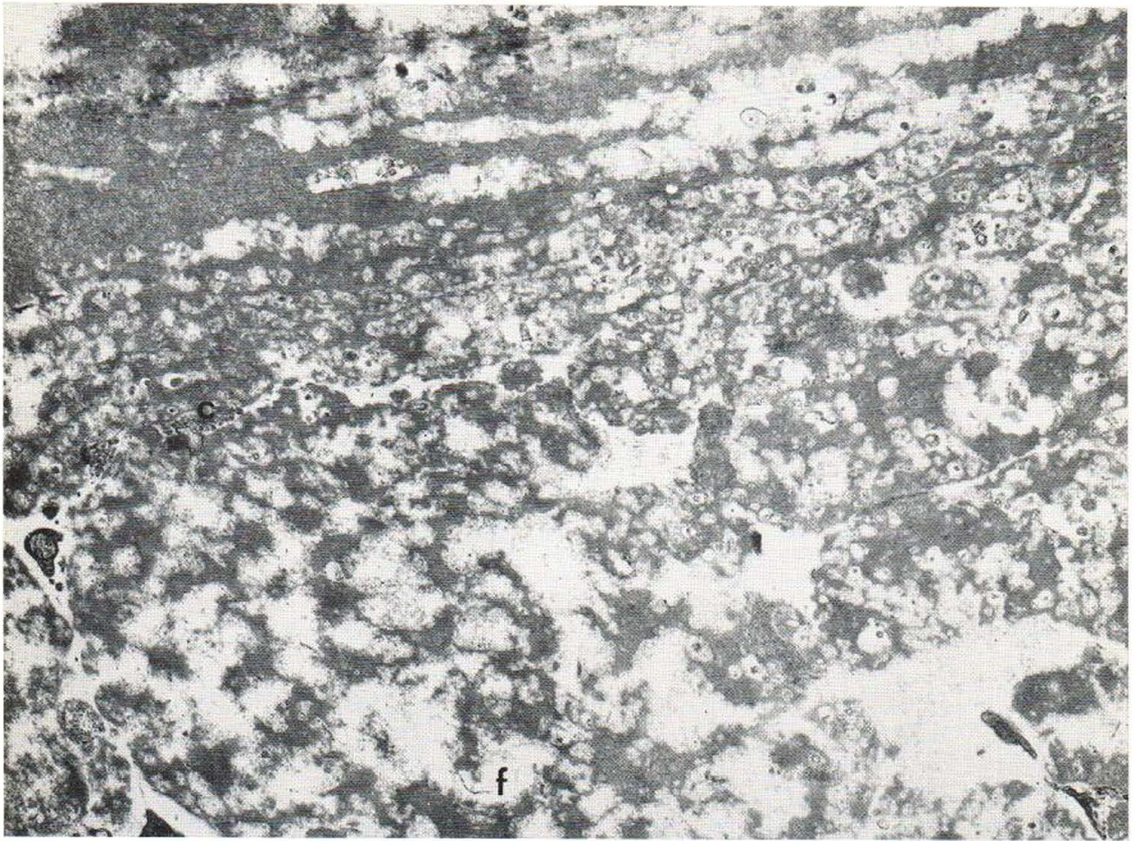


Fig. 4. Distended elastic fibres with many round holes and oblong lakes partly in lines along the axis of the fibres. Only strips of matrix remain. Light granular material, filaments with knobs (*f*) and several other

figures, but no elastic fibrils are seen inside the holes. Very few collagen fibrils (*c*) are seen. Back of the neck of an 84-year-old individual. $\times 16\ 700$.

xanthoma elasticum may be related to the presence or the absence of degeneration inside the elastic fibres. The "myelin figures" are believed to represent phospholipids (10). The filaments with knobs which have been found around elastic fibres in normal skin probably represent an aggregation of molecules of glycosaminoglycans (14). A degeneration of the elastic fibres similar to that described above has been observed in gastric vessels of adult persons (7). The holes with granular material inside masses of elastic tissue in dermatofibrosis lenticularis disseminata reported by Danielsen et al. (5) are similar to those observed in the present study inside the elastic fibres of adult skin. The banded rings and the myelin figures observed inside a thready material in pseudoxanthoma elasticum (6) are also similar to

those observed inside the elastic fibres in the present study.

The clumping and the reduction of the amount of collagen fibrils in heavily exposed skin is thought to be secondary to the changes of elastic fibres. Severe alterations of collagen fibrils in exposed skin have been reported by some authors (3, 17, 18), whereas we found only minor alterations of collagen. The occasional finding of increased diameter and twisting of collagen fibrils in the skin could neither be related to any particular age, nor to exposure. The twistings were similar to those found in large numbers in the skin lesions of pseudoxanthoma elasticum (6). A similar helical organization of unit filaments within collagen fibrils of rat aorta has been demonstrated using "inert dehydration" and hydroxy-

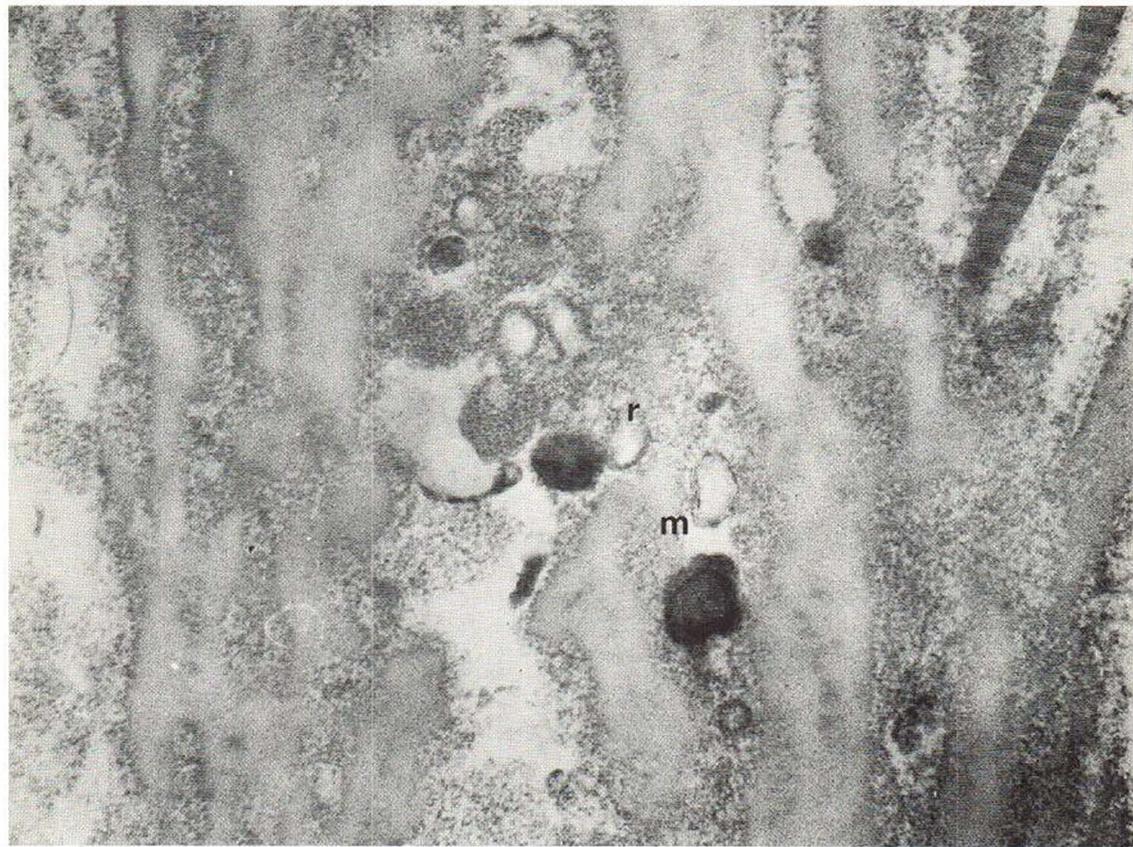


Fig. 5. Elastic fibre showing lakes containing light granular material, thin banded rings (*r*) and "myelin figures" (*m*).

No elastic fibrils are seen in the lakes. Armpit of a 92-year-old individual. $\times 56\ 000$.

propyl methacrylate embedding of the tissue (2). The considerations in the present study are in disagreement with the suggestion of Ebner (9) of a cellular formation of abnormal proteins in exposed skin.

The changes of elastic fibres found in the present study seemed to be related to age as well as to exposure to light. Further studies are needed, however, to demonstrate the influence of either of these factors.

ACKNOWLEDGEMENTS

The authors wish to thank Mrs Nancy Hansen, Miss Lise Fredebo and Mr John Winther for their valuable technical assistance.

REFERENCES

1. Banfield, W. G. & Brindley, D. C.: Preliminary observations on senile elastosis using the electron microscope. *J Invest Derm* 41: 9, 1963.

2. Bouteille, M. & Pease, D. C.: The tridimensional structure of native collagenous fibrils, their proteinaceous filaments. *J Ultrastruct Res* 35: 314, 1971.
3. Braun-Falco, O.: Die Morphogenese der senil-aktinischen Elastose. Eine elektronenmikroskopische Untersuchung. *Arch Klin Exp Derm* 235: 138, 1969.
4. Constantine, V. S. & Hartley, M. W.: Collagen and elastic fibers in normal dermis and severe actinic (senile) elastosis. A light and electron microscopic study. *Ala J Med Sci* 3: 329, 1966.
5. Danielsen, L., Midtgaard, K. & Christensen, H. E.: Osteopoikilosis associated with dermatofibrosis lenticularis disseminata. *Acta Derm (Chicago)* 100: 465, 1969.
6. Danielsen, L., Kobayasi, T., Larsen, H.-W., Midtgaard, K. & Christensen, H. E.: Pseudoxanthoma elasticum. A clinico-pathological study. *Acta Dermatovener (Stockholm)* 50: 355, 1970.
7. Danielsen, L. & Kobayasi, T.: A light and electron microscopic study of gastric arteries in patients with and without pseudoxanthoma elasticum. To be published.
8. — The ultrastructure of calcification in different conditions of the skin and arteries. To be published.

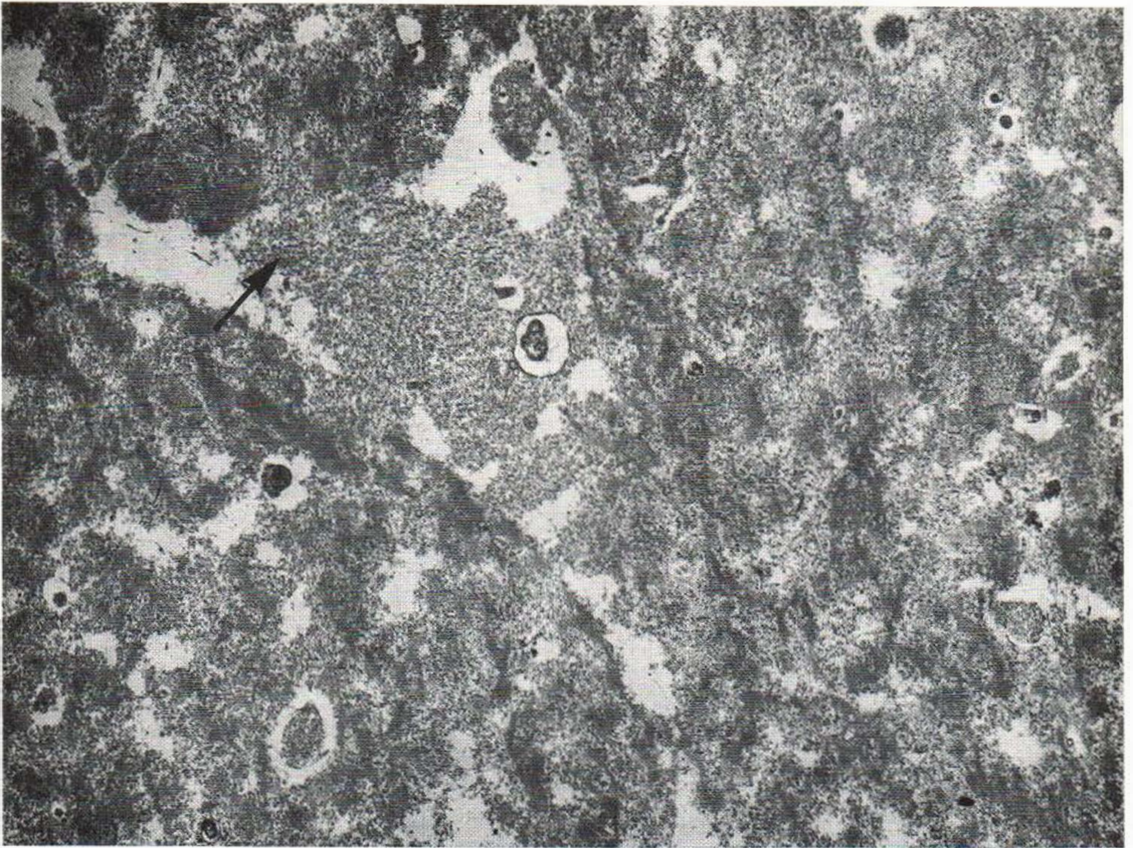


Fig. 6. Broad elastic fibres showing almost all holes filled up with light granular material. A granular material (arrow) confluent with the intra-fibrous granular material

is seen in the extra-fibrous space. Back of the neck of an 84-year-old individual. $\times 12\,600$.

9. Ebner, H.: Über die Entstehung des elastischen Materials. Eine elektronmikroskopische Studie. *Z Haut Geschlechtskr* 44: 889, 1969.
10. Finean, J. B.: Electron microscope and X-ray diffraction studies of a saturated synthetic phospholipide. *J Biophys Biochem Cytol* 6: 123, 1959.
11. Gardner, M. B. & Blankenhorn, D. H.: Aortic medial calcification. An ultrastructural study. *Arch Path* 85: 397, 1968.
12. Hill, W. R. & Montgomery, H.: Regional changes and changes caused by age in the normal skin. A histologic study. *J Invest Derm* 3: 231, 1940.
13. Kobayasi, T.: Electron microscopy of the elastic fibers and the dermal membrane in normal human skin. *Acta Dermatovener (Stockholm)* 48: 303, 1968.
14. Kobayasi, T., Danielsen, L. & Asboe-Hansen, G.: Hyaluronate(?) microfibrils in human dermis. *Acta Dermatovener (Stockholm)* 51: 27, 1971.
15. Ma, C. K. & Cowdry, E. V.: Aging of elastic tissue in human skin. *J Geront* 5: 203, 1950.
16. Marshall, D. R.: The clinical and pathological effects of prolonged solar exposure. I. The association with ageing of the skin. *Austr N Z J Surg* 34: 161, 1965.
17. Mitchell, R. E.: Chronic solar dermatosis: A light and electron microscopic study of the dermis. *J Invest Derm* 48: 203, 1967.
18. Niebauer, G. & Stockinger, L.: Über die senile Elastosis. Histochemische und elektronenmikroskopische Untersuchungen. *Arch Klin Exp Derm* 221: 122, 1965.
19. Smith, J. G., Jr & Lansing, A. I.: Distribution of solar elastosis (senile elastosis) in the skin. *J Geront* 14: 496, 1959.
20. Yu, S. Y. & Blumenthal, H. T.: The calcification of elastic fibers. II. Ultramicroscopic characteristics. *J Geront* 18: 127, 1963.
21. — The calcification of elastic fiber. III. Various crystalline structures of apatite in human aortae. *Lab Invest* 12¹¹: 1154, 1963.

Received July 6, 1971

L. Danielsen, M.D.
 Department of Dermatology
 Rigshospital
 Blegdamsvej 9
 2100 Copenhagen Ø
 Denmark

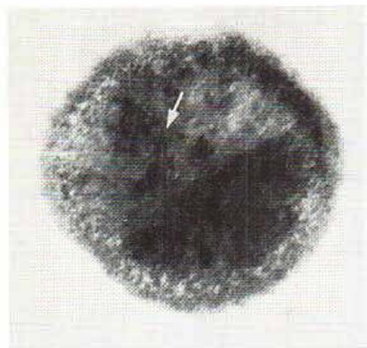


Fig. 7. Dense round body showing granules and needles (arrow) in annular and radial arrangements. Armpit of a 92-year-old individual. $\times 120\ 000$.

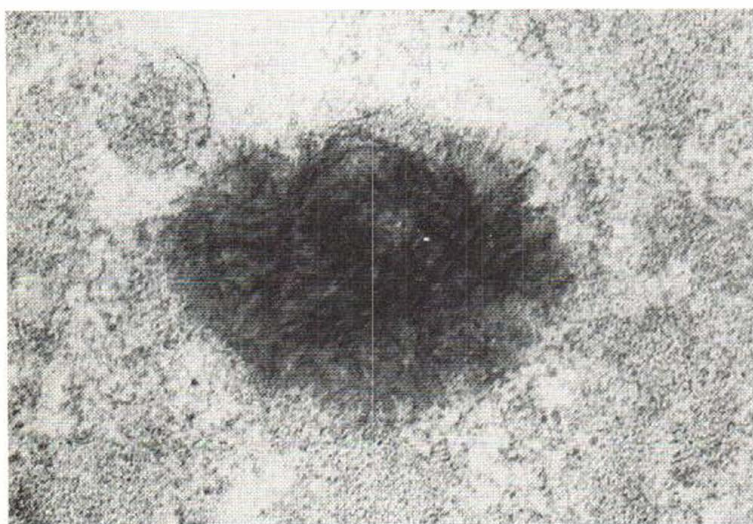


Fig. 8. Dense round body showing needles in random arrangement. Back of the neck of a 70-year-old individual. $\times 120\ 000$.

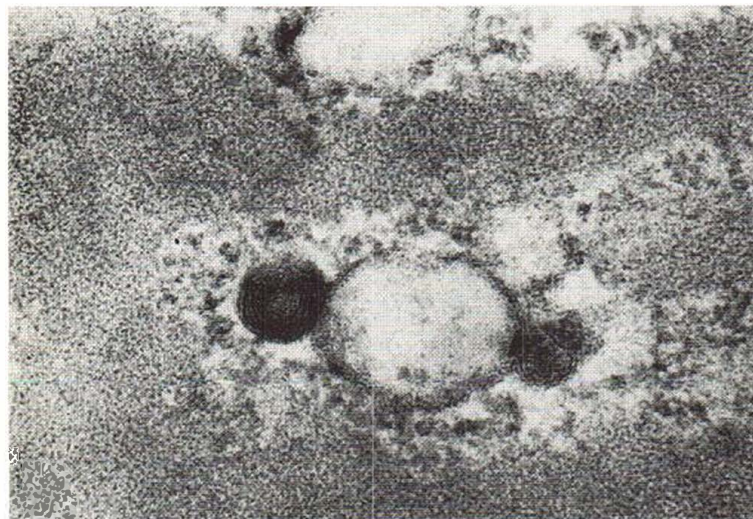


Fig. 9. "Myelin figures" appearing as round uniform and annular lesions showing a lamellar structure. Back of the neck of an 84-year-old individual. $\times 120\ 000$.

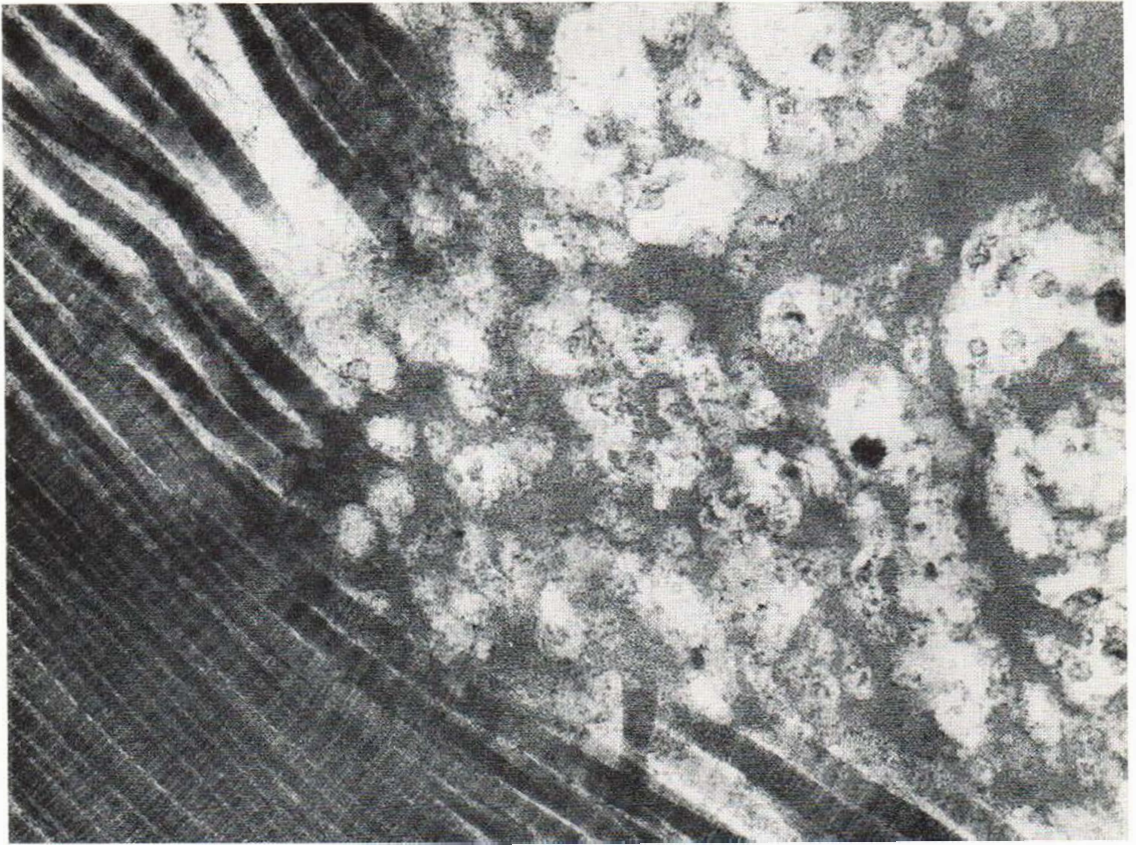


Fig. 10. A bundle of collagen fibrils seemingly forced together by a wide elastic fibre. Back of the neck of an 84-year-old individual. $\times 56\ 000$.

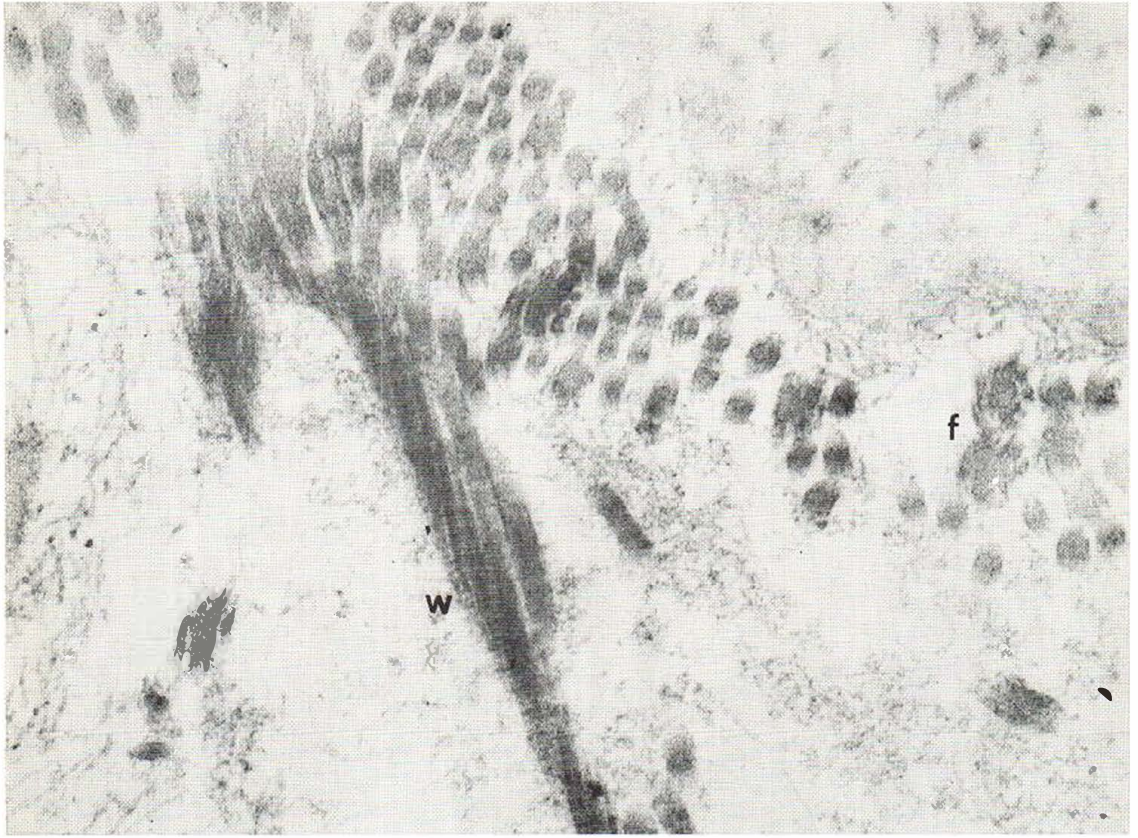


Fig. 11. Twisted collagen fibrils showing flower-like shape (f) in cross section, and wire-like figure (w) in longitudinal section. The antecubital region of a 29-year-old individual. $\times 56\ 000$.