

## BASAL CELL CARCINOMA IN GARDNER'S SYNDROME<sup>1</sup>

R. J. Lewis and J. C. Mitchell

*From the Sub-Department of Dermatology, The Vancouver General Hospital, Vancouver, British Columbia, Canada*

**Abstract.** Two brothers with intestinal polyposis, osteomas and epidermoid cysts (features of Gardner's syndrome) presented basal cell carcinomas at the age of 44 years. These carcinomas were probably induced by actinic exposure but the occurrence of basal cell carcinomas as a late development in the natural history of this syndrome cannot be discounted.

The main features of the syndrome described by Gardner and his associates consist of multiple osteomas, fibrous and fatty tumours of the skin and mesentery, epidermoid inclusion cysts of the skin, leiomyomas, odontomas and multiple intestinal polyposis with malignant change (1).

Here, basal cell carcinomas are reported in two members of a family showing Gardner's syndrome (Fig. 1, 13 and 9).

### CASE REPORTS

#### 1. *Propositus* (Fig. 1.13)

A white male, aged 46 years, noted rectal bleeding at age 24 years and a colectomy and ileosigmoidostomy was performed for multiple intestinal polyposis. At age 37 years ileoproctostomy was performed. Subsequently polyps in the rectum were fulgurated at yearly intervals. At age 44 years, an epidermoid cyst was excised from the right upper arm and three basal cell carcinomas were excised from the upper back.

Later in the patient's 44th year, a superficial basal cell carcinoma, 1.5 cm diam., of the skin of the right forehead and an actinic keratosis of the left cheek were treated by curettage and electrosurgery. At age 46 years, an ulcero-nodular basal cell carcinoma, 1.0 cm diam., of the skin of the right forehead, at a site distinct from the previous carcinoma, and actinic keratoses of the right and left sides of the nose were treated by curettage and electrosurgery. Six epidermoid cysts were presented on the trunk and one had been removed from the dorsum of the left hand. Three osteomas were present on the frontal skull.

<sup>1</sup> Presented to the Pacific Northwest Dermatological Society, May 22, 1970, Harrison Hot Springs, B.C., Canada.

The patient had blue eyes, medium brown hair and a fair, not freckled skin. Actinic atrophy (senile elastosis) was not evident clinically. He was a self-employed contractor exposed to sun during the course of his occupation. His hobbies exposed him to sun to a 'moderate' degree. He had resided in British Columbia since birth.

#### 2. *A brother of the propositus* (Fig. 1.9)

A white male, aged 54 years, underwent colectomy for intestinal polyposis at age 38 years. At age 44 years, basal cell carcinomas were excised from the skin of the cheek and shoulder. Actinic keratoses appeared later on the facial skin. Osteomas were present on the frontal skull and fibromas and epidermoid cysts were present on the skin.

The two patients were not accustomed to vacation outside British Columbia.

### DISCUSSION

The association, in these two patients, of osteomas of the skull, epidermoid cysts of the skin and polyposis of the colon, together with the family history, appears sufficient to make a diagnosis of Gardner's syndrome (3). A total of seven basal cell carcinomas appearing for the first time in the two brothers when each was aged 44 years may be coincidental or also a part of the syndrome.

The occurrence of basal cell carcinomas in residents of British Columbia in their fifth decade is unusual, unless they have spent part of their lives in sunnier climates.

Trichoepitheliomas (1) and squamous cell carcinoma of the skin of the trunk (4) have each been reported in a single case of Gardner's syndrome. The absence of other reports of skin cancer in the syndrome would seem to suggest a coincidence of skin cancer in our cases.

However, Gorlin (2) commented "The infrequency with which the syndrome is reported does

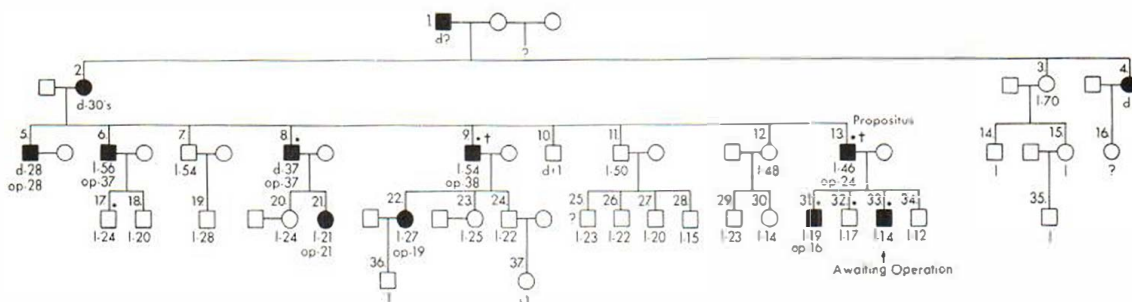


Fig. 1. Intestinal polyposis. ■, Male affected; □, male unaffected; ●, female affected; ○, female unaffected; \*, epidermoid cysts (incomplete history except for propositus

and family); ?, not known if affected or unaffected (16 and 25); †, basal cell carcinoma; d, died; l, living; op, operated.

not, in the author's opinion, reflect its true incidence. Incomplete physical examination, the attempt at brevity in case reports and the purposeful deletion from scientific papers of what appear to be incidental findings are factors which may be responsible for their failure to be reported".

The occurrence of basal cell carcinomas and of actinic keratoses in these two patients on the customary areas of actinic exposure, viz. face and upper back, speaks for a coincidence of skin cancer and Gardner's syndrome. A third possibility requires consideration, namely that the presence of Gardner's syndrome may predispose to an earlier occurrence of the type of basal cell carcinoma which is induced by actinic exposure in genetically predisposed individuals.

The life expectancy of untreated cases is usually less than 40 years. Possibly, basal cell carcinoma may be a late manifestation which will be observed more frequently in the future, as more of these patients are recognized and treated definitively so that their life span approaches the norm.

The syndrome is transmitted as an autosomal dominant trait with rather marked penetrance and variable expressivity and appears to be, fundamentally, a heritable disorder of connective tissue. The occurrence of a connective tissue disorder, as predisposing to basal cell carcinoma, would be of special interest in respect to the pathogenesis of such carcinomas.

The pattern of inheritance in this family is consistent with an autosomal dominant trait with marked penetrance. Number 10 (Fig. 1) died in infancy of post WW I influenza and may be excluded from this genetic survey. Five of the other eight siblings including the propositus were

affected with intestinal polyposis. Also, it appears that the grandfather (Fig. 1.1) of the propositus fathered five additional children by a second wife; two are said to have died of intestinal polyposis and one is alive following colectomy. Potentially, a more extensive investigation can be carried out.

The available evidence suggests to us that such skin cancer is coincidental with Gardner's syndrome but the occurrence of basal cell carcinoma as a late development in the natural history of the syndrome cannot be discounted with certainty.

#### ACKNOWLEDGEMENTS

Support was received from The British Columbia Dermatology Foundation.

Dr W. H. Sutherland referred the Propositus. Dr J. R. Miller gave advice on genetics.

#### REFERENCES

- Gardner, E. J.: Follow-up study of family group exhibiting dominant inheritance for syndrome including intestinal polyps, osteomas, fibromas and epidermal cysts. *Amer J Hum Genet* 14: 376, 1962.
- Gorlin, R. J. & Pindborg, J. J.: *Syndromes of the Head and Neck*, p. 410. Toronto, 1964.
- Thomas, K. E., Watne, A. L., Johnson, J. G., Roth, E. & Zimmermann, B.: Natural history of Gardner's syndrome. *Amer J Surg* 115: 218, 1968.
- Turner, F. P.: Familial polyposis of the large intestine. *Ann Surg* 146: 131, 1957.

Received June 15, 1970

J. C. Mitchell, M.D.  
Department of Dermatology  
The Vancouver General Hospital  
Vancouver 9, B.C.,  
Canada