

THE ASSOCIATION OF GENERALIZED GRANULOMA ANNULARE WITH ANTITHYROID ANTIBODIES

Paul R. Gross and Walter B. Shelley

From the Department of Dermatology, Pennsylvania Hospital and University of Pennsylvania School of Medicine, Philadelphia, Pa, USA

Abstract. Two patients with generalized granuloma annulare were found to have circulating antibodies to thyroglobulin. One had a definite past history of thyroiditis. Both had lesions only on light-exposed areas and both showed dramatic improvement on chloroquin.

Generalized granuloma annulare is a distinctly rare condition. Its etiology is unknown. The recent observation that 2 patients with this condition have circulating anti-thyroid antibodies seems worthy of documentation.

CASE REPORTS

Case 1

A 57-year-old white female was admitted to the Hospital of the University of Pennsylvania with a 9 month history of an eruption on her arms, legs and chest. She had been vacationing in Miami, Florida, and shortly after returning to her home in New Jersey, she had developed an upper respiratory infection. This was treated with tetracycline and cough syrup by her family physician. Approximately 10 days later, she noted the sudden onset of a papular rash on her right forearm. This was interpreted at first as urticaria, although the lesions were not pruritic. She was given an injection of steroid without improvement. The eruption persisted and slowly spread to involve both arms, legs and the upper chest. She stated that new lesions appeared rather suddenly and were at first papular, but would coalesce and flatten out. Treatment with lubricating baths, topical steroids and antihistamines had been ineffectual.

Her past history was significant in that 13 years earlier she had had a partial thyroidectomy for thyroiditis. She had been taking thyroglobulin (Proloid®). Review of systems was otherwise negative except for frequent attacks of post-prandial upper abdominal burning and migraine headaches.

On physical examination, there were hyperpigmented plaques on the dorsal aspects of both hands. These lesions had atrophic centers and slightly elevated serpiginous

borders. Over the back, shoulder, breasts, thighs, and neck there were multiple annular elevated lesions which were flesh-colored or pink (Fig. 1). No lesions were noted on areas of the trunk that would be covered by a bathing suit. Physical examination was otherwise normal except for the presence of a thyroidectomy scar.

Routine laboratory results were within normal limits, including CBC, BUN, creatinine, alkaline phosphatase, calcium, phosphate, and Kolmer test. The serum protein electrophoresis was normal. The PBI was 4.3 $\mu\text{g}\%$. The fasting blood sugar was 64 mg%. Urinalysis was within normal limits. X-ray examination of the chest was within normal limits. An upper G.I. series revealed displacement of the cervical esophagus at the thoracic inlet due to a thyroid nodule on the left. A moderate-sized hiatal hernia was noted. Gall bladder X-rays were normal.

Skin tests for deep fungi were negative. The old tuberculin skin test was positive at 48 hours.

A skin biopsy was performed on the right breast. This was interpreted by Dr Herman Beerman as granuloma annulare (Fig. 2).

Skin testing was done with a hot quartz lamp. The minimal erythema dose was determined, and an eight MED dose was delivered to the back. She developed erythema but no lesions suggestive of granuloma annulare. Three hundred roentgen of grenz radiation was administered to lesions on the left posterior shoulder, but without demonstrable effect.

A serum specimen was tested for anti-thyroid antibodies. This was positive on both agglutination and complement fixation testing, both at titers of 1:5.

In view of her history of thyroiditis, and because she had been taking a thyroid medication (Proloid®) which contained thyroglobulin, it was felt that an auto-immune process might be responsible for her skin problems. Therefore, she was advised to discontinue the thyroglobulin and to use pure tri-iodo-thyronine (Cytomel®). In addition, chloroquin was also prescribed in a dose of 250 mg twice daily for 1 week, then once daily. One month later there was definite improvement in the condition of her skin, and within 4 more weeks there was virtually complete involution. Six weeks later she discontinued the Cytomel® because she felt it caused her to have headaches. She resumed Proloid®. Although she was not

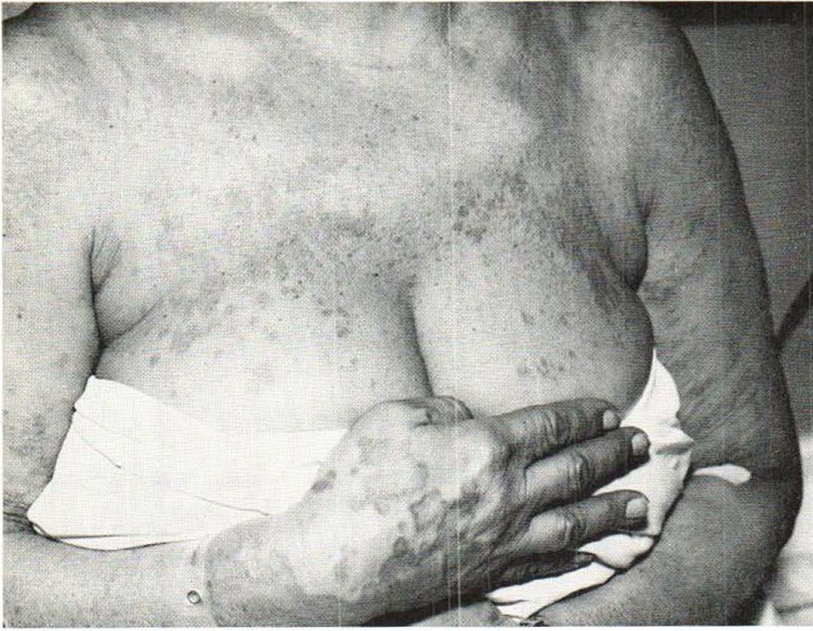

Fig. 1. Fifty-seven-year-old patient (case one) with papular and plaque-like lesions of granuloma annulare confined to light-exposed portions of the body.

examined at that time, she reported that the eruption reappeared suddenly. She then stopped the Prolid[®] and the rash involuted. She never resumed the Prolid[®]. The chloroquin was later reduced to a dosage of 250 mg every second day. When last seen, 2 months later, the patient's skin was absolutely clear.

Case 2

This 52-year-old white female presented with a slightly pruritic symmetrical rash of 3 months duration. It had

begun on both arms simultaneously and subsequently spread to both legs. Originally it was thought to be urticarial, but treatment with antihistamines had been unsuccessful. She was still developing new lesions at the time of her initial examination. She denied any other history of skin disease or allergies.

She had had hypothyroidism for 5 years with an initial PBI of 1.3 μ g%. She had been taking tri-iodo-thyronine (Cytomel[®]) and occasionally aspirin, but denied other medications.

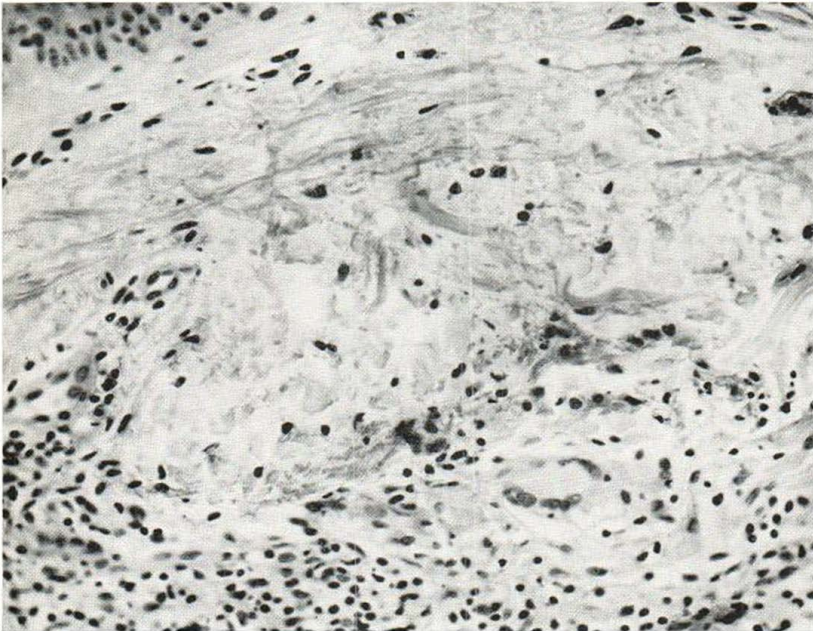


Fig. 2. Histologic appearance of a lesion on the breast (case one). There is a focal area of necrobiosis of collagen with an infiltrate of histiocytes and lymphocytes at the periphery. Occasional foreign body type giant cells are noted. Hale-stained sections were positive for mucin.

Examination revealed indurated erythematous plaques on the arms and legs. Most of these lesions showed an elevated, serpiginous border with central clearing. There were also smaller, papular lesions.

The remainder of the physical examination was within normal limits. Chest X-ray and EKG were normal. Laboratory values including CBC, urinalysis, sedimentation rate, calcium, phosphate, fasting blood glucose, BUN, uric acid, cholesterol, total protein and serum protein electrophoresis, creatinine, alkaline phosphatase, LDH, and SGOT were within normal limits. The glucose tolerance test revealed a fasting blood sugar of 80 mg%; at one-half hour it was 110; at 1 hour, 108; 2 hours, 68; and at 3 hours, 36 mg%. She reported fatigue in the later portion of the test which she also claimed to have at home in the late morning and late afternoon. This symptom was relieved by food. This was considered to represent reactive hypoglycemia.

Anti-thyroid (thyroglobulin) antibodies were present in a titre greater than 1:20 by slide agglutination technique. PPD, intermediate strength, was positive. Skin biopsy confirmed the clinical impression of granuloma annulare.

Topical steroid creams under occlusion, and intralesional injections of steroid suspension were without effect. The patient was begun on chloroquin, 250 mg, twice daily for 1 week, then reduced to 250 mg once daily. Within 2 weeks there was a marked improvement in the clinical appearance of the eruption. The chloroquin was stopped, and there has been no relapse during the subsequent 3 months.

DISCUSSION

Though the etiology of generalized granuloma annulare is unknown, recent reports have suggested an association with diabetes mellitus (2, 3). The diabetic status was not fully evaluated in the first patient, but her fasting blood sugar was normal (64 mg%). The second patient had had a glucose tolerance test 2 years previously which was entirely normal. At the present time her tolerance study showed a reactive hypoglycemia with a 3 hour level of 36 mg%. Approximately 30% of such patients will eventually develop diabetes (6).

Photosensitivity has also been invoked as a cause of this disease (5, 7), and possibly it did play a role in our cases. Both patients had lesions limited to the light-exposed portions of their body. Moreover, in the first patient, the onset of the eruption was subsequent to intense sun exposure during a Florida vacation. Finally, chloroquin, long a standby in the treatment of photosensitivity states (lupus erythematosus, polymorphous light eruption), was effective in both patients.

The intriguing aspect of these cases is the finding of circulating anti-thyroid antibodies, an as-

sociation which to our knowledge has not been recognized previously. Our first patient had a definite history of thyroiditis. She had been taking thyroglobulin for replacement therapy, and it was against this fraction that her serum antibodies were directed. Switching this patient to a pure tri-iodo-thyronine preparation was associated with clinical improvement in her skin, though the other treatments she was receiving could also explain her improvement. More suggestive, however, was her report of an exacerbation upon resumption of Prolid®. The second patient, whose titre was even higher (1:20) was already on Cytomel at the time her eruption developed. She has never taken Prolid, but it is probable that sometime in the past, she had received desiccated thyroid.

At this time, one can only speculate on a possible relationship between granuloma annulare and the anti-thyroid antibodies. These antibodies are a serologic sign of thyroiditis occurring in only 1.2% of normal individuals (1). The specificity of the test is remarkable in that even those cases labeled "false positive" may actually show evidence of thyroiditis on pathologic examination (4). Hence, it is likely that both our patients had thyroiditis, although we have histologic confirmation in only one. One might hypothesize that an antigen-antibody reaction is occurring in the dermis. However, frozen sections of skin from the lesions of the second patient, incubated with fluorescein-conjugated anti-human globulin, failed to reveal any binding in the affected areas of the dermis.

It is unlikely that the hypothyroid state itself is related to generalized granuloma annulare, since both these patients were euthyroid, clinically and by laboratory evaluation, at the time their eruption developed. Furthermore, granuloma annulare is not a concomitant of myxedema.

REFERENCES

1. Anderson, J. R., Buchanan, W. W., Goudie, R. B. & Gray, K. G.: Diagnostic tests for thyroid antibodies. *J Clin. Path* 15: 462, 1962.
2. Dicken, C. H., Carrington, S. G. & Winkelmann, R. K.: Generalized granuloma annulare. *Arch Derm* (Chicago) 99: 556, 1969.
3. Rhodes, E. L., Hill, D. M., Ames, A. C., Tourle, C. A. & Taylor, C. G.: Granuloma Annulare: Prednisone glycosuria glycosuria tests in a non-diabetic group. *Brit J Derm* 78: 532, 1966.

4. Rose, N. R. & Witebsky, E.: Thyroid autoantibodies in thyroid disease. *Advances in Metabolic Disorders* 3: 231, 1968.
5. Selmanowitz, V. J., Vandow, J. E. & Director, W.: Atypical granuloma annulare. *Arch Derm (Chicago)* 93: 454, 1966.
6. Seltzer, H. S., Fajans, S. S. & Conn, J. W.: Spontaneous hypoglycemia as an early manifestation of diabetes mellitus. *Diabetes* 5: 437, 1956.
7. Tolmach, J. A.: Disseminated granuloma annulare (atypical). *Arch Derm (Chicago)* 84: 167, 1961.

Received August 10, 1970

Walter B. Shelley, M.D.
Department of Dermatology
Hospital of the University of Pennsylvania
Duhring Laboratories Building
3400 Spruce Street
Philadelphia, Pa 19104
USA