

## SELENIUM SULPHIDE TREATMENT OF TINEA VERSICOLOR

Kjell Hersle

*From the Department of Dermatology, Lundby Medical Center, Gothenburg, Sweden*

**Abstract.** Sixty-four patients with tinea versicolor have been treated with selenium sulphide suspension (Selsun®—Abbott Laboratories, Chicago, Ill., USA) according to two different therapeutic schedules. Thirty-four patients were treated with a single overnight application and then regularly controlled for 1–2 years. Thirty patients had the same initial treatment but were retreated every third month for one year and any relapses were noted at regular controls for another year. The immediate treatment results were excellent. One month after the initial treatment only 2/64 had active lesions of tinea versicolor left. The long-term recurrence rate after one single treatment was high, however. The frequency of relapses in the first year was 53% and after 2 years 82% of the cases had relapsed. The intermittent treatment had a more lasting effect. The frequency of relapses was 14% during the treatment-year and only 20% the next year. It seems likely, therefore, that an intermittent suppressive treatment has a more lasting effect on the transformation of the yeast-like *Pityrosporon orbiculare* to its more pathogenic mycelial phase with clinical signs of tinea versicolor.

Selenium sulphide thus is a most effective remedy for tinea versicolor but the treatment has to be repeated three to four times at least every third month.

Tinea versicolor is defined as a mild, chronic, mostly symptomless fungus infection of the stratum corneum caused by the yeast-like *Malassezia furfur*, which results in the production of discrete or conrescent scaly, discoloured or depigmented areas principally on the chest, back, abdomen and upper limbs (15). *Malassezia furfur*, the cause of tinea versicolor, is present in infected scales as short, fat hyphal elements and as clusters of rounded budding spores. Culture has yielded the yeast-like *Pityrosporon orbiculare* (7). Evidence of the identity of *P. orbiculare* and *M. furfur* now seems convincing (2, 8, 10, 13, 16). Most forms of therapy listed in the standard texts, i.e. salicylic acid, sulphur ointment and 10–20% aqueous sodium hyposulphite, require frequent applications for several weeks, often with poor or tran-

sient results. Selenium sulphide has been used in the treatment of tinea versicolor since 1953 (4), but treatment procedures are varied (5, 11, 14) and follow-up studies of the effect are scanty. Albright et al. reported in 1966 (1) good initial treatment results after a single overnight treatment with 2.5% selenium disulphide suspension but an increasing number of relapses in a follow-up study.

The aim of the present study is to report on the immediate results and a follow-up study of 64 patients treated with 2.5% selenium disulphide suspension (Selsun®), according to two different therapeutic schedules. The patients in one group were treated with a single overnight application of selenium disulphide suspension and then controlled clinically and mycologically at regular intervals for at least 1 year. The patients in another group had the same initial treatment but were then retreated every third month for 1 year and then controlled regularly, in most cases for another year.

### MATERIAL AND METHODS

A total of 64 patients were treated. Thirty-four patients comprised group A and the other 30 group B. All patients were from the Dermatological Outpatient Clinic at Lundby Medical Center, Gothenburg. There were 36 women and 28 men. Thirty-two patients had received different treatments earlier but had not been treated with selenium sulphide. Besides the clinical examination the diagnoses were verified by microscopical examination of scales (Methylene blue stained KOH-preparations) and at the follow-up controls Wood's light was also used as it is known that subclinical lesions exist which are visible only under Wood's light (3).

The treatment procedure was as follows: At night the selenium sulphide suspension was generously applied to the affected skin and to about 20 cm of the surrounding normal-looking skin. The genital region was avoided to

Table I. Follow-up periods and relapses of single treatment (A) or intermittent treatment (B) with selenium sulphide of tinea versicolor

	No. of cases	Cases free of tinea versicolor (mo.)				Number of relapses (mo.)			
		0-6	7-12	13-18	19-24	0-6	7-12	13-18	19-24
Single treatment (A)	30	30	24	14	6	6	10	5	3
Intermittent treatment (B)	29	29	28	25	20	1	3	4	1

prevent any irritation. The suspension dried and caused no discomfort during the night. The treatment time was at least 8 hours and the suspension was then washed away.

The patients in group A were not allowed to treat themselves again and after this only treatment they were regularly controlled after intervals of about 1, 3, 6, and 12 months and then twice during the next year (clinical examination, Wood's light, microscopical examination). For practical reasons some of the patients were interviewed by phone and if they suspected a relapse they were at once examined at the clinic.

The patients in group B were treated every third month during the first year and were then regularly controlled,

as described above, and any relapses were noted. In most cases the follow-up period was 18-24 months.

## RESULTS

One month after the initial treatment only 2/64 had active lesions of tinea versicolor. The 62 patients free of tinea versicolor were controlled according to the methods outlined above. Two patients in group A and 1 patient in group B did not return for control examinations and thus the total number of patients was 59 (A = 30; B = 29). The number of relapses and the follow-up periods in the two groups A and B are summarized in Table I. As can be seen from the table almost all patients were followed for at least 1 year. The total number of relapses in group A were 24 and in group B there were 9. Fig. 1 shows the frequency of relapses after different follow-up periods. In group A there was a relapse frequency of 53% during the first year after treatment and in group B with the intermittent treatment there was a relapse frequency of 14%. The intermittent treatment was stopped after 1 year but there was still a low frequency of relapse during the second year (20%). The total frequency of relapse 2 years after the trial began was 82% in group A vs. 31% in group B. Of the 32 patients who had received different kinds of treatment earlier, 26 thought the selenium sulphide treatment superior. Some patients with tinea versicolor of many years duration were quite enthusiastic about this simple treatment procedure.

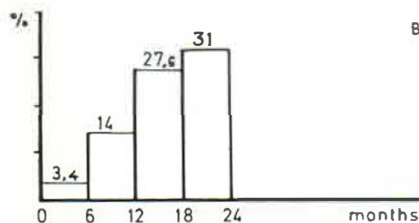
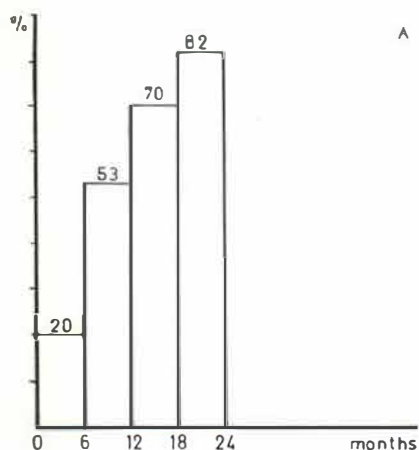


Fig. 1. Frequency of relapse (%) after different follow-up periods. (A) Single treatment; (B) intermittent treatment.

## DISCUSSION

The investigation has confirmed earlier reports of the immediate excellent treatment results with

the single application of selenium sulphide (1). However, the long-term recurrence rate is high. Treatment with selenium sulphide must therefore be repeated in most patients. That selenium sulphide treatment has only a suppressive effect in many patients is in accordance with recent studies, where it is shown that the mycelial elements disappear but that the yeast-like forms of *Pityrosporon orbiculare* merely give a lower colony mean count (12). The supposed transformation from yeast to mycelial phase can then once again take place if the host is in a suitable condition for this, i.e. has a constitutional susceptibility and lives in a suitable climate.

The frequency of relapse during the post-treatment year after the single treatment was 53% compared with only 20% (5 relapses) in group B, where the patients were treated intermittently the year before. It seems likely, therefore, that an intermittent suppressive treatment has a more lasting effect on the transformation of the yeast-like *Pityrosporon orbiculare* to its more pathogenic mycelial phase.

No patient in the present series manifested any skin irritation. The genital region was avoided, as it appears reasonable to assume that prolonged contact with the detergent included in the suspension may cause some skin irritation (1). The risk of intoxication with selenium sulphide by this mode of application is negligible as the sulphide was found to possess a very low toxicity, according to a recent report (9). This is in contrast to the toxic effects of the soluble selenium compounds (6) on the gastrointestinal tract, the nervous and the respiratory system.

#### REFERENCES

- Albright, S. D., Hitch, J. M. & Hill, C.: Rapid treatment of tinea versicolor with selenium sulfide. *Arch Derm (Chicago)* 93: 460, 1966.
- Burke, R. C.: Tinea versicolor: Susceptibility factors and experimental infection in human beings. *J Invest Derm* 36: 389, 1961.
- Conant, N. F., Smith, D. T., Baker, R. D., Callaway, J. L. & Martin, D. S.: *Manual of Clinical Mycology*, ed. 2. Saunders, Philadelphia & London, 1954.
- Dumery, P. R.: Le Sélénium, agent antimycosique. *Presse Med* 61: 1646, 1953.
- Giordano, W. C.: One application treatment for tinea versicolor. *J Med Soc New Jersey* 60: 186, 1963.
- Goodman, L. S. & Gilman, A.: *The Pharmacological Basis of Therapeutics*, 3rd ed., p. 984. Macmillan, New York, 1965.
- Gordon, M. A.: The lipophilic microflora of the skin. *Mycologica* 43: 524, 1951.
- Lipophilic yeast-like organisms associated with tinea versicolor. *J Invest Derm* 17: 267, 1969.
- Henschler, D. & Kirschner, U.: Zur Resorption und Toxizität von Selensulfid. *Arch Toxikol* 24: 341, 1969.
- Keddie, F. M.: Electron microscopy of *Malassezia furfur* in tinea versicolor. *Sabouraudia* 5: 134, 1966.
- Levan, N. E.: Selenium sulfide suspension in the treatment of tinea versicolor. *Arch Derm (Chicago)* 75: 128, 1957.
- McGinley, K. J., Lantis, L. R. & Marples, R. R.: Microbiology of tinea versicolor. *Arch Derm (Chicago)* 102: 168, 1970.
- Roberts, S. O. B.: Pityriasis versicolor: A clinical and mycological investigation. *Brit J Derm* 81: 315, 1969.
- Robinson, H. M., Jr & Yaffe, S. N.: Selenium sulfide in treatment of pityriasis versicolor. *JAMA* 162: 113, 1956.
- Rook, A., Wilkinson, D. S. & Ebling, F. J. G.: *Textbook of Dermatology*. Oxford, 1968.
- Sternberg, T. H. & Keddie, F. M.: Immunofluorescent studies in tinea versicolor. *Arch Derm (Chicago)* 84: 999, 1961.

Received May 12, 1971

Kjell Hersle, M.D.  
Department of Dermatology  
Lundby Medical Center  
S-417 17 Gothenburg  
Sweden