

LOCALIZATION OF WART VIRUS ANTIGEN IN HUMAN PLANTAR WARTS (VERRUCAE VULGARES)

J. Genner

From the Institute for Medical Microbiology, University of Copenhagen, and the Department of Dermatology, The Finsen Institute, Copenhagen, Denmark

Abstract. Antibodies against wart virus were obtained from rabbits and guinea-pigs immunized with crude homogenates from selected plantar warts. Warts were studied by fluorescence microscopy as frozen sections using either the direct or indirect fluorescent antibody technique. Specific intranuclear fluorescence corresponding to the basophilic inclusion body was demonstrated. Specific fluorescence was marked with the animals' hyperimmune sera in the direct technique but fainter with the patients' sera in the indirect technique.

Warts were the first animal tumours to be transmitted experimentally. Ciuffo in 1907 (8) demonstrated in cell-free homogenates of warts an ultrafiltrable agent capable of producing new warts, when inoculated into the skin of human volunteers; experiments with homologous transmission of warts by inoculation of crude extracts of warts were already successful in 1893 (24).

The virus was isolated in microcrystalline form by Strauss et al. in 1949 (21), the first animal virus to be isolated in this way. Wart virus is placed in the Papova virus group (14). This virus is shaped like an icosahedron with a diameter of 530 Å and contains 42 capsomeres.

Only homologous transmission has been carried out (9) and only three microbiologists have obtained the virus in culture (15, 18, 19). The report of Mendelson & Kligman (15) was the only one which fulfilled the Henle-Koch criteria.

The purpose of the present study was to raise antibodies against wart virus in laboratory animals and then use the sera to visualize the virus antigen in biopsy specimens by fluorescence microscopy.

MATERIALS AND METHODS

Biopsy material employed

A total of 76 plantar warts (common warts) were removed under sterile precautions by curettage; half of

each was routinely examined in hematoxylin and eosin stained sections, whilst the remainder was stored in the deep-freeze at -70°C after immediate freezing in dry ice. Storage in equal parts of glycerol and isotonic saline at $+4^{\circ}\text{C}$ was also used. Material from solitary, untreated plantar warts which had been present for 8 ± 4 months was selected from the immunization procedures. This material should contain most virus (3).

"Inclusion warts" (*Myrmecia*) according to the criteria established by Lyell & Miles (12) were especially valuable and elected on evidence of "activity" of the disease: edema, tenderness, redness and hemorrhage of the wart following microtraumata. Inclusion warts were also used in particular to show the presence of elementary bodies and fluorescent antigen.

Epidermis from normal skin biopsy specimens and hyperkeratoses from patients without plantar warts were used as control antigens.

Antigens used for the immunization of laboratory animals

Warts, skin biopsies and hyperkeratoses were all treated in the same way. The specimens were rapidly thawed in a water-bath at $+37^{\circ}\text{C}$, minced by means of knife and scissors, washed 2-3 times in phosphate-buffered saline (PBS) and then homogenized in a mortar with sand for at least 15 min, the aseptic precautions being maintained. The homogenates were 2-3 weight-volume per cent with respect to dry weight. The crude homogenate was decanted and centrifuged for 5 min at 1000 rpm and distributed in one-millilitre ampoules for storage at -70°C .

Sera and immunization procedure employed

(a) Serum samples from patients attending the clinic were obtained at the first visit and when they were controlled some weeks later.

(b) Hyperimmune sera from white, female rabbits and guinea-pigs, aged 6 months, were obtained from several groups of two animals; each animal received subcutaneous injections of 1.0 ml homogenate into the neck skin.

On first occasion, half-strength mixed with complete Freund adjuvant was used; on the following occasions, pure antigen. They were immunized four times, with a 1 month interval between the first two injections, thereafter at intervals of 3 weeks. Blood samples were drawn from the animals before the immunization and 1 week after each of the last three immunizations. After the final

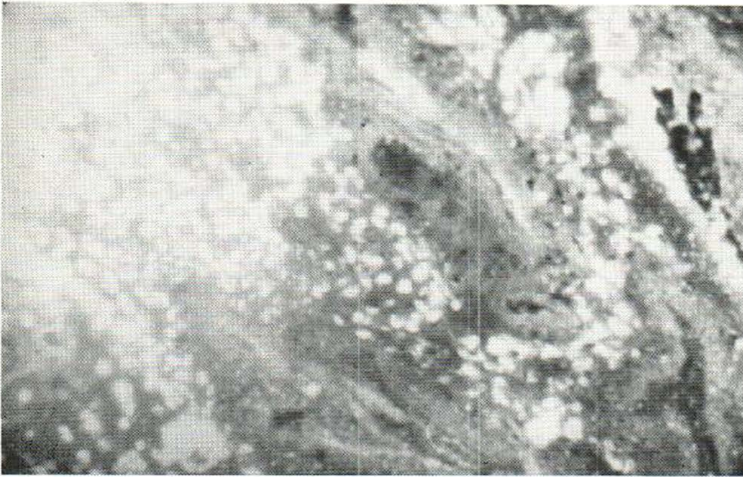


Fig. 1. Cryostat section of wart. $\times 100$. Nuclei containing viral antigen. Stained with FITC-conjugated rabbit-anti-wart-virus serum.

injection the animals were bled as much as possible without killing them.

The serum was stored at -20°C . Control sera consisted of the pre-inoculation sera from the experimental animals and sera from those animals immunized with control antigens.

Conjugation of hyper-immune sera with fluorescein isothiocyanate (FITC)

FITC (British Drug Houses) was used as fluorescent marker. The globulin fraction of serum obtained by precipitation of serum with equal parts of a saturated ammonium sulphate solution at neutral pH was dialyzed overnight against PBS. After dialysis the mixture was diluted with 0.9 per cent isotonic saline until the protein content was 1.0% and buffered with 1/10 volume of bicarbonate/carbonate buffer to a pH of 9.0 was reached. FITC (0.05 mg per mg of globulin) was added and stirring at $+4^{\circ}\text{C}$ continued overnight.

The concentrations of protein and FITC were estimated as OD_{280} and OD_{100} on a spectrophotometer, and plotted on a standard curve. The protein-bound FITC was separated from free FITC on a sephadex G-25 column with 30 ml bed volume per 5 ml serum. Elution at room temperature was carried out with 0.0067 M phosphate buffered saline. The first yellow fraction coming out was measured, pooled and stored at -20°C . It constituted the conjugate.

Preparation of cryostat sections

Serial sections of warts and normal skin, 5 μm thick, were placed on coverslips, washed 3–5 times in PBS and fixed in acetone for 30 min at -20°C , air dried and stained for 30 min at $+37^{\circ}\text{C}$ in a moist chamber with overlay of conjugate. After a final rinsing with PBS they were mounted in glycerol-saline (pH 9.0). All FITC-stained preparations were made employing the direct fluorescent antibody technique. A few sections were prepared according to the indirect method using overlay of fluorescent anti-human-gamma-globulin from goat (Baltimore Biological Laboratories).

The specificity was tested either after blocking with non-conjugated immune serum or by showing the un-specific staining of normal skin by the conjugate. The serial sections permitted comparison of the different immune sera and evaluation of their potency.

Microscopy and photography

A Leitz photomicroscope (Orthomat) equipped with a HB 200 high pressure mercury lamp and blue-green exciter filter BG 12 in connexion with K 53 barrier filter supplied the pictures on Kodak tri-x-pan 27°DIN and ectachrome HB-3 film. Routine microscopy was carried out at 100 and 400 times magnification.

Routine histology

The hematoxylin and eosin staining (HE) was performed according to a routine method.

RESULTS

The warts (HE staining) exhibited the typical histological structure including hyperkeratosis and parakeratosis and in some areas well-developed papillomatosis and parakeratosis, sometimes also acanthosis. The nuclei were enlarged and vacuolated, containing dark, granular, purple masses.

Inclusion bodies of the basophilic type were present in some of the modified nuclei, but these altered nuclei constituted only a minority of the total number of nuclei.

No fluorescence occurred in the connective tissue or in the germinative layer of Malpighii. The fluorescence was observed in stratum spinosum and corneum and—with maximal intensity—in the granular layer. The fluorescence was evidently nuclear and in parakeratotic areas one could distinguish the individual cells and nuclei and see

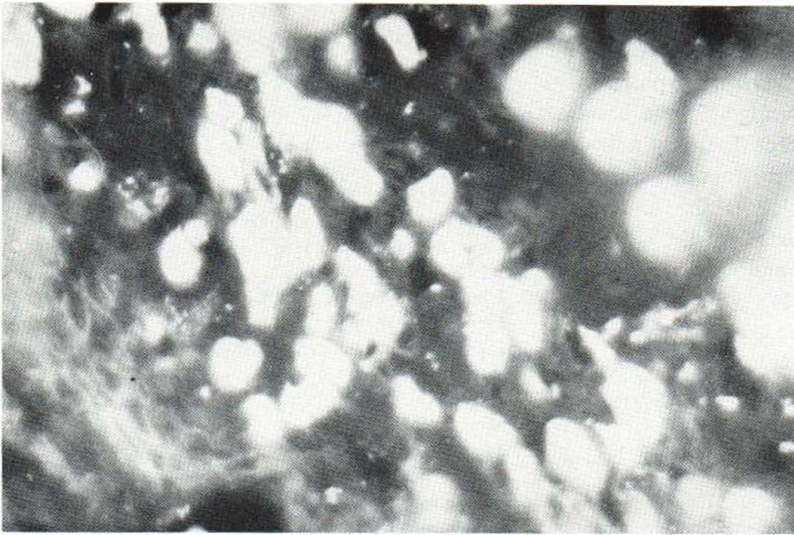


Fig. 2. Cryostat section of wart. $\times 400$. Fluorescence of nuclear material.

the extrusion of fluorescent antigenic material at the surface, while in other areas the nuclear and cellular remnants were intermingled to give a homogenous fluorescent layer. The technique did not permit a more detailed study of the cell nuclei, but the correlation between the intranuclear basophilia and the localization of the fluorescent antigen was evident.

Any relationships between nucleolus and fluorescent antigen could not be demonstrated, presumably because of the same technical difficulties.

"Inclusion warts" (12) showed a more pronounced, bright clear and green fluorescence than most usual warts. Warts with a history of over 18 months showed marked reduced fluorescence.

Fluorescence was characteristic and distinct in the 11 "inclusion warts" (total number of warts 76). Especially those warts with well-developed papillomatosis and pronounced "projections" (and herein localized parakeratosis) turned out to have a stronger and more wide-spread fluorescent antigenic zone than most warts. The usual wart has areas of focal activity where there is fluorescent antigen, but in much smaller quantities and with a weak fluorescence. Although clinically typical warts, they were not papillomatous and contained small areas with inclusion-bodies. The sparse fluorescence occurred in the superficial areas within the scaly remnants of nuclei.

Keratolytic therapy reduced the fluorescence only in the outer layers.

The indirect technique yielded sporadic results

and very faint staining. Only one clear positive result was obtained with serum from a patient showing spontaneous regression of all warts at the same time.

DISCUSSION

Homogenates of warts have been shown to contain virus particles (10, 13, 17, 18, 25). The preparative techniques have been the same as those employed in the present paper. The number of virus particles per wart seems to be maximal in warts with a history of 5–12 months as described by Barrera-Oro (3). This is confirmed here by the fact that proper fluorescence was seen only in warts with a history of less than 1 year. It is reasonable to assume that the fluorescent antigenic material is related to the virus. Fluorescence is observed in the nuclei, where the first changes can be seen and where the inclusion bodies later develop. Furthermore, direct agglutination of virus particles with hyperimmune serum has been observed in the electron microscope with antisera prepared in the same manner, whereby specific antigen-antibody binding is demonstrated (2, 19).

The specificity of the fluorescence is confirmed by the use of appropriate negative sera (animals preimmunization sera, conjugates of anti-skin and anti-hyperkeratoses), by the inhibition of reaction by prior application of non-conjugated immune sera (blocking test) and by the unspecific staining obtained when staining normal skin sections with wart-antisera.

The distribution of the antigen in the various layers of epidermis in the warts is in accordance with descriptions of rabbit and bovine papillomas (16, 20). The absence of viral antigen in the basal cells can be explained by the fact that only naked virus DNA and virus protein are found, whereas assembled virus particles, which is the antigen, are not. Or it can be due to coating of the antigen (masking) from extravasated antibody from the underlying capillary network (4). Obviously, differences in avidity of staining sera would give such a picture. But serial sections treated with different sera all had the same distribution of antigen, with nothing in the germinative layer.

Both eosinophilic and basophilic inclusion bodies have been described in nuclei and cytoplasm of the affected cells (1, 7). Lipschütz (11) and later Blank (5) reported on the occurrence of basophilic inclusion bodies. Lyell & Miles (12) reported about eosinophilic inclusions and Strauss et al. (22) described type B inclusion bodies in 1950. Bloch & Goodman (6, 13) have postulated an evolution cycle beginning with eosinophilic, Feulgen-negative nuclear inclusions which later develop into basophilic, Feulgen-positive inclusions.

The basophilic inclusions in the cell nuclei were highly refractile when viewed by phase contrast microscopy. Simultaneous observation in phase contrast and ultraviolet light proved that the fluorescent antigenic material was localized herein. This has not previously been demonstrated (23).

ACKNOWLEDGEMENT

The investigations were supported by grants from "Aage Bangs Fund".

REFERENCES

- Almeida, J. D.: Electron microscope study of human warts: sites of virus production and nature of the inclusion bodies. *J Invest Derm* 38: 337, 1962.
- The structure of antigen-antibody complexes. *J Exp Med* 118: 327, 1963.
- Barrera-Oro, J. G.: Quantitation of papova virus particles in human warts. *J Nat Cancer Inst* 29: 583, 1962.
- Beard, J. W.: The fallacy of the concept of virus "masking": A review. *Cancer Res* 16: 279, 1956.
- Blank, H.: The nature of the inclusion body of verruca vulgaris: a histochemical study of nucleotides. *J Invest Derm* 16: 19, 1951.
- Bloch, D. P. & Goodman, G. C.: A cytological and cytochemical investigation of the development of the viral papilloma of human skin. *J Exp Med* 105: 161, 1957.
- Bunting, H.: The cytology of skin papillomas that yield virus-like particles. *Amer J Path* 28: 985, 1952.
- Ciuffo, G.: Innesto positivo con filtrato di verruca volgare. *G Ital Mal ven e delle pelle* 48: 12, 1907.
- Freudenthal, W. & Spitzer, R.: Warzen und Kondylome. In: *Handb. d. Haut- und Geschlechtskrankheiten*. Bd. XII/3: 33, 1933.
- Klug, A. & Finch, J. T.: Structure of viruses of the papilloma-polyoma type. *J Mol Biol* 11: 403, 1965.
- Lipschütz, B.: Über Chlamydozoa-Strongyloplasmen. *Wiener Klin Wschr* 37: 286, 1924.
- Lyell, A. & Miles, J. A. R.: The myrmecia. *Brit J Med* 1: 912, 1951.
- Melnick, J. L.: Electron microscopy of viruses of human papilloma, molluscum contagiosum, and vaccinia, including observations on the formation of virus within the cell. *Ann NY Acad Sci* 54: 1214, 1952.
- Melnick, J. L.: Papova virus group. *Science* 135: 1128, 1962.
- Mendelson, C. G. & Kligman, A. M.: Isolation of wart virus in tissue culture. *Arch Derm (Chicago)* 83: 59, 1961.
- Noyes, W. F. & Mellors, R. C.: Fluorescent antibody detection of the antigens of the Shope papilloma virus in papillomas of the wild and domestic rabbit. *J Exp Med* 106: 555, 1957.
- Noyes, W. F.: Structure of the human wart virus. *Virology* 23: 65, 1964.
- Studies on the human wart virus. II. Changes in primary human cell cultures. *Virology* 25: 358, 1965.
- Oroszlan, S. & Rich, M. A.: Human wart virus: In vitro cultivation. *Science* 146: 531, 1964.
- Smithies, L. K. & Olson, C.: Antigen of bovine papilloma detected by fluorescent antibody. *Cancer Res* 21: 1557, 1961.
- Strauss, M. J.: "Crystalline" virus-like particles from skin papillomas characterized by intranuclear inclusion bodies. *Proc Soc Exp Biol (N.Y.)* 72: 46, 1949.
- Virus-like particles and inclusion bodies in skin papillomas. *J Invest Derm* 15: 433, 1950.
- Walter, E. L.: Localization of specific antigen in human warts. *Arch Path* 79: 419, 1965.
- Variot, G.: Un cas d'inoculation expérimentale des verrues de l'enfant à l'homme. *J Clin Thérap Infant* 2: 529, 1894.
- Williams, M. G.: Morphological characterization of the virus of the human common wart. *Nature* 189: 895, 1961.

Received November 23, 1970

J. Genner, M.D.
Aerenprivej 10
DK-2820 Gentofte
Denmark