

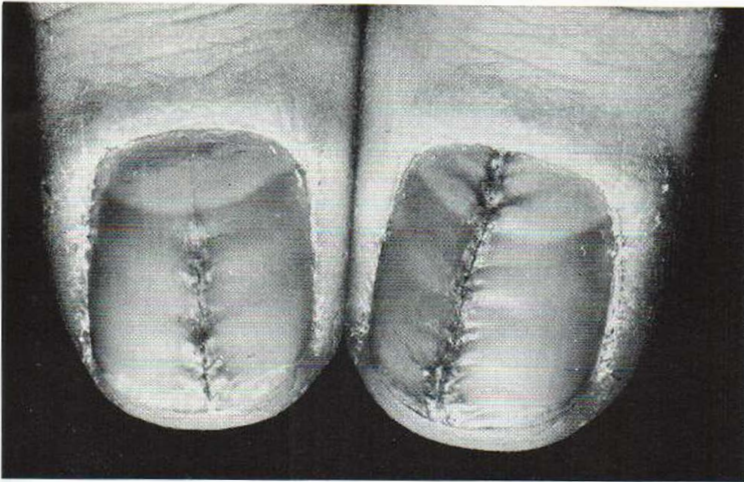Fig. 4. Dystrophia unguis mediana canaliformis.

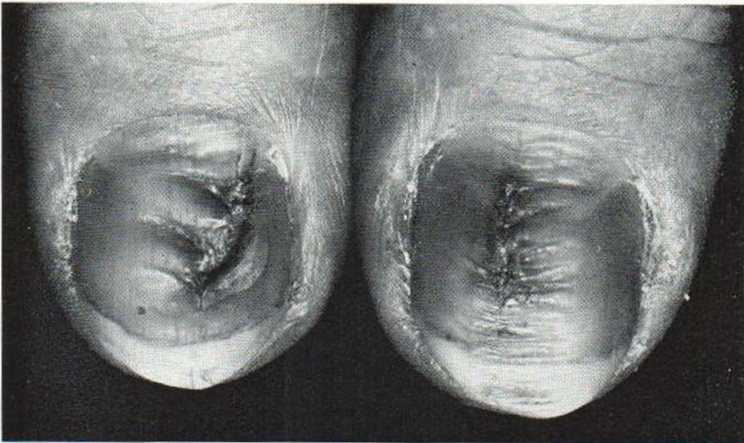


Fig. 5. Dystrophia unguis mediana canaliformis.

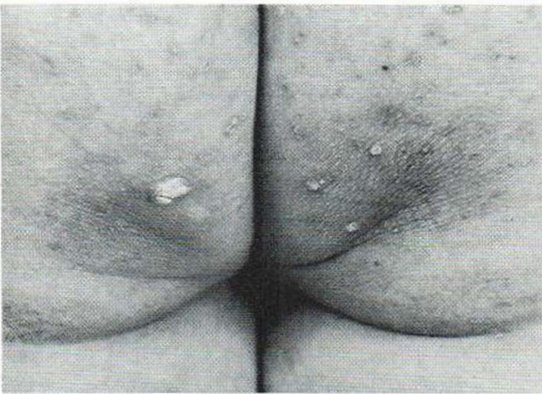


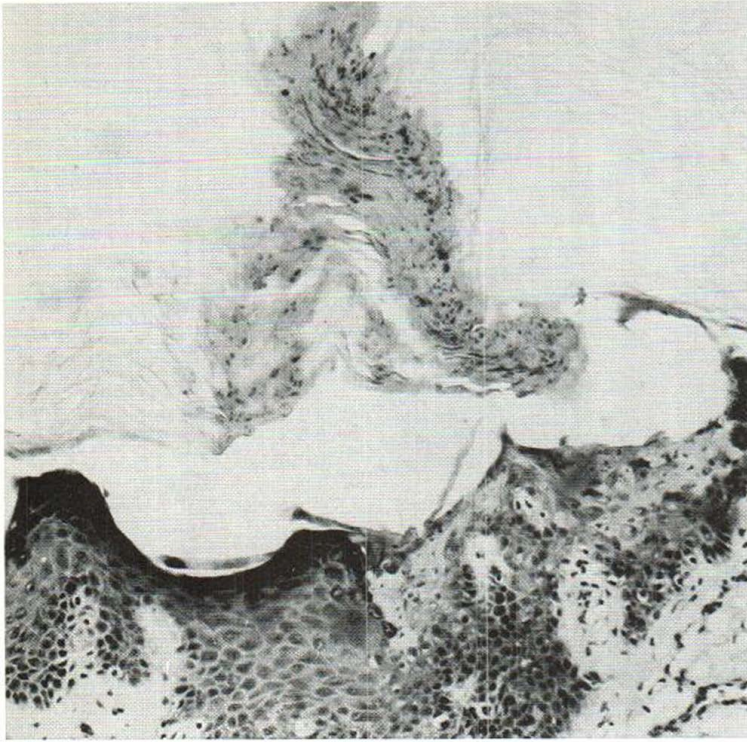
Fig. 6. Superficial disseminated eruptive form of Porokeratosis Mibelli.

### Superficial Disseminated Eruptive Form of Porokeratosis Mibelli on Nonactinic Skin Areas

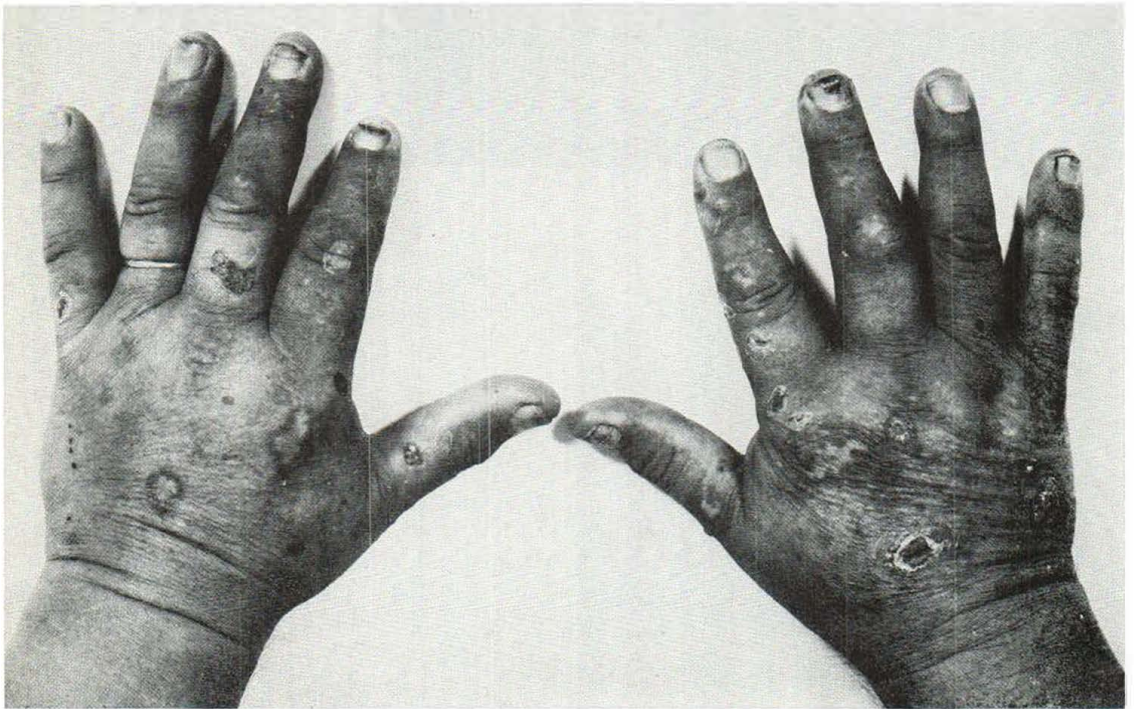
*Presented by Kirsti-Maria Niemi*

A 38-year-old female was affected with large ulcerations on the frontal sides of her legs and with thrombocytopenia. Due to earlier tuberculosis she had been administered antituberculous treatment together with cortisone. Scaling papules 2 to 5 mm in diameter covered with hard keratin appeared on the buttocks and the skin of the right wrist (Fig. 6).

*Histology:* Massive hyperkeratosis with separate vertical piles and lamellar plugs was seen in the



*Fig. 7. Superficial disseminated eruptive form of Porokeratosis Mibelli.*



*Fig. 8. Porphyria cutanea tarda due to colchicine.*




Fig. 9. Porphyria cutanea tarda due to colchicine.

section of the skin. The parakeratotic nuclei were seen as striae running in different directions. At the base of a plug the epidermis was thinned out and the stratum granulosum was broken (Fig. 7). The findings are compatible with Porokeratosis Mibelli.

#### Reference

Chernosky, M. E., & Freeman, R. J.: Disseminated superficial actinic Porokeratosis. *Arch Derm (Chicago)* 96: 611, 1967.

### Porphyria Cutanea Tarda Due to Colchicine in a Patient with Gout

*Presented by Kirsti Kuokkanen*

A 66-year-old man suffered from arthritis urica since 1967. The highest serum uric acid value

was 12.1 mg%. Since early spring 1968 the light-exposed areas—face, ear lobes and backs of hands (Fig. 8) were affected by a bullous dermatosis, which healed, leaving scars. With exposition tests it was demonstrated that colchicine, which the patient had been prescribed for his gout, was the causative agent of the dermatosis. Skin symptoms disappeared as the drug was expelled.

### Porphyria Cutanea Tarda Due to Colchicine in a Patient with Gout

*Presented by Kirsti Kuokkanen*

A 55-year-old man had for 20 years suffered from joint troubles diagnosed as arthritis urica. The brother of the patient also had gout. After commencing treatment with colchicine, small blis-