

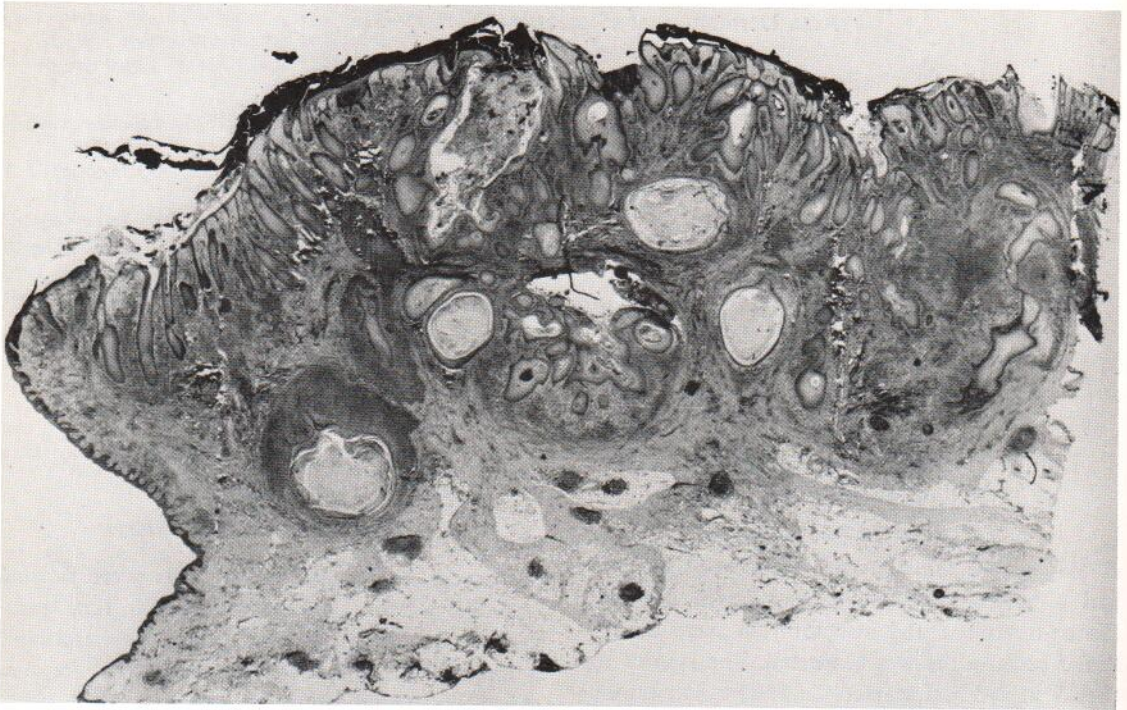Fig. 2. Lupus erythematosus hypertrophicus et profundus.

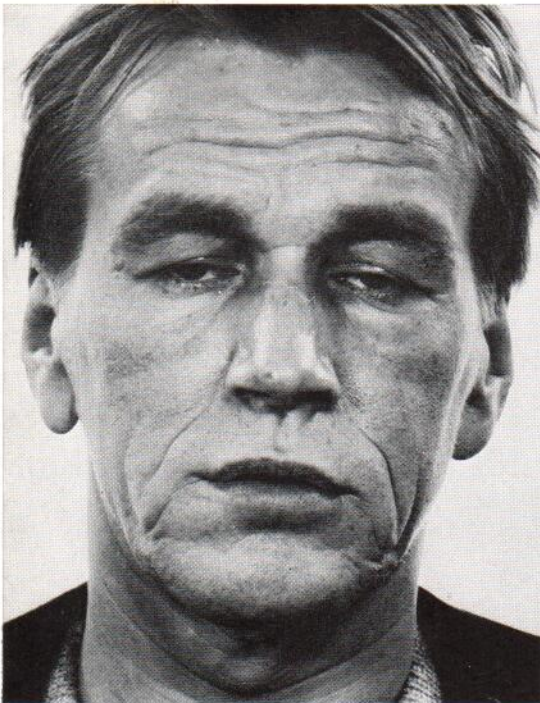


Fig. 3. Cutis laxa.

Dystrophia Unguis Mediana Canaliformis

Presented by Katri Rehtijärvi

A 16-year-old school-girl, the daughter of the previous patient. Since the age of 13 she has continuously had the same changes in her thumbnails as had her mother (Fig. 5).

Comment: Dystrophia unguis mediana canaliformis was described by Heller in 1928. Robinson & Weidman, and Sweet have also reported on this change affecting only the thumbnails. This rare deformity has not previously been reported as familial.

References

- Heller, J.: Zur Kasuistik der seltenen Nagel-Krankheiten. *Dermat Ztschr* 51: 416, 1928.
- Robinson, M. M. & Weidman, F. D.: Dystrophia unguis mediana canaliformis. *Arch Derm Syph* 57: 328, 1948.
- Sweet, R. D.: Dystrophia unguis mediana canaliformis. *Arch Derm Syph* 64: 61, 1951.

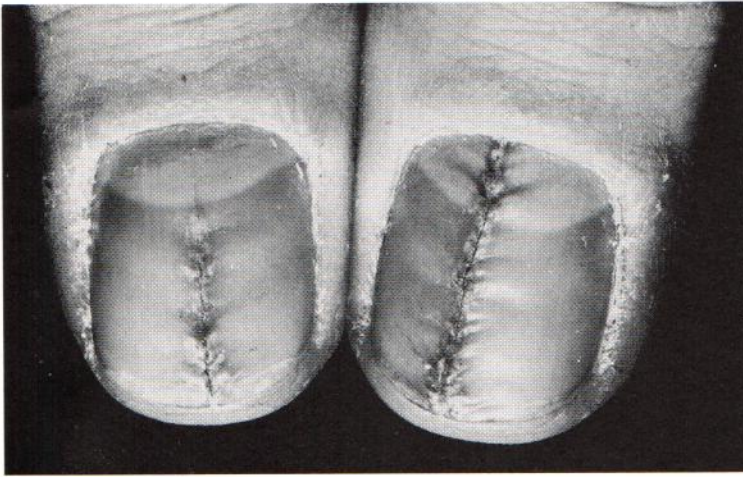


Fig. 4. Dystrophia unguis mediana canaliformis.

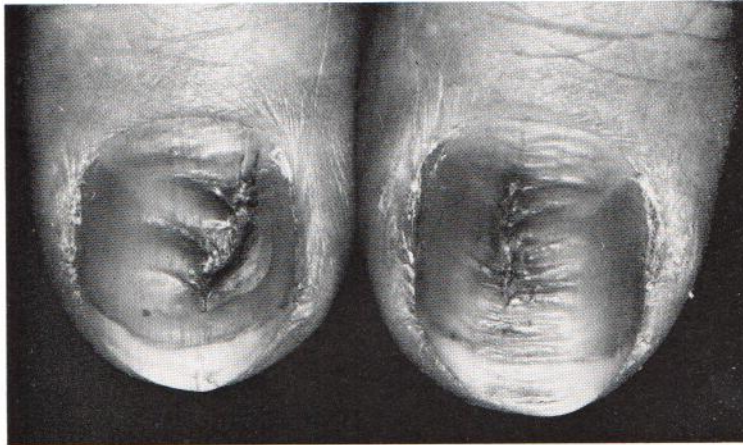

Fig. 5. Dystrophia unguis mediana canaliformis.

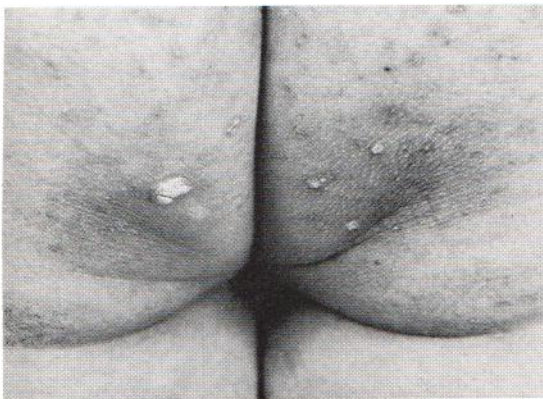

Fig. 6. Superficial disseminated eruptive form of Porokeratosis Mibelli.

Superficial Disseminated Eruptive Form of Porokeratosis Mibelli on Nonactinic Skin Areas

Presented by Kirsti-Maria Niemi

A 38-year-old female was affected with large ulcerations on the frontal sides of her legs and with thrombocytopenia. Due to earlier tuberculosis she had been administered antituberculous treatment together with cortisone. Scaling papules 2 to 5 mm in diameter covered with hard keratin appeared on the buttocks and the skin of the right wrist (Fig. 6).

Histology: Massive hyperkeratosis with separate vertical piles and lamellar plugs was seen in the