

SOCIETY PROCEEDINGS

FINNISH DERMATOLOGICAL SOCIETY

SECTION OF THE UNIVERSITY OF OULU, 1967-1968

Lupus Erythematosus Hypertrophicus et Profundus

Presented by Kai Dammert

A 69-year-old female, who, from 1944 to 1961, had a butterfly-figure-like eruption in her face. Finsen-treatment and streptomycin were administered because she was suspected. The skin of the cheeks healed and scarred. In 1963 a soft tumour began to grow on the scar-area of the left cheek (Fig. 1). The tumour was excised on suspicion of carcinoma.

Histology: The epidermis was irregularly atrophic and acanthotic. Hyperkeratotic plaques were seen on its surface. The basal layer displayed occasionally liquefied cells. Dermal adnexes were surrounded by a tight lymphocytic infiltration, which was also seen deep in the lower parts of the dermis (Fig. 2).

Comment: A very rare case of lupus erythematosus hypertrophicus et profundus. Skin hypertrophy of this extent is very unusual.

Cutis Laxa

Presented by Kirsti Kuokkanen

The patient was a 24-year-old man, whose facial skin at the age of 17 became slack and began to hang in folds (Fig. 3). There was no history of a corresponding case in the family. Examination revealed that the skin of the upper trunk was more flaccid than in other regions.

Histology: Collagen was normal in structure, but elastica-staining revealed that elastic fibres had decreased in number.

Dystrophia Unguis Mediana Canaliformis

Presented by Katri Rehtijärvi

A 43-year-old female whose nails were normal until the age of 10 years. Thereafter first transverse striae appeared on the thumbnails and later a longitudinal striae which partly split the nail (Fig. 4). The deformity disappeared for a time, but reappeared later, and for the past 10 years it has remained.

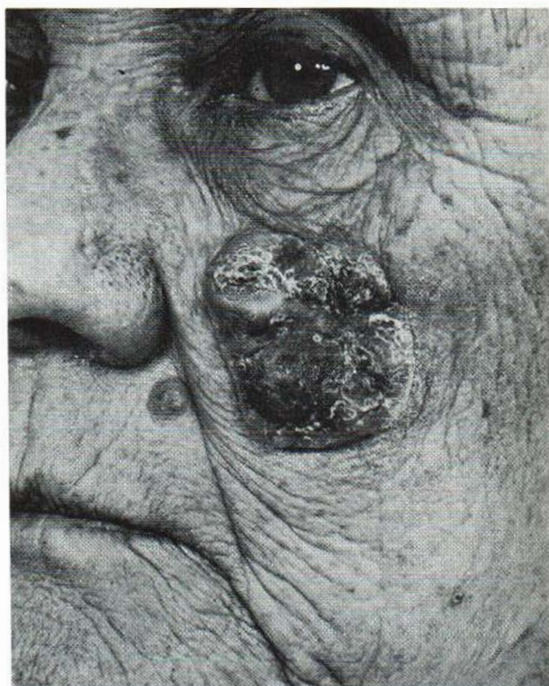

Fig. 1. Lupus erythematosus hypertrophicus et profundus.

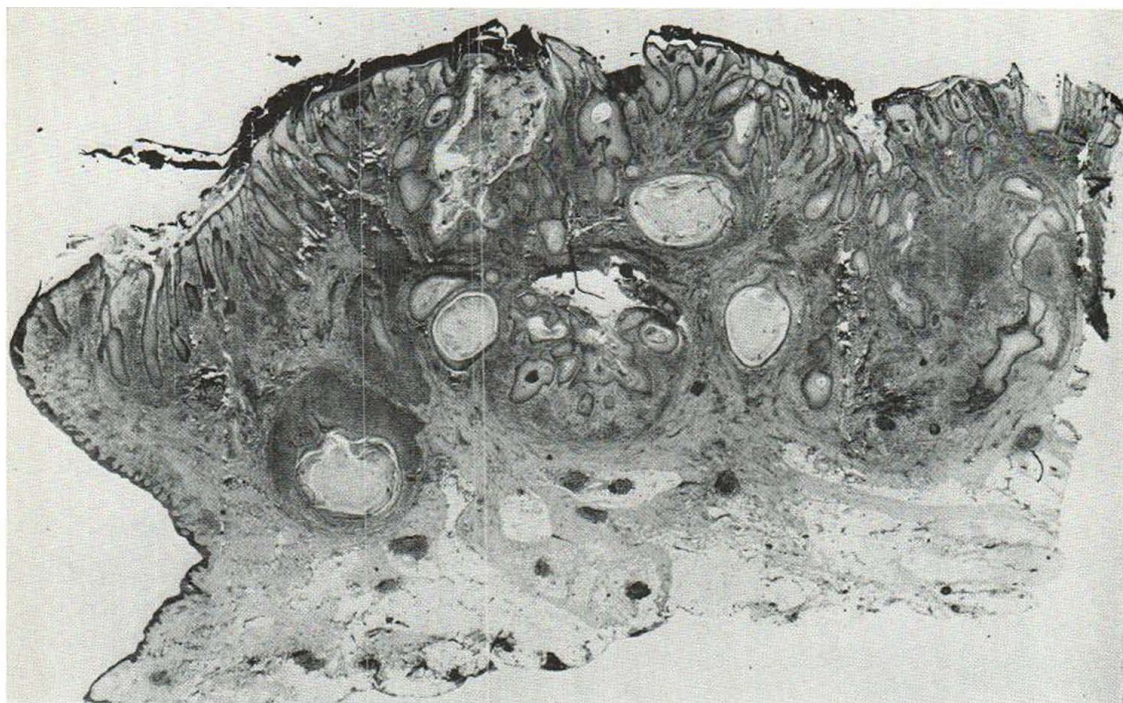


Fig. 2. Lupus erythematosus hypertrophicus et profundus.

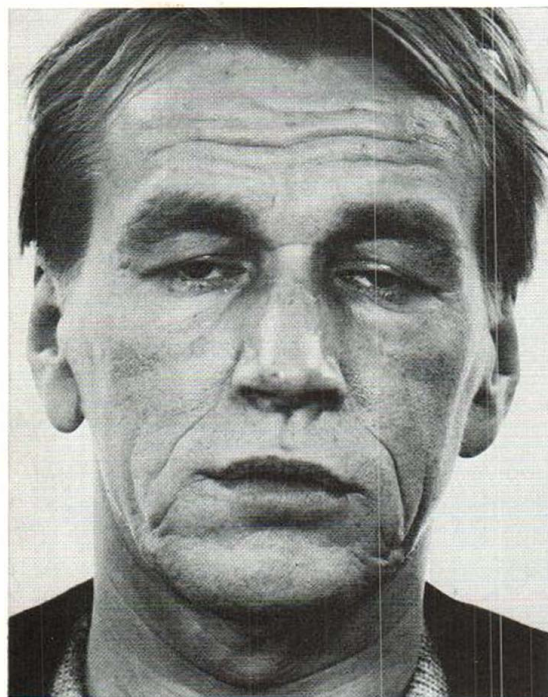


Fig. 3. Cutis laxa.

Dystrophia Unguis Mediana Canaliformis

Presented by Katri Rehtijärvi

A 16-year-old school-girl, the daughter of the previous patient. Since the age of 13 she has continuously had the same changes in her thumbnails as had her mother (Fig. 5).

Comment: Dystrophia unguis mediana canaliformis was described by Heller in 1928. Robinson & Weidman, and Sweet have also reported on this change affecting only the thumbnails. This rare deformity has not previously been reported as familial.

References

- Heller, J.: Zur Kasuistik der seltenen Nagel-Krankheiten. *Dermat Ztschr* 51: 416, 1928.
- Robinson, M. M. & Weidman, F. D.: Dystrophia unguis mediana canaliformis. *Arch Derm Syph* 57: 328, 1948.
- Sweet, R. D.: Dystrophia unguis mediana canaliformis. *Arch Derm Syph* 64: 61, 1951.