

ULTRAVIOLET LIGHT INFLAMMATION AND C-REACTIVE PROTEIN IN A CASE OF AGRANULOCYTOSIS WITH ERYSIPELAS

Claës-Otto Kindmark, Halvor Möller and Emil Neumann

*From the Departments of Clinical Chemistry and Dermatology, University of Lund,
Malmö General Hospital, Malmö, Sweden*

Abstract. An acute ultraviolet light inflammation was induced in a patient lacking circulating granulocytes. Polymorphonuclear leukocytes did not appear in the cutaneous lesion which otherwise developed normally, including the expected influx of lymphocytes. C-reactive protein (CRP) produced in response to a spell of erysipelas was shown to be normal and it was concluded that the CRP value and the leukocyte count are independent parameters.

The function of polymorphonuclear leukocytes (PMN) in acute inflammation has not been clarified. They dominate the early cellular infiltrate of human skin exposed to various injuries. Later on in the inflammatory process, the regular appearance of lymphocytes and histiocytes makes it tempting to presume that the different morphological stages are interdependent and that every step is conditioned by the previous phenomenon. Thus it has been assumed that substances inducing vascular dilatation and increased capillary permeability are liberated by lysosomes from ruptured PMN; such rupture with liberation of lysosomal enzymes does occur in skin exposed to ultraviolet (UV) light (5). However, time sequences of cellular infiltration and vascular phenomena vary between species in, e.g. ultraviolet injury (9).

The availability of a patient lacking circulating neutrophils prompted us to study the microscopic picture of UV light injury in order to learn more of the role played by PMN in the development of the acute inflammatory response.

Additionally, a problem of more clinical impact was approached in this study. It is often important to know whether or not a patient has an inflammatory process caused by bacteria. Likewise, it is important to know if the therapy given against severe bacterial diseases such as sepsis, subacute

endocarditis, abscesses, or sequelae such as rheumatic fever, is sufficient. Time-honored aids to the solution of this problem have been the patient's temperature, the total and differential leukocyte counts and the erythrocyte sedimentation rate, and since 1950, a semi-quantitative determination of C-reactive protein (CRP) (1). This protein has been used as an indicator of the activity of the disease process and the presence of CRP is considered one of the most sensitive tests of a necrotic process (15). Several authors (2, 10, 16) have shown a direct correlation between CRP and the white cell count, in man and the dog, respectively, but the source of CRP and the pathological mechanism resulting in the formation of this protein have not yet been settled. Actually, the question has been raised as to CRP and leukocytosis being independent parameters. As a matter of fact, Rapport et al. (14) suggested that CRP is a manifestation of the activity of cells, such as PMN, which appear in early response to tissue injury. On the other hand, Good (4) has shown that the CRP response to inflammatory stimuli was retained following induction of granulocytopenia by nitrogen mustard; his result has later been confirmed in a patient suffering from cyclic neutropenia (11), and in the rabbit (7). In our patient lacking circulating neutrophils we thought it accordingly of great interest to determine the amount of CRP by a new and quantitative technique during a spell of erysipelas.

MATERIAL

Patient A under study is described in the case report below. Patients B and C served as controls, both being treated with prednisone 15 mg daily. B was a 58-year-old

Table I. Rectal temperature, white blood and differential counts, and CRP in the agranulocytotic patient

Inflammation study was September 29 to October 3, second episode of erysipelas November 11 to 20

	September		October				November				
	29	30	1	2	3	13	11	12	13	14	20
Temp. °C, a.m.								37.2	37.0		36.5
Temp. °C, p.m.								37.6	38.3	38.0	37.3
WBC × 1000	9.8	13.9	10.7	7.8	7.0		4.3	7.8	12.3	10.1	8.3
Differential count (%)											
Unsegmented	0	0	0	0	0		0	0	0	0	0
Segmented	3	0	1	0	0		0	0	3	2	0
Eosinophils	2	1	1	0	0		1	1	0	1	0
Basophils	3	0	0	0	0		0	0	1	1	0
Lymphocytes	83	97	90	98	100		95	96	91	89	99
Monocytes	9	0	6	0	0		1	0	2	4	1
Myelocytes	0	2	2	2	0		3	2	1	0	0
Metamyelocytes	0	0	0	0	0		0	0	1	3	0
Plasma cells	0	0	0	0	0		0	1	1	0	0
CRP (mg/100 ml)						4.5	10	8	6	5	4

man with chronic hand dermatitis, C a 61-year-old man with a stasis dermatitis.

Case report

Patient A was a 61-year-old woman with a history of systematic lupus erythematosus since 1955. This diagnosis was based on malaise, spells of fever, polyarthralgia, leukopenia, LE-cells in the peripheral blood, and a diffuse hypergammaglobulinemia (IgG 2 g%). She had been continuously treated with oral steroids, usually prednisone 7.5 mg daily. In 1966 she was splenectomized because of agranulocytosis. Postoperatively, white blood counts were temporarily raised but soon decreased to an agranulocytotic level with 0-4% neutrophils in the differential count. Since 1966 she had been hospitalized several times because of recurring erysipelas, usually originating from minor ulcers on the lower legs. Diagnosis was founded on the clinical picture with a rapidly spreading, infiltrated and well-demarcated erythema, extending proximally from an inconspicuous traumatic ulcer, accompanied by prostration and fever chills. Hemolytic streptococci, however, were never cultured from the skin lesions but various low-virulent strains such as staphylococcus albus, proteus mirabilis, and candida albicans.

The patient was admitted in September 1969 (Table I) because of erysipelas of her lower left leg, originating from a traumatic ulcer. Her daily prednisone dosage had been increased lately to 15 mg, and when hospitalized she was given erythromycin 1 g daily. Fever and skin lesions disappeared within a week.

Two weeks later, when still in remission, and with maintained prednisone dosage of 15 mg, an acute UV injury was induced in the skin of the patient and her reactions were recorded. During this study the peripheral blood was examined daily for circulating leukocytes and a differential count. Before leaving hospital in good condition a blood sample for CRP was secured (Oct. 13).

In November the patient was readmitted for another spell of erysipelas in the same leg as before. Values for

rectal temperature, total and differential white blood counts, and CRP/s were collected from this episode.

METHODS

UV light inflammation was induced in the normal back skin of the agranulocytotic patient and of the two controls. A Kromayer mercury lamp with a decreased window area (diameter 10 mm) and a lamp/skin distance of 65 mm was used to determine the minimal erythema dose (MED) which was 10 sec for B and 20 sec for A and C. Then three MED of UV light was given to three areas on each patient. Punch biopsies were taken 8 hours, 24 hours and 72 hours after exposure. Samples were fixed in formalin and stained with hematoxylin-eosin and with toluidine blue.

Patient A was also injected intracutaneously with 0.1 ml of saline solutions of histamine HCl 0.01% and polymyxine B sulfate 0.5%.

CRP was determined as described earlier (6) As reference was used CRP prepared according to Ganrot & Kindmark (3) The nitrogen content of the preparation was determined according to Kjeldahl. The protein content was calculated by multiplying the Kjeldahl-N-value by 6.25.

RESULTS

The cutaneous reaction induced by UV light was macroscopically similar in the agranulocytotic patient (A) and in the two control patients (B and C). There was a non-palpable erythema at 8 hours and erythema with infiltration at 24 hours. However, in patient A the infiltration was weak and had disappeared at 72 hours whilst it was still palpable in the two controls.

The microscopic picture is illustrated in Fig. 1.

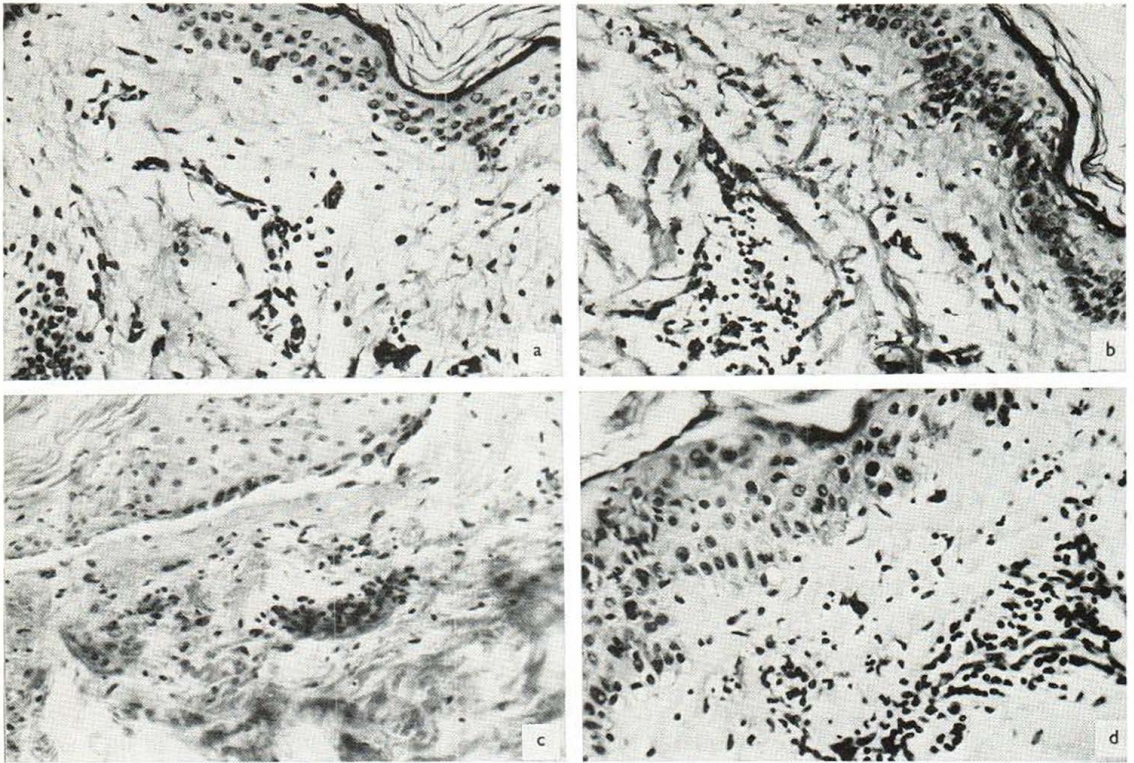


Fig. 1. Ultraviolet light reaction in the skin. (a) Patient A at 8 hours: vasodilatation and striking edema in corium, slight perivascular mononuclear infiltration, total absence of PMN. Focal liquefaction degeneration in basal cell layer, "altération cavitaire" in stratum spinosum. (b) At 24 hours: in comparison to (a), more intense mononuclear infiltration. Total absence of PMN. (c) At 72 hours:

perivascular infiltration of mononuclear cells in entire corium. Hyalinization of collagen, subepidermal vesiculation. Total absence of PMN. (d) Patient C at 72 hours: acanthosis with nuclear vesiculation in suprabasal layer, epidermal and dermal edema, exocytosis, perivascular infiltrate composed of mononuclears and PMN.

As expected, there were no PMN in the early reaction to UV light in patient A. In patients B and C some PMN could be seen at all stages of the inflammatory response but mononuclears always dominated the picture. In the later stages there was a regular infiltration of lymphocytes and connective tissue cells in patient A, quite similar to the findings in the controls. In all three cases there was vasodilatation and edema, as well as subepidermal vesiculation. In addition, signs of primary cell damage in the upper stratum spinosum in the form of hyalinization and nuclear pyknosis were observed, as well as signs of precocious regeneration (acanthosis and nuclear vesiculation) in the basal parts of the epidermis.

The intracutaneous injection of histamine in A resulted in a wheal of 20×20 mm and an erythema of 40×45 mm at 20 min. Polymyxine B

gave a wheal of 15×20 mm and an erythema of 40×50 mm. Both answers were considered normal reactions.

The values for rectal temperature, peripheral blood counts and CRP in patient A are given in Table 1. Total white counts varied between $4-13\,000/\text{mm}^3$, almost all cells being lymphocytes. Practically no neutrophil leukocytes appeared during the experimental inflammation, or during the second episode of erysipelas. In contrast, CRP was definitely increased from 4.5 to 10 mg/100 ml during the infection. The antistreptolysin-0 titre was weakly positive (360 U), and the patient was repeatedly tuberculin-negative.

DISCUSSION

Agranulocytosis in man is usually a grave disease of short duration and thus not amenable to experi-

mental studies. Hitherto, only one such case seems to have been published (11, 12). In this patient, having a periodic neutropenia, the authors provoked allergic skin reactions of delayed type and recorded changes in the histologic picture as well as the composition of the cellular infiltrate by means of Rebeck's skin window technique. In the leukopenic stage they did not notice any development of an inflammatory edema, and remarkably enough, the infiltration of lymphocytes was delayed or suppressed.

Several authors have studied the acute inflammatory response in experimental animals made neutropenic by a cytotoxic drug, usually nitrogen mustard. Varying results were obtained for different types of acute inflammation. Thus, delayed allergic reactions in the rabbit, including the Arthus- and Shwartzman phenomenon were decreased or abolished in the absence of PMN (12, 13, 17, 18). In an infectious inflammation the response was diminished (19). The results obtained with thermal injury were contradictory (20, 21), which, however, may be attributable to species discrepancy. For UV light inflammation in the guinea pig no microscopic picture was described but macroscopically the neutropenia did not influence the inflammatory process (8). Evidently, the varying cutaneous responses to acute injury are explained by difference in species and in inflammatory agent.

In view of our scanty knowledge in the field it seemed justified to publish a second case in man with experimental inflammation in the absence of neutrophils. It should, however, be pointed out that our patient did not suffer from a "pure" agranulocytosis. In other words, her underlying collagenic disease, although in remission, might influence the inflammatory response. One drawback in evaluating the inflammatory reaction was her corticosteroid therapy. It was attempted to counteract this difficulty by comparing with controls receiving the same treatment; their dose of 15 mg prednisone did not seem to suppress the UVL dermatitis.

With this reservation our findings may be evaluated as follows. Observing the UVL injury with the naked eye the inflammatory reaction seemed to proceed normally. The infiltration was, however, weak to palpate and disappeared early. This may possibly be due to the absence of PMN in the cellular infiltrate.

Light microscopy disclosed a normal inflammatory response with the exception of PMN. There was a vascular dilatation, including edema, and the regular infiltration of lymphocytes in the later stages. These findings are at variance with those of Page & Good (12), which is probably explained by the two different types of inflammation under study.

The vascular phenomena of UV light inflammation in the guinea pig have been reported not to be influenced by neutropenia (8) which seems to be in accordance with the results in our patient. Furthermore, the cutaneous vessels of our patient were sensitive to a vasodilating agent (histamine). A triple response was also induced by a histamine liberator, polymyxine B. This is in agreement with the finding of metachromatically stainable mastocytes. In the neutropenic guinea pig the cutaneous response to a histamine liberator was decreased (the presence of dermal mastocytes was not registered) although the reaction to histamine itself was normal (9).

The basic question of the role of PMN in the development of the inflammatory response may hardly be answered by our limited results. Nevertheless, one conclusion seems justified: since vascular phenomena and lymphocytic infiltration occur in the absence of circulating granulocytes the importance of these latter cells in conditioning the later stages in a non-allergic inflammation appears small.

The amount of CRP produced by our agranulocytosis patient during a spell of erysipelas is about the same as could be expected from the severity of the disease. It is interesting to note that CRP was produced during remission, when the patient received steroids, possibly indicating that her LED was still active and more prednisone or immunosuppressive agents might have been useful. From the results it may also be justified to conclude that the amount of CRP is a parameter independent of the leukocyte count and that the CRP production does not require circulating PMN.

ACKNOWLEDGEMENT

Supported by grants from the Faculty of Medicine, University of Lund.

REFERENCES

1. Anderson, H. C. & McCarty, M.: Determination of C-reactive protein in the blood as a measure of activity. *Acta Dermatovener (Stockholm)* 51

- uity of the disease process in acute rheumatic fever. *Amer J Med* 8: 445, 1950.
2. Dillman, R. C. & Coles, E. H.: A canine serum fraction analogous to human C-reactive protein. *Amer J Vet Res* 27: 1769, 1966.
 3. Ganrot, P. O. & Kindmark, C.-O.: A simple two-step procedure for isolation of C-reactive protein. *Biochim Biophys Acta* 194: 443, 1969.
 4. Good, R. A.: Acute-phase reactions in rheumatic fever. *In* Rheumatic Fever (ed. L. Thomas). University of Minnesota Press, Minneapolis, 1952.
 5. Johnson, B. E. & Daniels, Jr, F.: Lysosomes and the reactions of skin to ultraviolet radiation. *J Invest Derm* 53: 85, 1969.
 6. Kindmark, C.-O.: Quantitative measurement of C-reactive protein in serum. *Clin Chim Acta* 26: 95, 1969.
 7. Kushner, I. & Kaplan, M. H.: Studies of acute phase protein. *J Exp Med* 114: 961, 1961.
 8. Logan, G. & Wilhelm, D. L.: Ultra-violet injury as an experimental model of the inflammatory reaction. *Nature* 198: 968, 1963.
 9. — The inflammatory reaction in ultraviolet injury. *Brit J Exp Path* 47: 286, 1966.
 10. Matsushima, Y.: C-reactive protein in the postoperative patient. *Bull Tokyo Med Dent Univ* 14: 1, 1967.
 11. Page, A. R. & Good, R. A.: Studies on cyclic neutropenia. A clinical and experimental investigation. *Amer J Dis Child* 94: 623, 1957.
 12. — A clinical and experimental study of the function of neutrophils in the inflammatory response. *Amer J Path* 34 (11): 645, 1958.
 13. Parish, W. E.: Effects of neutrophils on tissues. Experiments on the Arthus reaction, the flare phenomenon, and post-phagocytic release of lysosomal enzymes. *Brit J Derm* 81: suppl. 3, 28, 1969.
 14. Rapport, M. M., Schwartz, A. E. & Graf, L.: C-reactive protein in patients following operation. *Ann Surg* 145: 321, 1957.
 15. Schwarz, G.: Das C-reaktive Protein. Dr Dietrich Steinkopff Verlag, Darmstadt, 1963.
 16. Seidel, K. & Reuter, W.: Ergebnisse der C-reaktiven-Protein-Bestimmungen bei rheumatischen Herzfehlern, und ihre Korrelation zu anderen Serum-Untersuchungsmethoden. *Z. Rheumaforsch* 21: 79, 1962.
 17. Stetson, Ch. A., Jr, & Good, R. A.: Studies on the mechanism of the Schwartzman phenomenon. Evidence for the participation of polymorphonuclear leucocytes in the phenomenon. *J Exp Med* 93: 49, 1951.
 18. Stetson, Ch. A., Jr.: Similarities in the mechanisms determining the Arthus and Schwartzman phenomena. *J Exp Med* 94: 347, 1951.
 19. Taichman, N. S., Freedman, H. L. & Uriuhara, T.: Inflammation and tissue injury. I. The response to intradermal injections of human dentogingival plaque in normal leukopenic rabbits. *Arch Oral Biol* 11: 1385, 1966.
 20. Uriuhara, T. & Movat, H. Z.: Role of PMN-leukocyte lysosomes in tissue injury, inflammation and hypersensitivity. V. Partial suppression in leukopenic rabbits of vascular hyperpermeability due to thermal injury. *Proc Soc Exp Biol Med* 124: 279, 1967.
 21. Willoughby, D. A. & Spector, W. G.: Inflammation in agranulocytotic rats. *Nature* 219, 1258, 1968.

Received October 6, 1970

Halvor Möller, M.D.
Department of Dermatology
Malmö General Hospital
S-214 01 Malmö
Sweden