

REGENERATION OF HUMAN EPIDERMAL SURFACE AND WATER BARRIER FUNCTION AFTER STRIPPING

A Combined Study with Electron Microscopy and Measurement of Evaporative Loss

Göran Eriksson and Lars-Olof Lamke

From the King Gustaf V Research Institute and the Department of Environmental Factors of the Swedish Research Institute of National Defence, Stockholm, Sweden

Abstract. The exterior layers of the epidermis were removed by tape-stripping and regeneration was followed by daily measurements of evaporation in a climate chamber with well defined environment and simultaneous study of the ultrastructure. At first the evaporative water loss from the injured surface epithelia was very extensive, but very soon decreased because of the regeneration of the stratum corneum which underwent structural changes during the healing process. Already by the third to fourth day numerous new layers of the stratum corneum were formed, and evaporation was then only slightly raised. After about eight days conditions were almost normal. The layers which act as a protection against desiccation are situated very superficially in the epidermis. The immature corneal cells, formed early in the healing process, very soon render good protection against water loss from the injured surface.

One of the most essential functions of the skin is to reduce water loss from the body surface. Injury to the protective layers causes excessive water loss and disturbs the cellular tissue. This leads to water and electrolyte imbalance in the organism.

The purpose of the present work was to ascertain the location of those layers in the skin which give protection against water loss and to study the generation of these cell layers after experimental injury.

Earlier investigations

Evaporative measurements and electronic microscopy of tape-stripped skin during the healing process have been carried out separately but not in combination and not under controlled ambient conditions.

Monash & Blank (9) applied an unventilated apparatus in which evaporative water loss was measured and combined this with tape-stripping.

One day after tape-stripping the evaporation had decreased from 29 mg cm⁻²h⁻¹ to 15 mg cm⁻²h⁻¹ and after 48-72 hours it was 8 mg cm⁻²h⁻¹. Light microscopic investigations of repeated skin biopsies showed that the damaged stripped skin was replaced by a layer of immature parakeratotic cells. Later, this layer was replaced by normal stratum corneum. These authors concluded that the layer preventing evaporation was situated in the deeper part of the stratum corneum. Fallon & Moyer (2) calculated the vapour pressure in different layers of the skin. Immediately under the deepest skin layer the pressure recorded was 44 mmHg; at the surface epithelium, 23 mmHg. After stripping the skin, evaporation increased 20 times and normalization of the vapour penetration occurred during the following 3 to 6 days.

In another experiment the skin was defatted by an acetone-hexane solution, whereby skin evaporation was greatly increased. It was concluded that the water-preserving layer consisted of a hydrous lipoprotein complex.

Baker & Kligman (1) also found that stripping increased evaporation. After 2 days they observed that the skin injury had healed to an extent of nearly 50%. At the same time the thickness of the skin was measured, and evaporation was found to be in inverse proportion to the thickness of the corneal layer. The existence of a special layer preventing evaporation could not be verified. They considered that evaporation followed the diffusion and was throughout in inverse proportion to the thickness of the stratum corneum.

Regeneration and mitotic activity was studied

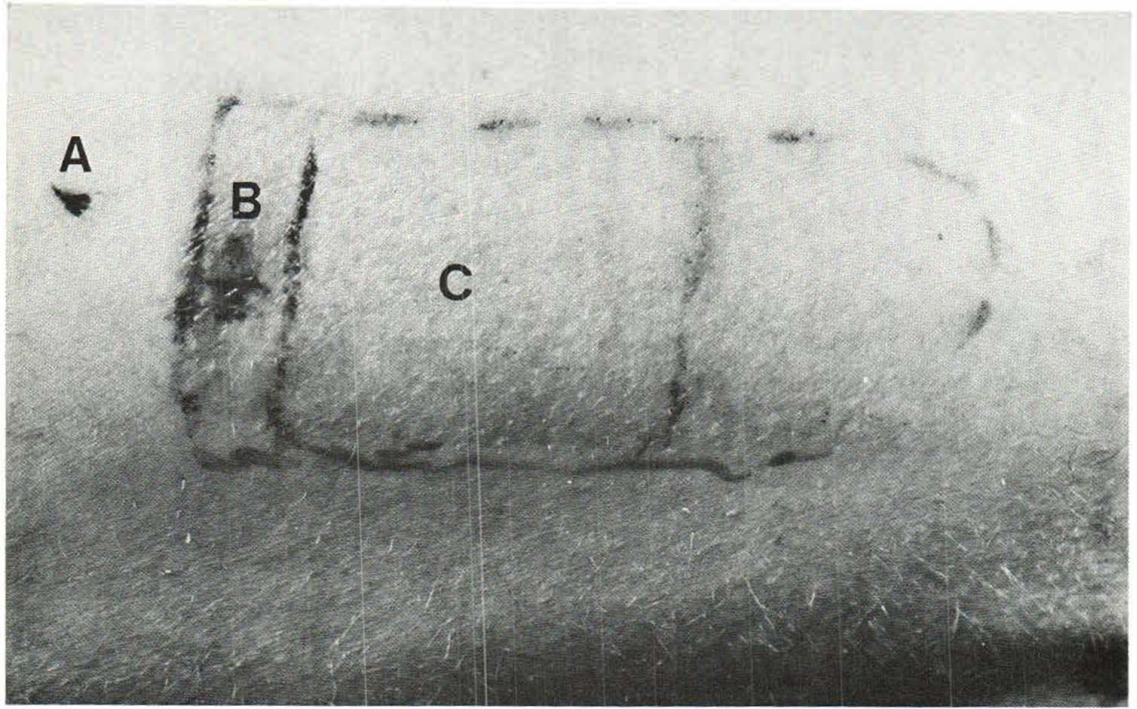


Fig. 1. Measuring area on outer side of thigh. A, Biopsy from normal skin. B, Biopsies from stripped area. C,

Area for measuring evaporation. Dotted lines indicate perimeter of stripped area.

under a light microscope by Pinkus (11), who found from three to four new layers of corneum after 48 hours. The mitotic activity greatly increased after 24 hours.

Mishina & Pinkus (8) found, after stripping, cellular edema and damage of the plasma membranes at the desmosomes. This damage was healed, however, in 2 days. Pinkus (11) is of the opinion that the loss of corneum is the stimulus to regeneration of the epidermis. Matoltsy, Schragger & Matoltsy (7) demonstrated that keratohyaline granules disappeared 24 hours after stripping and reappeared between the third and fourth day. At the same time parakeratosis occurred in the corneum. Ohara & Mizuna (10) considered that the diffusion barrier was situated in the deepest layers of stratum corneum or lucidum.

MATERIAL AND METHODS

The experiments were performed on two healthy male subjects. They stayed in a climate chamber at $+28 \pm 1/2^\circ\text{C}$ and $40 \pm 4\%$ relative humidity (RH). The experiments were started after 30 min adaptation. After electric shav-

ing the outer skin layer was removed from the external side of the thigh by the repeated stripping of adhesive plaster (Mölnlycke 5 cm 303300—Mölnlycke AB, Gothenburg, Sweden). Three series of experiments, consisting of a maximum of 50, 75 and 100 strippings respectively, were performed on each subject. During the stripping process and regeneration, evaporation was regularly measured by an "evaporometer" (4).

In the "evaporometer" a slow current of air is passed over a test area of 25 cm^2 . The humidity in the in-going and out-going air is measured and the increase of moisture is recorded. When knowing the humidity increase and the flow of air the evaporation can be calculated and expressed in mg of water per cm^2 and hour.

Biopsies were taken regularly from the subject's skin immediately after stripping and the following 7 to 8 days (Fig. 1). The area was anesthetized locally with Citanest-Exadrin 0.5% (AB Astra, Södertälje, Sweden). The biopsies were fixed in buffered 1% osmium tetroxide solution (13). Fixation was carried out in an ice bath for 3 hours, after which the specimens were rinsed in 0.9% saline solution and dehydrated with ethyl alcohol in increasing concentration: thereafter they were embedded in Epon or Vestopal. Sections, $1-3 \mu$ thick, were stained with toluidine blue (12) and were studied under a light microscope. Thin sections were stained with uranyl acetate (16) and lead acetate (3). The sections were studied and photographed in Siemens Elmiskop I at 80 kV and with $2-10\ 000\times$ primary magnification.

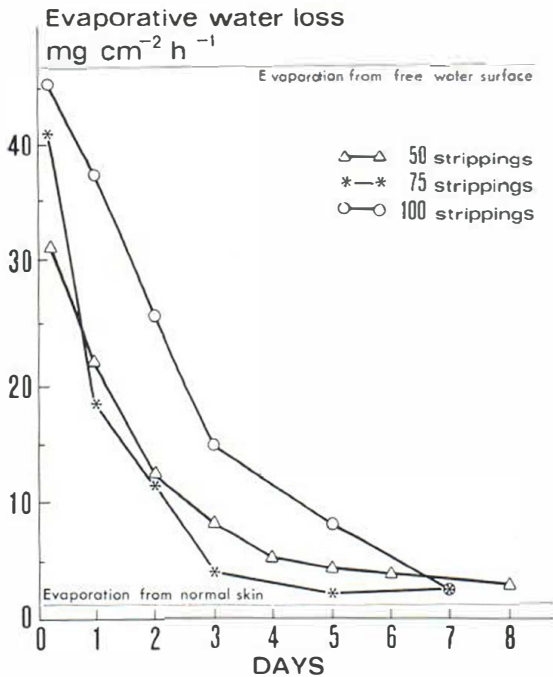


Fig. 2. Evaporative water loss during healing in the three series. Water loss from free water surface calculated according to a modification of Rohwer's formula (14). Water surface temperature $+33^{\circ}\text{C}$ and air conditions $+28^{\circ}\text{C}$ and 40% RH. Evaporation from normal skin according to Lamke & Wedin (6).

RESULTS

Macroscopic findings

After stripping there was redness and slight edema in the stripped area. The surface was glistening and felt moist during the first 24 hours. From 3 to 4 days later the redness acquired a light brown tint, and the edema regressed. During days 7 and 8 there was slight peeling. After about 2 weeks no macroscopic changes were visible.

Evaporative measurements

Up to 75 strippings, the increase in evaporation was rapid, but then became slower. At 100 strippings a maximum seemed to have been reached at 46.4 and 45.0 $\text{mg cm}^{-2}\text{h}^{-1}$. At 75 strippings evaporation was 39.2 and 43.2, and at 50, 27.4 and 34.2 $\text{mg cm}^{-2}\text{h}^{-1}$ respectively.

Healing was more rapid after 50 and 75 than at 100 strippings when it seemed to be delayed 24 hours. In all the series evaporation showed a marked regression during the first 3 days. On the following days this seemed to be slower. After 7 to 8 days the value was almost normal (Fig. 2).

Ultrastructure findings

The healing was similar in the series where 50 and 75 strippings were applied and, consequently, these series are given together.

In biopsies taken directly in connection with 50 strippings 3–4 corneal layers remained and after 75 strippings these layers were reduced to 1–2. In 2–3 cell layers membrane-coating granulae (MCG) appeared as in normal epidermis. The epidermis was otherwise intact. Twenty-four hours later, in both series, 6–7 corneal layers rapidly developed which contained nuclear residue. Marked reduction in both keratohyaline (KH) and MCG was observed mostly in the series of 50 strippings (Fig. 3). Two days later a few defective corneal layers were formed. The number of KH and MCG had also started to increase. On the third day there was further increase in the corneal layers, KH were restored in 4–5 and MCG in 2–4 cell layers (Fig. 4). Manifest nuclear edema in the upper corneum and distended tonofibrils in elongated basal cells were observed.

After 4–5 days the upper stratum corneum had more blistery structures with nuclear residue. In the lower layers the corneal cells had normal appearance (Fig. 5). Both KH and MCG reappeared in 2–3 of the layers, which, however, had apparently abundant granulae. The above-mentioned corneal layers persisted in the still unrejected surface epithelia. After 6–8 days there was still edema in the nuclei, but only in the outermost parts of the stratum spinosum.

In biopsies taken directly after 100 strippings a corneal layer was still visible and in the entire epidermis, generalized, perinuclear edema was present, in which the nucleus was semilunar, pericentric, and compressed (Fig. 6). Twenty-four hours later pronounced intercellular edema was observed, with extended and detached desmosomes (Fig. 7).

After 2 days there were a few KH-granulae in seven corneal layers. The perinuclear and intercellular edema had regressed. In the lower stratum spinosum there was moderate nuclear edema (Fig. 8). On the third day KH was present in 4–5 cell layers and palisade basal cells and clumsy projections on the basement membrane. During the fifth day KH was observed in four cell layers besides manifestly chromatin-poor nuclei with edema in the stratum spinosum.

On day 8 evident generations were observed in

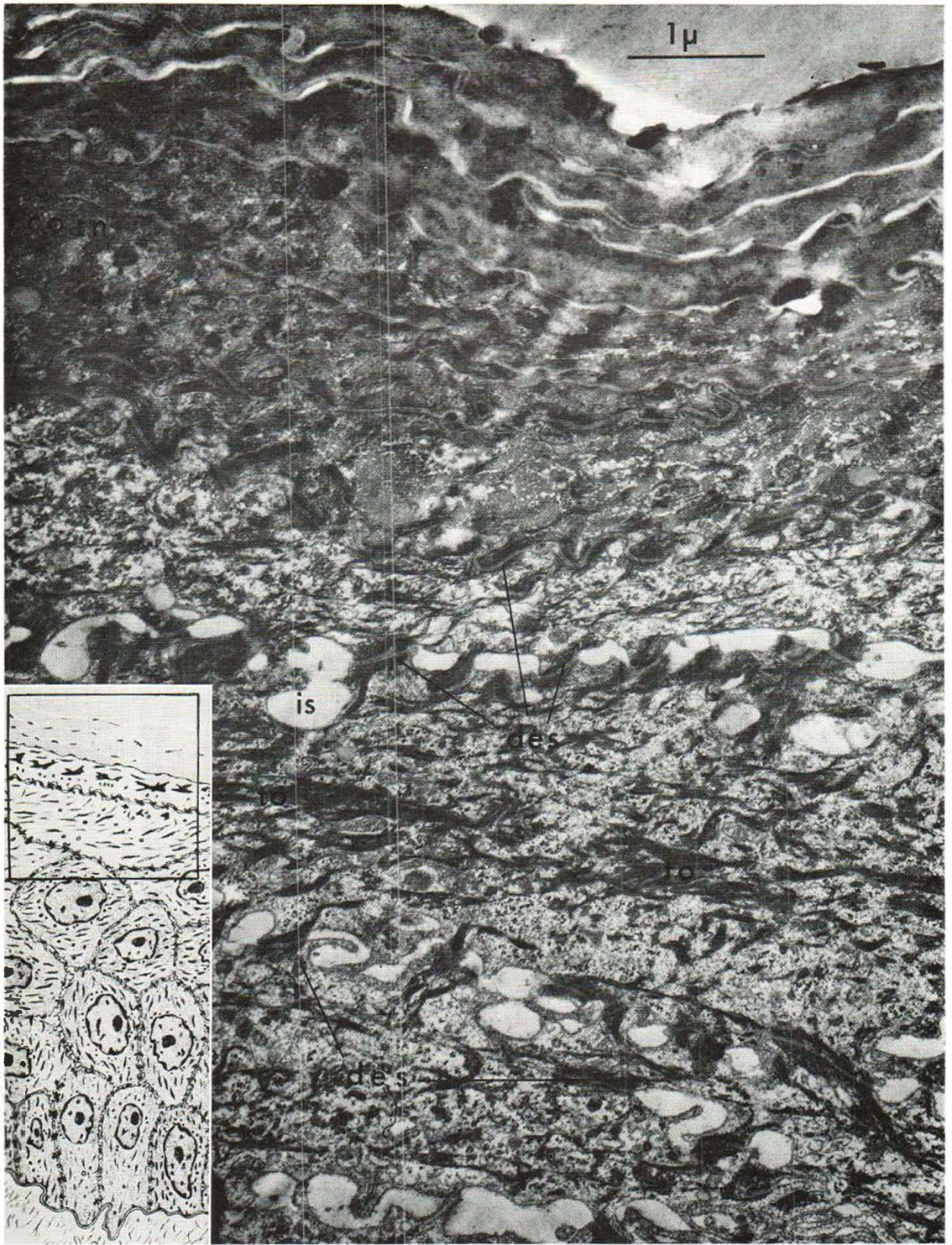


Fig. 3. Regeneration of skin 1 day after 50 strippings. Abnormal dehydration in the granulosum and no keratohyaline granules are observed. A few membrane-coating

granulae (MCG) are situated in the lower part of the stratum granulosum. *des*, desmosomes; *to*, tonofibrils; *is*, intercellular space. $\times 21\,400$.

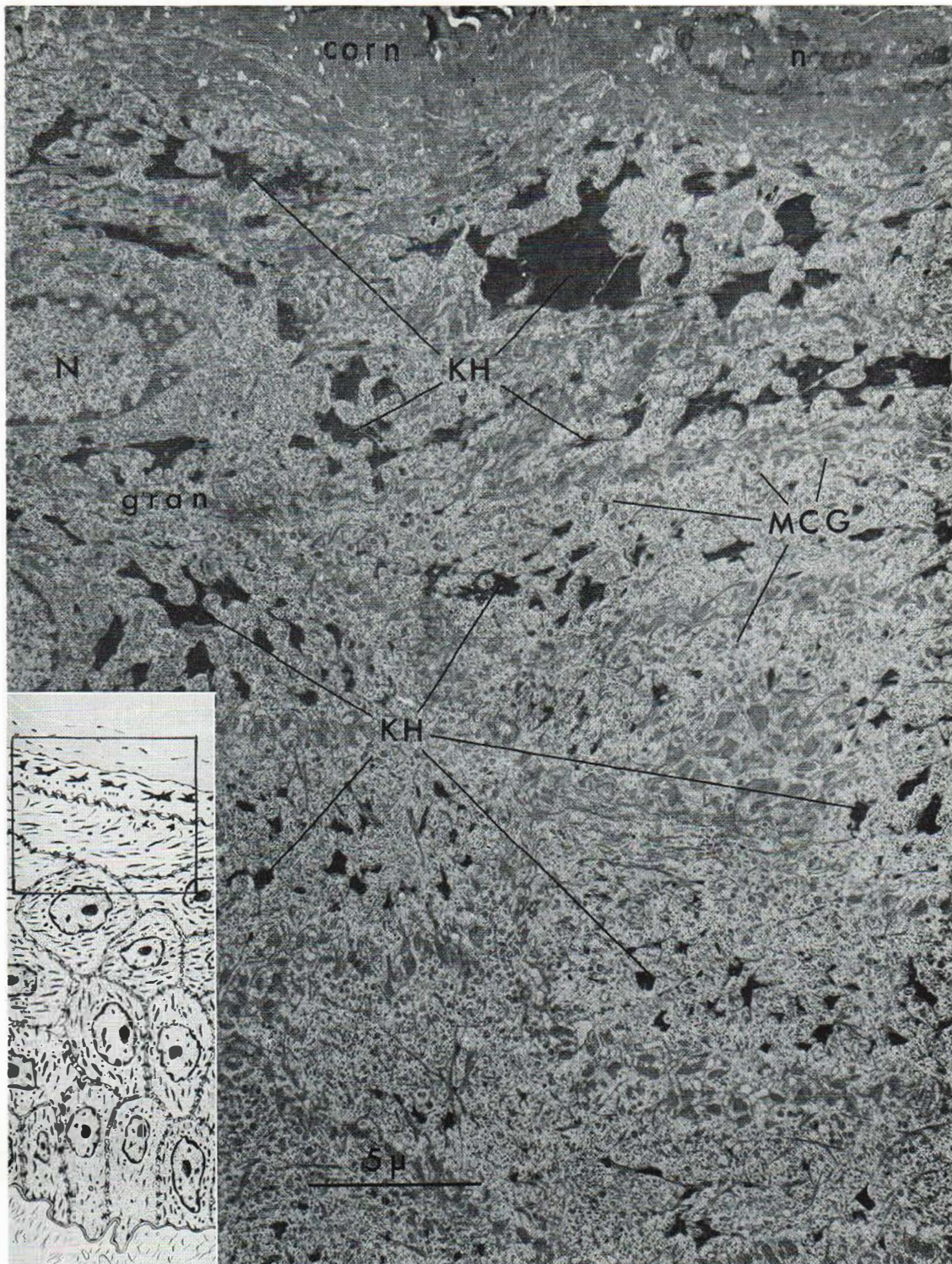


Fig. 4. Regeneration 3 days after 75 strippings. There are now several layers with keratohyaline granulae (KH). The granulae are larger near stratum corneum. Several

membrane-coating granulae (MCG) are visible. N, Nucleus in granulosum cell; n, remaining nucleus in parakeratotic corneum cell. $\times 5350$.

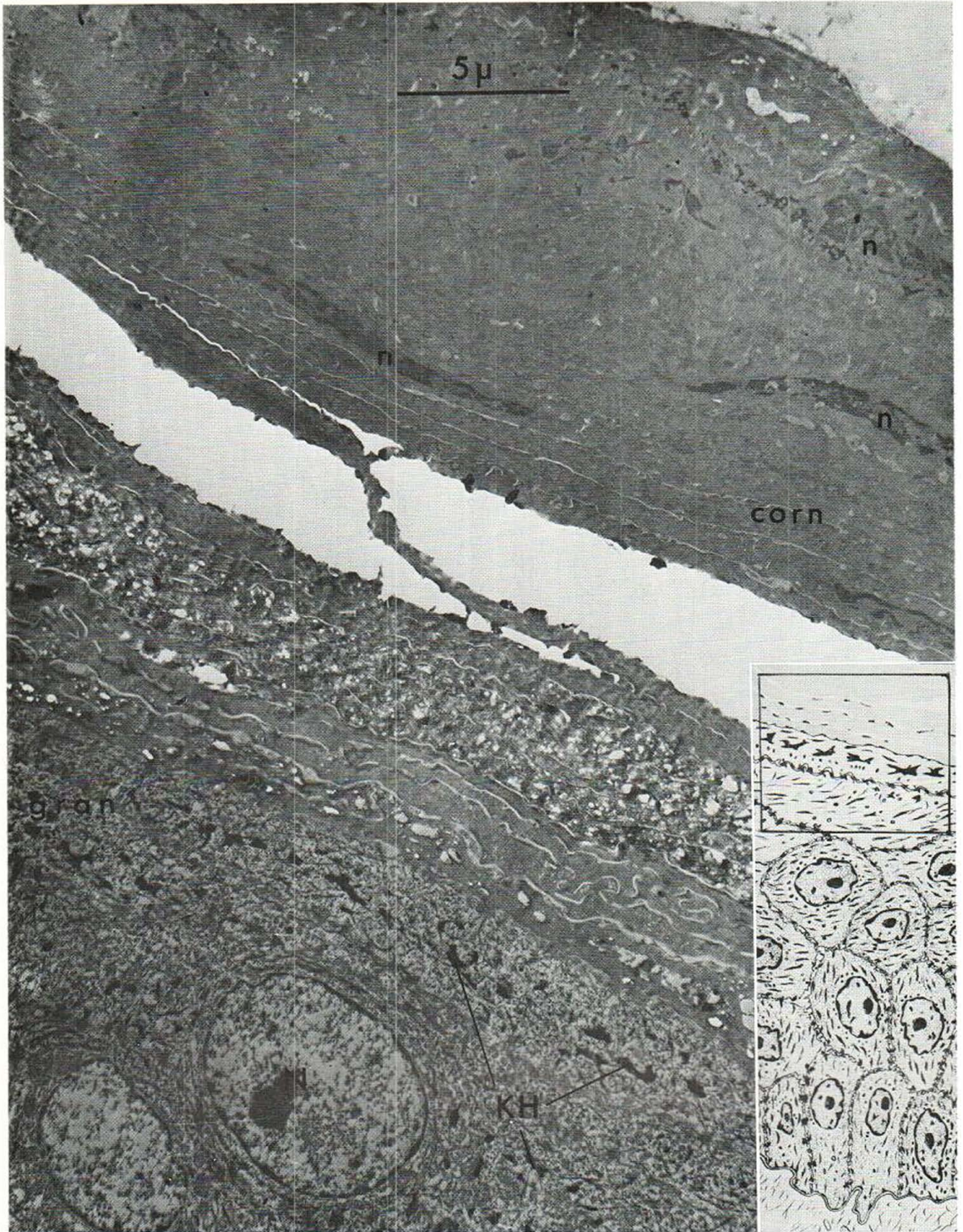


Fig. 5. Regeneration 8 days after 75 strippings. Several layers of the stratum corneum with obvious generations. Surface parakeratotic cells and deeper cells full of vesicles.

Normal keratinization. Slight edema in the nuclei (n).
× 5 350.




Fig. 6. Specimen immediately after 100 strippings. The cells show slight edema with deformed pycnotic nuclei (*n*), which are compressed pericentrally and exhibit peri-

nuclear edema (*ps*). Increased fluid in the intercellular space (*is*). $\times 4700$.

the corneum with partly parakeratosis, and partly inadequate keratinization with some remaining KH-granulae (hypokeratosis). Now 2–3 cell layers contained KH. Nuclear edema was still present in the stratum spinosum though to a less extent. Normalization occurred in the basal cells and basement membrane.

DISCUSSION

When evaporation was between $40\text{--}50\text{ mg cm}^{-2}\text{ h}^{-1}$ the microscopy showed that only a few detached corneal layers remained. It seemed impossible to penetrate deeper because adhesion be-

tween the cells in the stratum granulosum and the underlying layers was too strong to enable separation of these cells by the stripping technique used or the tape did not adhere to these wet layers. The stretching of the tissue evidently caused so much damage that both intra- and extracellular edema developed, which was naturally most pronounced after 100 strippings. The injury had then resulted in such extensive leakage that the surface became wet. Evaporation was now limited only by such physical factors as temperature of the surface and the humidity and temperature of the air.

When measuring on a free water surface Lamke

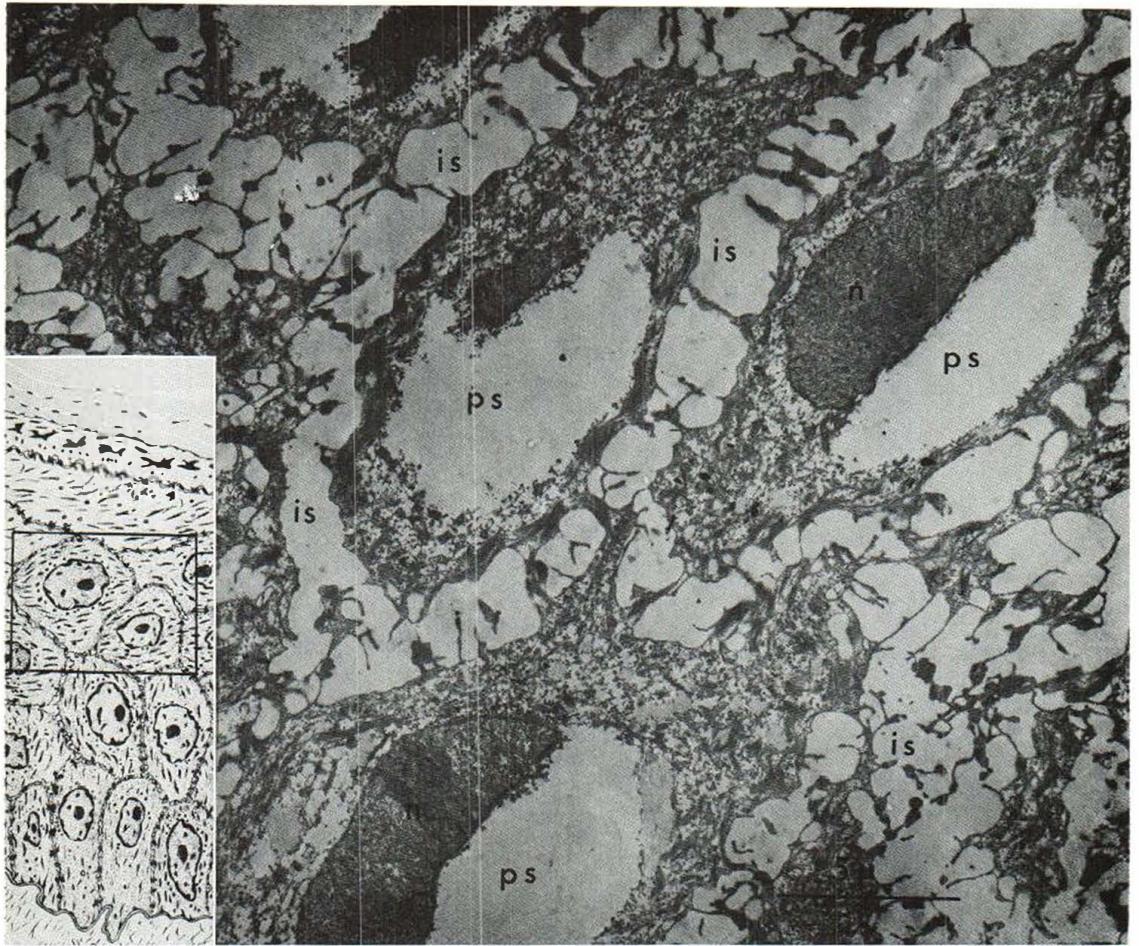


Fig. 7. One day after 100 strippings. Nuclei (n) still compressed with perinuclear edema (ps). Prominent intercellular edema has appeared. $\times 4\ 700$.

& Wedin (6) obtained a mean value of $53\text{ mg cm}^{-2}\text{h}^{-1}$ at a surface temperature of $+34^\circ\text{C}$. When calculating the evaporation according to Rohwer's formula (14) we obtained a value of $47.5\text{ mg cm}^{-2}\text{h}^{-1}$ at a surface temperature of $+33^\circ\text{C}$. In our experiments the mean surface temperature after 75 strippings was $+31.8^\circ\text{C}$. Thus the values found were very close to those for a freely evaporating, open water surface. For a strongly evaporating second degree burn the values were of the same magnitude (5).

Regeneration seems to develop very rapidly, and the same tendency occurred in all the series except the one with 100 strippings, where the healing was retarded one day. Here, evidently, a deeper injury had been caused. This was in good agreement with

the microscopic picture. Formation of the new corneal layers developed so rapidly that, after 50–75 strippings, the normal maturation with keratohyaline (KH) and membrane-coating granulae (MCG) was absent only from the upper layer of the stratum granulosum 1 day after stripping, but was present in the lower layer (Fig. 3). KH seemed to disappear at the same time. Therefore the MCG, which were formed in a lower layer, could be reproduced more readily than the KH. These granulae reappeared when the regeneration velocity decreased between the third and fourth day.

Apparently, the newly formed corneal layers soon afforded good protection against tissue desiccation. During the first 3 days evaporation was substantially reduced, but later in the course the

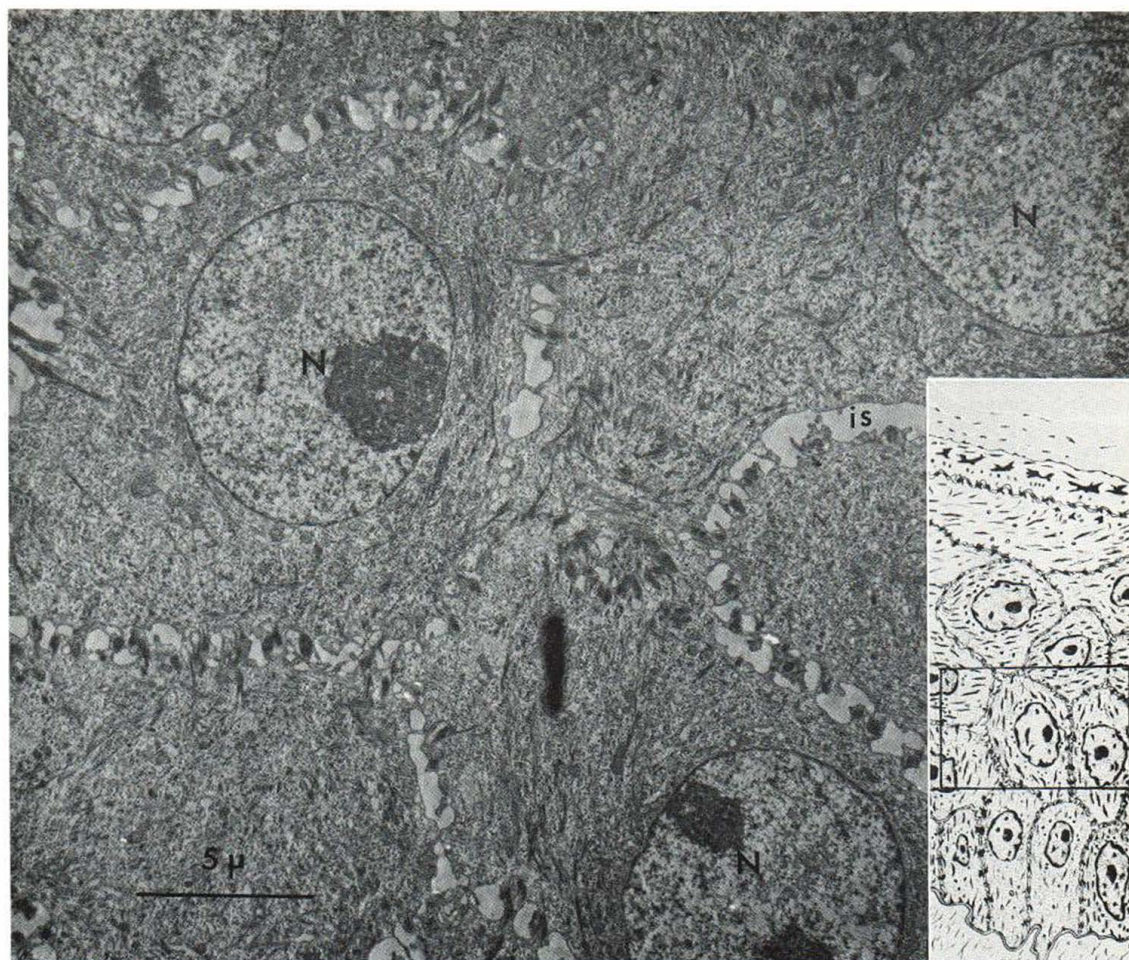


Fig. 8. Two days after 100 strippings. The nuclei (N) are normalized. Slight intranuclear edema is visible. Intercellular space is normalized. $\times 4700$.

healing process slowed down. This gave the curves (Fig. 2) a biphasic appearance. Our results are in close agreement with those of Monash et al. (9) and Matoltsy et al. (7). These authors found an 80% reduction already after 2 to 3 days. Other investigators (1, 15) reported a slower regeneration rate, which might be caused by a difference in the stripping technique used.

The ultrastructure of the corneal cells in the incipient healing process showed a pronounced immaturity. During the same time, the evaporation decreased markedly. This indicates that even immature corneal cells can give a relatively good protection against evaporative water loss.

On the sixth day the injury was, physiologically,

almost healed, but morphologically, healing took another 2 days before the cell layers were completely mature.

REFERENCES

1. Baker, H. & Kligman, A. M.: Measurement of trans-epidermal water loss by electrical hygrometry. *Arch Derm (Chicago)* 96: 44, 1967.
2. Fallon, R. H. & Moyer, C. A.: Rates of insensible perspiration through normal, burned, tape-stripped and epidermally denuded living human skin. *Ann Surg* 158: 915, 1963.
3. Karnovsky, M. J.: Simple methods for "staining with lead" at high pH in electron microscopy. *J Biophys Biochem Cytol (New York)* 11: 729, 1961.
4. Lamke, L. O.: An instrument for estimation of water

- evaporation from small skin surfaces. *Scand J Plast Reconstr Surg* 4: 1, 1970.
5. Lamke, L. O. & Liljedahl, S. O.: Evaporative water loss from burns, grafts and donor sites. *Scand J Plast Reconstr Surg* 5, 1971, in press.
 6. Lamke, L. O. & Wedin, B.: Water evaporation from normal skin under different environmental conditions. *Acta Dermatovener (Stockholm)* 51: 111, 1971.
 7. Matoltsy, A. G., Schragger, A. & Matoltsy, M. N.: Observations on regeneration of the skin barrier. *J Invest Derm* 38: 251, 1962.
 8. Mishina, Y. & Pinkus, H.: Electron microscopy of keratin layer stripped human epidermis. *J Invest Derm* 50: 89, 1968.
 9. Monash, S. & Blank, H.: Location and re-formation of the epithelial barrier to water vapor. *Arch Derm (Chicago)* 78: 710, 1958.
 10. Ohara, K. & Mizuna, I.: Identification of locality of the diffusion barrier in the skin. *Nagoya Med J* 10: 11, 1964.
 11. Pinkus, H.: Examination of epidermis by the strip method of removing horny layers. *J Invest Derm* 16: 383, 1951.
 12. Richardsson, K. C., Jarett, L. & Finke, E. W.: Imbedding in epoxy resins for ultrathin sectioning in electron microscopy. *Stain Techn* 35: 313, 1960.
 13. Rhodin, J.: Correlation of Ultrastructural Organization and Function in Normal and Experimentally changed Proximal Convolute Tubuli Cells of the Mouse Kidney. Karolinska Institutet, Stockholm. (Thesis) 1954.
 14. Rohwer, C.: Evaporation from free water surfaces. *Us Dept Agricult Techn Bull (Washington)* 271, 1931.
 15. Spruit, D. & Malten, K. E.: The regeneration rate of water vapor loss of heavily damaged skin. *Dermatologia* 132: 115, 1966.
 16. Watson, M. L.: Staining of tissue sections for electron microscopy with heavy metals. *J Biophys Biochem Cytol (New York)* 4: 475, 1958.

Received November 24, 1970

G. Eriksson, M.D.
 King Gustaf V Research Institute
 S-104 01 Stockholm 60
 Sweden