

SYPHILIS OF THE LUNG

A case report and discussion of its clinical diagnosis

S. HAIM, A. SHAFRIR AND Y. SASSON

Late complications of syphilis are nowadays apparently rarely encountered because of the nature of modern treatment for early syphilis. Syphilis of the lung was particularly rare even in earlier times. Recent literature describes very few new cases. It is possible that the difficulty in establishing the diagnosis to some extent contributes to this (9, 12, 10). Roessle (7) had seen at the autopsy table only cases which were not diagnosed clinically. This background gives special interest to a case of pulmonary syphilis which had been diagnosed clinically with reasonable certainty.

Case Report

The patient was a 59-year-old Tunisian male, a father of three healthy children, with nothing of particular interest in his family history. At the age of 27 he received twelve injections of arsenic because of a venereal infection. Otherwise, apparently, he had been healthy.

On routine examination a year prior to hospitalization a positive serological test for syphilis (STS) was detected. X-ray examination of the chest showed findings suggestive of tuberculosis, Loeffler's Disease or Mycotic pulmonary infection. No tubercle bacilli, fungi or neoplastic cells were detected in a bronchial aspiration and the patient was permitted to proceed to Israel for further investigations.

The patient was in good general health

and had no subjective complaints. He had no cough or dyspnea. The physical examination revealed few palpable and movable glands in both axillae and a light emphysema of the chest. His body temperature was normal, the pulse regular 80 per minute, blood pressure 150/90 mm and the electrocardiogram normal. The pupils were equal, round and reacted normally to light and accommodation. The vision of the right eye was 5/7 and of the left 5/6. The ophthalmoscopic examination revealed pallor of the optic disc in the right eye, whereas in the left eye it showed pigmented chorio-retinal foci. There was no nystagmus. The superficial vibratory and positional sensations were not impaired. Examination of the cranial nerves revealed no pathology. The reflexes were normal and there were no pathological reflexes.

Laboratory Investigations

The Erythrocyte Sedimentation Rate (ESR) was 8/20 (Westergreen). Complete blood count, fasting blood glucose, urea, electrolytes, liver function tests and paper electrophoresis were all normal. Lupus Erythematosus (LE) cells were not detected in the peripheral blood. The C-reactive protein was ++. Rose Waaler and Latex fixation tests were negative. Stool and urine examinations revealed no pathological findings. Kveim test was negative and also the Mantoux test (1/1000), repeated on four occasions. During the previous 10 months spu-

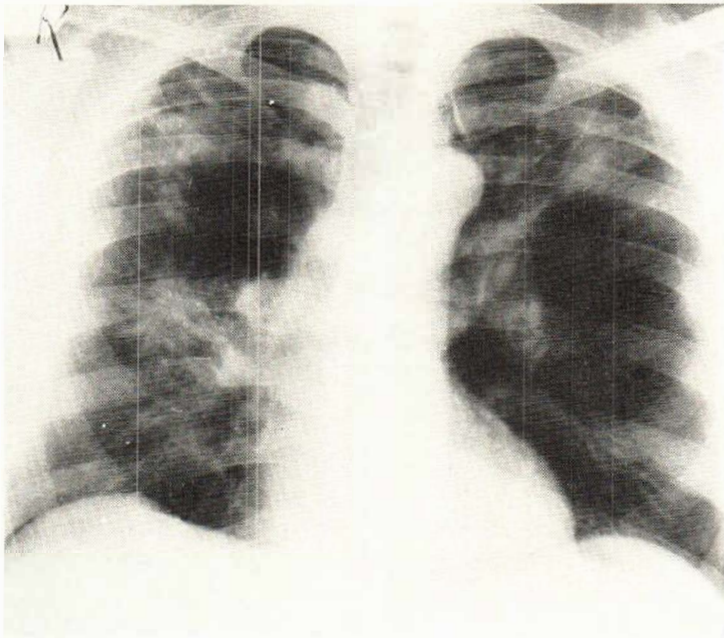


Fig. 1. An irregular infiltration in both upper lobes and in the middle field of the right lung. Overlaying the left pulmonary artery a round shadow is seen with a lucent centre suggestive of a granuloma.

tum, bronchial aspiration and gastric lavage had been examined and cultured several times. No tubercle bacilli, fungi, neoplastic cells or eosinophilic cells were detected. On the other hand, the STS revealed on several occasions the following findings:—V.D.R.L. + + +, Kolmer + +, Reiter Antigen + + and Wasserman + + +. The quantitative Wasserman test was positive in dilutions up to 1/16. The Treponema Immobilization Test (TPI) was positive. The cerebrospinal fluid was clear and revealed no pathological findings.

The bone marrow and scanning of the liver were normal. In prescalenus muscle biopsy free small lymph nodes were found. The histological examination of one of these nodes and of an axillary lymph gland revealed no pathology apart from slight increase of the reticulocytic cells. No signs of malignancy were detected in these glands.

X-ray Investigations

In August 1966 the X-ray examination of the chest revealed an irregular infiltration with fibrotic strands in both upper lobes

and in the middle field of the right lung. Overlaying the left pulmonary artery was a round shadow with a lucent centre. This shadow may be due to a granuloma, possibly with breakdown of the tissue (Fig. 1). The latter shadow was well demonstrated in Tomography in the layer "9 1/2" and "11". It looked as a round sharply defined mass overlaying the main left pulmonary artery. The infiltration of the left upper lobe was also noted (Fig. 2). Four months later and prior to treatment, the X-ray revealed a marked progress of the granulomatous lesions in both upper lobes and in the middle field of the right lung (Fig. 3). Both X-rays showed an overlapping of the right diaphragm.

The X-ray survey of the skull and bones of the upper and lower extremities revealed no pathology.

Course of Disease

The patient was treated with Aqueous Procain Penicillin, 1 million units daily for 22 consecutive days. During the treatment there was a temporary rise of the titre of

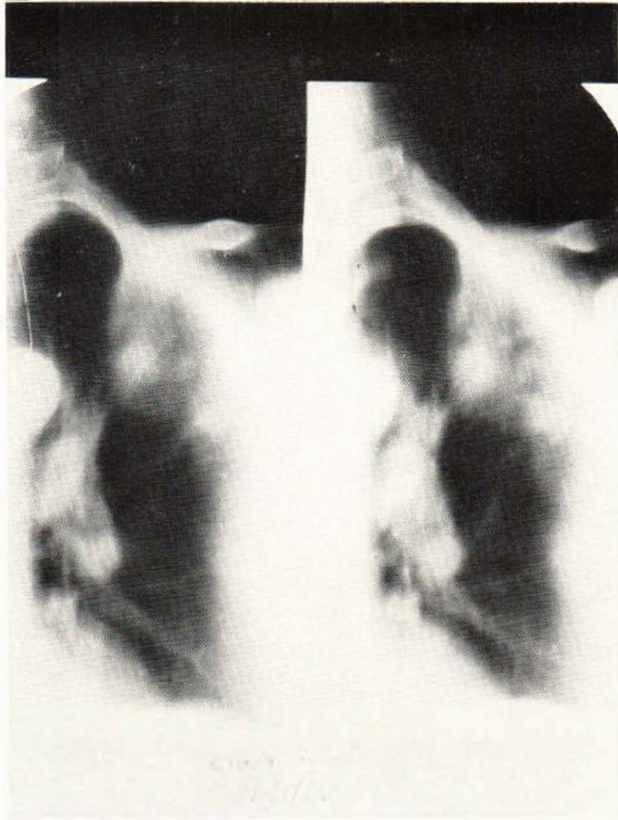


Fig. 2. Tomography in the layers 9 1/2 and 11 showing the round sharply defined mass overlying the main left pulmonary artery. The infiltration of the left upper lobe is also seen.

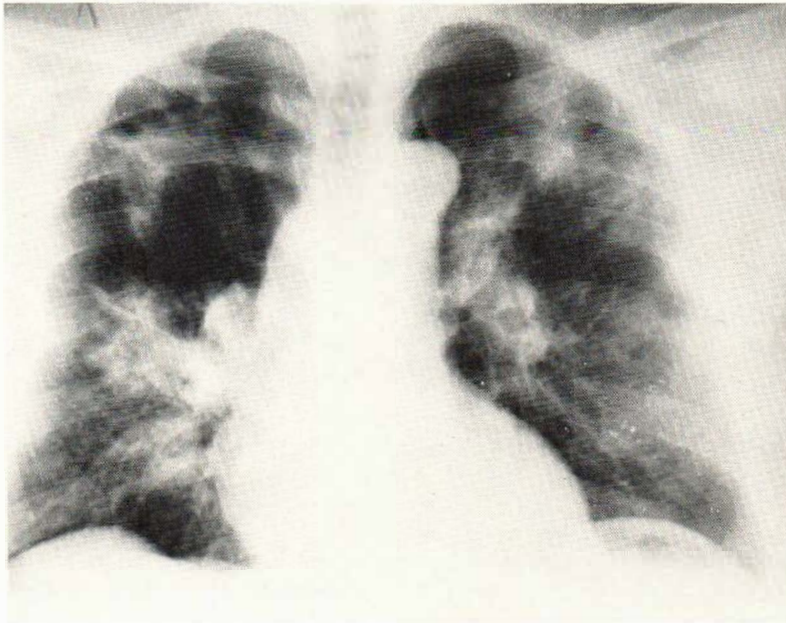


Fig. 3. X-ray examination four months later shows marked progress of the granulomatous lesions in both upper lobes and in the region of the right hilum.

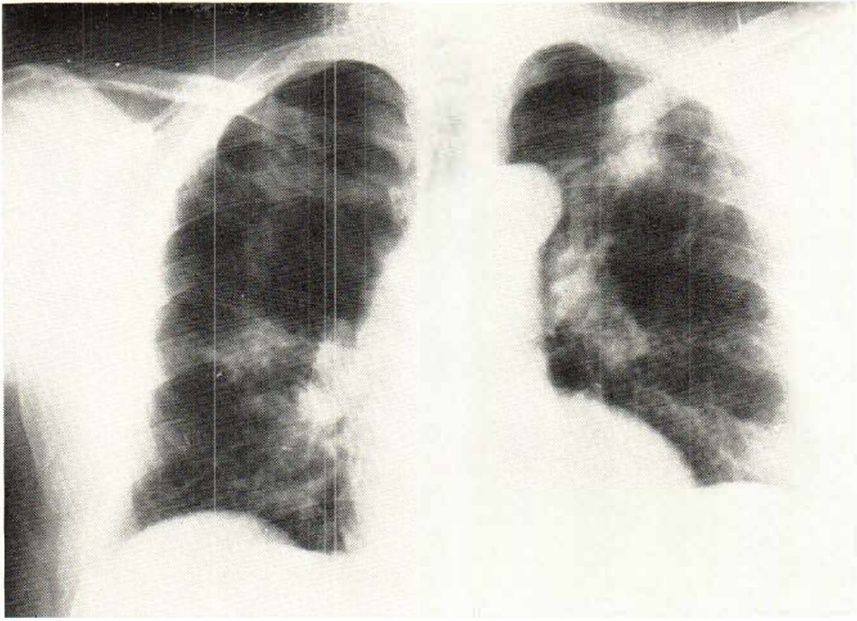


Fig. 4. One month after treatment there is diminution in size and density of the lesions.

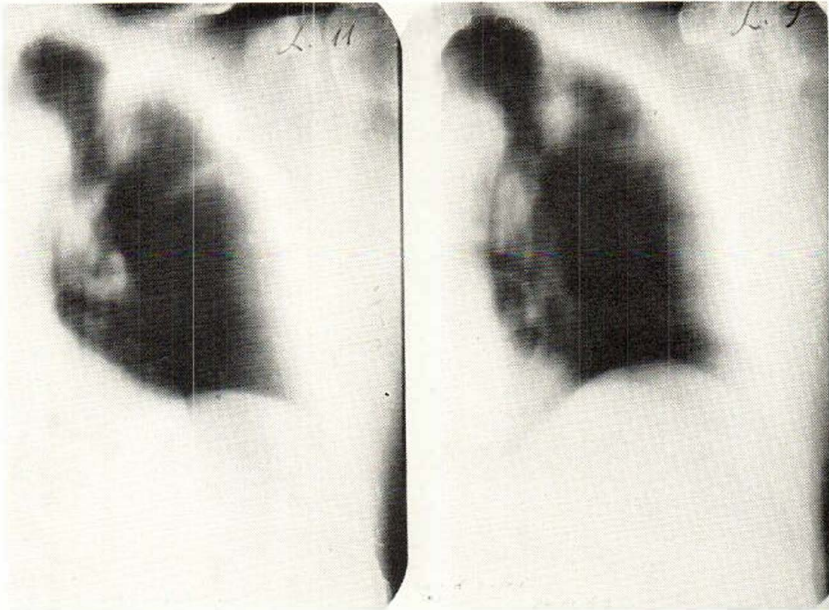


Fig. 5. The tomogram shows that the mass lesion in the previous tomogram has disappeared.

the Wasserman test and was positive in dilution of $1/32$. A month later the titre dropped to $1/4$ in dilution. The X-ray examination at this stage revealed diminution in size and in density of the lesions. The

shadow in the left hilum has almost disappeared (Fig. 4). The tomogram of the layer "9 1/2" and "11" demonstrated clearly the disappearance of the mass lesion previously seen (Fig. 5).

Discussion

Many doubts remain in attempting to establish a clinical diagnosis of syphilis of the lung since there is no precise clinical or radiological symptom complex in this disease. However, cases from large autopsy have been reviewed (2, 5) and criteria for clinical diagnosis have been suggested (3, 6). Royce (8) summarized diagnostic criteria and based on his summary we will attempt to discuss our case.

1. *History of syphilis*: The patient had a syphilitic infection at the age of 27 for which he received anti-syphilitic treatment.

2. *Signs and symptoms of pulmonary disease*: Apart from slight emphysema, no other sign was elicited and the patient had no symptoms suggesting a pulmonary disease. This is in keeping with the syphilitic manifestation of the lung in which the symptoms are usually mild or absent.

3. *Exclusion of other forms of pulmonary disease*: Perhaps much of the scepticism in the past regarding clinical diagnosis of pulmonary syphilis has been due to lack of thoroughness in ruling out other causes of pulmonary lesions (8). In our case, there were enough criteria to rule out the possibilities of acute infectious diseases, collagenic, parasitic, tuberculous, Loeffler's and the possibility of a neoplastic disease. Indeed the condition of the patient and the X-ray findings may simulate sarcoidosis in its bronchopneumonic infiltrative form, but the round lesion in the region of the left hilum points rather to the possibility of a gumma. In addition, no other signs of sarcoidosis were elicited in the bones, eyes, prescalenous biopsy and in the histological examination of the lymph nodes. The Kveim test was negative and the blood electrophoresis was normal.

4. *Serological test for syphilis*: Besides the positive T.P.I. the patient revealed persistently high titre of the Wasserman test, excluding the possibility of a biological false positive (B.F.P.) reaction (1).

5. *Demonstration of T. pallidum*: We were unable to demonstrate these organisms. This had been considered to be one of the criteria and cases have been reported following their detection (13, 11). Like in

other tertiary lesions *T. pallidum* can rarely be demonstrated in pulmonary syphilis. If spirochaetal organisms are demonstrated caution must be exercised since they are often unlikely to be *T. pallidum* (4).

6. *Radiographic evidence of pulmonary syphilis*: The radiological features in our case are suggestive of gummatous infiltrative form of pulmonary syphilis. It can be differentiated from tuberculus manifestation by the ill-defined infiltrative shadow with fibrotic strands distributed in several lobes and in both lungs. Loeffler's disease does not present fibrotic strands and the round opacity near the left hilum is not a feature of sarcoidosis.

7. *Therapeutic test*: This has been demonstrated in our case in a very convincing way. After treatment the titre of the Wasserman test dropped. There was marked concurrent absorption of the infiltrative pulmonary process and complete resolution of the round lesion (gumma).

8. *Presence of associated syphilitic lesion in other organs*: The patient revealed chorioretinal foci in his left eye suspected to be of a syphilitic nature.

The question of a pulmonary biopsy was raised, but was considered to be unjustified. Sufficient clinical and laboratory evidence was on hand to arrive at the diagnosis. It was considered unjustified to subject an apparently healthy patient to such a major procedure.

SUMMARY

Syphilis of the lung is today a rare finding. The absence of a precise clinical or radiological complex in this condition renders its clinical diagnosis uncertain. Nevertheless an asymptomatic case of pulmonary syphilis has been described. The case was first noticed on routine examination and was later proved to conform to all criteria for a clinical diagnosis of syphilis of the lung.

REFERENCES

1. Becker, S. W., and Obermayer, M. E.: *Modern Dermatology and Syphilology*,

- 1947, 2nd Ed., J. B. Lippincott & Co., Philadelphia, pp. 841, 863.
2. Hamilton, C. E., and Wexler, N. H.: *M. Rec.* 45: 508, 1937.
3. Hartung, A., and Freedman, J.: *J.A.M.A.* 98: 1969, 1932.
4. Howard, C. P.: *Amer. J. Syph.* 8: 1, 1924.
5. Lyons, C. G., Bregon, A. J., and Sewyer, J. G.: *Amer. J. Roentgenol.* 47: 877, 1942.
6. Pearson, R. S. B., and De Navasquez, S.: *Brit. J. Ven. Dis.* 14: 243, 1938.
7. Roessle, R.: *München Med. Wchschr.* 65: 36, 1918.
8. Royce, B. E.: *Ann. Int. Med.* 33: 700, 1950.
9. Schinz, H. R., Baensch, W. E., Friedl, E., and Uehlinger, E.: *Roentgen Diagnostic*, Amer. Ed., arranged by James Case, Grune and Stratton, 1953, p. 2542.
10. Shanks, S. G., and Kerley, P.: *A text Book of X-ray Diagnosis*, 3rd Ed. Vol. 2, Lewis & Co. Ltd., London, 1962, p. 636.
11. Smith, J. W., Laqueur, G. L., and Barnett, G. W.: *Amer. J. Syph.* 34: 383, 1950.
12. Spencer, H.: *Pathology of the Lung*, 2nd Ed., Pergman Press, 1963, p. 175.
13. Wilson, J. M.: *Ann. Int. Med.* 25: 134, 1948.