

EFFECT OF ULTRA-VIOLET LIGHT ON THE TEXTURE OF THE HUMAN SKIN DENOTING THE RELEASE PRESUMABLY OF CATHECHOLAMINES

A preliminary communication

J. ADAMS-RAY

The visible effects of ultra-violet light on human skin in the form of erythema appear after a latent period as a result of irradiation at wave-length < 314 nm (short-wave ultra-violet light) with two peaks at 250 and 297 nm. Extensive exposures give rise also to edema which has a smoothing effect on the skin-texture. Pigmentation after irradiation within these wave-lengths is also visible after a latent period.

Long-wave ultra-violet light (< 315 nm) has a very weak erythema-producing effect, but, on the other hand, a "direct" pigmenting effect. Ultra-violet light gives, however, rise to still another visible skin change, which appears not to have been described in the literature. The point of departure for the studies leading to this observation was the discovery that after ultra-violet irradiation the skin mastcells in hamsters (1, 2) producing and storing dopamine considerably increased their fluorescence (3). Preliminary results of an autoradiographic study also indicate the presence in the human skin of cells able to take up and concentrate L-dopa (15). Moreover, it was possible to observe an increase of free fatty acids in human blood after 5 minutes irradiation of the front side, indicating the liberation of a catecholamine (4).

After irradiation with a 200 W high pressure mercury lamp, the emission of which contains both short-wave and long-

wave ultra-violet light with a certain preponderance for the long-wave it was possible to observe, besides direct pigmentation, the following change in texture often visible to the naked eye but best seen with a magnifying glass:

The skin appears to be crumpled, with a deepening of the wrinkles. Wrinkles not previously visible are also observed, presenting a finely wrinkled appearance to the naked eye. Deepenings are sometimes seen in connection with the hair-follicles and occasionally pilo-erection. Stereophotography and stereomicroscopy show beautifully the difference in the texture before and after the irradiation. With stereo-photogrammetry the crumpling of the skin can be objectively shown. It may sometimes last for 24 hours. The change cannot be brought about by heat; nor does it appear on skin which lacks pilo-erectors. It is especially pronounced in areola mammae with its abundant smooth musculature. There is also seen an extension of the skin change especially in apical direction after 1-2 hours.

The phenomenon may also be brought about by intracutaneous injection of catecholamines and their precursor dopa and of a monoamin-oxidaseinhibitor (nialamid) which augments the amount of catecholamines; both noradrenaline and dopamine (5) occur in the skin.

In man the skin of the calf contains




Fig. 1. Skin A.) before and B.) after treatment with long-wave U.V.-light.

about 7 times as much noradrenaline as the skin of the epigastrium (6).

The decarboxylase inhibitor N.S.D. 1015 can block the formation of dopamine. When intracutaneously injected it gives in the skin of the epigastrium no reaction or a very slight one, but an intense pilo-erection as predominant symptom in the skin of the calf. The pilo-erection is inhibited by an α -receptor blocking agent (Regitin).

On the forearm there is a similar slight reaction on N.S.D. 1015 but after U.V. treatment as a predominant symptom intense pilo-erection.

The change in texture can also be caused by long-wave ultra-violet light alone.

A similar change in the texture of the skin has been described i.a. by Pfaundler (14), who in infants with thin skin observed on the thigh, applying mechanical stimulus to the abdomen, a "peau de chagrin" with fine wrinkles and small dimples ("rides très fines et des petites fossettes"). In older persons in whom the skin was from the outset slightly wrinkled André-Thomas (7) found, instead of pilo-erection, accentuation of the wrinkling ("fripement de la peau"). The phenomenon was explained on the basis of contraction of the smooth musculature in the skin.

Tomsa (16) reported that with a moderately strong stimulation of the pilo-erec-




Fig. 2. Effect of intracutaneous injection of N.S.D. 1015 on skin A) of the epigastrium B) of the calf.

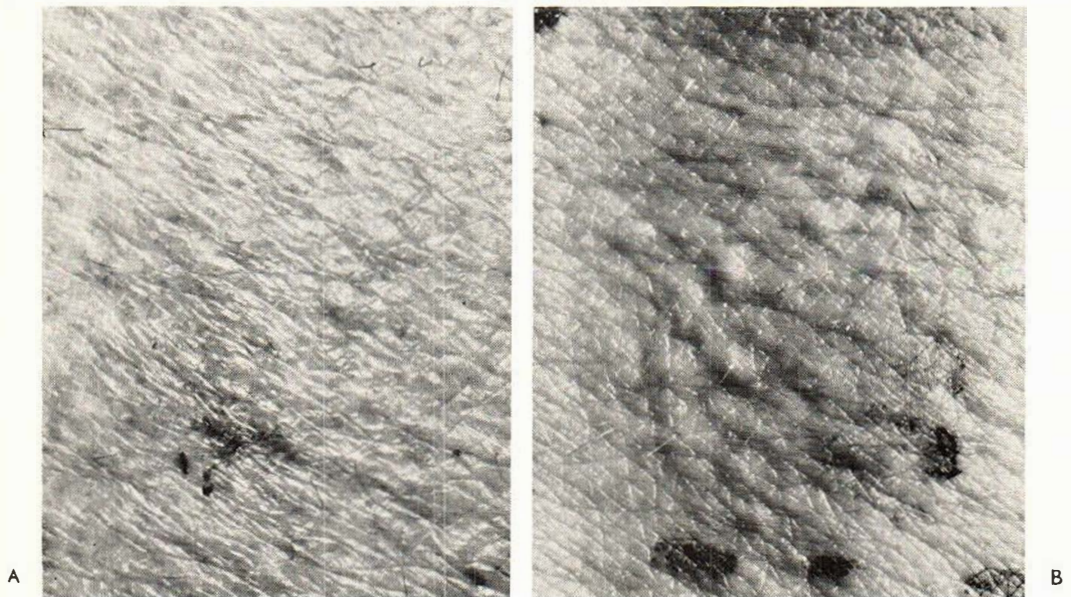


Fig. 3. Effect of intracutaneous injection of N.S.D. 1015 on skin of the forearm A) control B) U.V.-treated (long-wave).

tors no effect on the hair is produced. There is, on the other hand, a contraction and thickening of the skin.

It is further mentioned that in their studies of pilo-erection in healthy persons

Koenigsfeld and Zierl (10) observed that the pilo-erection was sometimes preceded by "eine feinste Fältelung der Haut".

A lowering of the temperature has also been described by van der Leun (11), and

a reduced circulation by Levan *et al.* (12) in the irradiated area during the latent period before the erythema. The liberation of a vasoconstrictor substance was discussed.

The change in texture observed appears only in skin regions where non-vascular musculature occurs, and can be explained as a result of its contraction. The findings indicate a release of catecholamines with their actions on smooth muscle.

Such substances can be produced from tyrosine in the skin in two ways. U.V.-light liberates tyrosinase—also the long-wave type according to Pathak *et al.* (13)—forming dopa, which can be decarboxylated into dopamine, which by hydroxylation can be transformed into noradrenaline. Also another mechanism is possible. Tyrosine can be decarboxylated into tyramin which *in vitro* can be transformed by U.V.-light (184–400 nm) into dopamine and noradrenaline (9). *In vitro* tyrosine is said to be transformed by such light into dopa (8).

A direct action on the connective tissue of the U.V.-light causing the wrinkling seems not very probable since the fibers of the connective tissue are relatively radiation resistant (17). Further the observed extension of the skin changes outside the borders of the treated area rather suggests a release of an active substance. Such a release in the skin may not only have a local effect but also other far-reaching biological effects. Preliminary results of biochemical studies seem to indicate a release of catecholamines in the U.V.-treated skin and an increased uptake of radioactive L-dopa in the above-mentioned cells after long-wave U.V. treatment.

Acknowledgements

The investigation was supported by grants from Nationalföreningen mot hjärt- och lungsjukdomar, Syskonen Wesséns Stiftelse, Emil och Wera Cornells Stiftelse.

REFERENCES

1. Adams-Ray, J., Dahlström, A., Fuxe, K. and Hillarp, N. Å.: *Exper.* 20: 1, 1964.
2. Adams-Ray, J., Dahlström, A. and Sachs, Ch.: *Acta physiol. scand.* 67: 295, 1966.
3. Adams-Ray, J., Dahlström, A. and Sandberg, G.: The effect of U.V. irradiation on the uptake of L-dopa in the mastcells of hamster ears. To be published.
4. Adams-Ray, J., Carlson, L., Dahlström, A., Häggendal, J. and Sandberg, G.: *Nord. Med.* 78: 1410, 1967.
5. Adams-Ray, J., Dahlström, A. and Häggendahl, J.: The dopamine content of human skin. To be published.
6. Adams-Ray, J.: *Acta Neuroveg.* 14: 283, 1956.
7. André-Thomas: *Rev. Neurol.* 33: 767, 1926.
8. Arnow, L.: *J. Phys. Chem.* 42: 415, 1938.
9. Ferrari, R. and Luduena, F.: *Arch. int. Pharmacodyn.* 156: 402, 1965.
10. Koenigsfeld, H. and Zierl, F.: *Deutsch. Arch. f. klin. Med.* 106: 442, 1912.
11. Van der Leun, J.: *Ultraviolet Erythema*. Thesis, Utrecht, 1966.
12. Levan, N., Hyman, Ch., Freedman, R. and Rohter, F.: *J. Invest. Derm.* 43: 451, 1964.
13. Pathak, N., Riley, F. and Fitzpatrick, T.: *J. Invest. Derm.* 39: 435, 1962.
14. Pfaundler, cit. by André-Thomas: *Le Réflexe pilomoteur*. Masson et Cie. Ed Paris 1921, page 7.
15. Ritzén, M. and Adams-Ray, J.: An autoradiographic study with Tritium-labelled L-dopa of the human skin. To be published.
16. Tomsa, cit. by Unna: *Ziemen Handbuch der spez. Path. u. Ther.* Leipzig, 1883.
17. Zollinger, H.: *Handb. d. allg. Path.* X 1. part. Springer Verlag, Berlin, 1960.