

## LEG ULCERS

A report of two cases caused by sarcoidosis

ROGER H. BRODKIN\*

### Introduction

The differential diagnosis of leg ulcers has grown to include a large number of systemic diseases as well as local infection, trauma, and neoplasms. It has been noted in recent presentations on leg ulcers (1, 2) that sarcoidosis has not been included among the granulomas producing leg ulcers and the literature on sarcoidosis does not specify leg ulcers as an initial cutaneous manifestation of this disease. Two cases of sarcoidosis are presented to illustrate this finding.

### Case Reports

Case I. The patient, a 52 year old negro female, was born in rural Georgia. There had been no significant illnesses until her first pregnancy at age 20 years when she developed a "burst blood vessel" in the right leg. This resulted in persistent swelling of the leg. A high saphenous ligation was performed twelve years later which relieved the swelling. During a thyroidectomy performed for hyperthyroidism three years after the first operation, a cut down was performed on the right leg for intravenous infusions. The cut down site failed to heal and a persistent nonsymptomatic ulceration developed in this area. During the next several years she developed a gradually spreading eruption on the legs and then the arms, neck, face and scalp. She described the lesions as "open sores" and only the

original ulcer on the right leg was mildly pruritic. The patient's only other complaint was asthma in childhood.

Physical examination revealed a wide spread eruption involving the extremities, neck, scalp, and face. The lesions were primarily slightly erythematous, hyperpigmented papules, many coalescing to form rings and plaques. The scalp showed a large irregular area of alopecia with atrophy and scaling. On the lower extremities were numerous ulcerations varying in size from 1 × 1.5 cm to 3 × 5 cm. They were roughly oval or irregular in shape with distinctly papular borders. The base of the ulcers consisted of moist, bright red granulation tissue or yellow-gray crusts (Fig. 1). Hepatosplenomegaly was also present.

Laboratory findings included normal CBC, urinalysis, sickle cell preparation, FBS, S.T.S., BUN, LDH and bilirubin. Serum Protein electrophoresis demonstrated: Albumin 2.5 (3.5-5.5),  $\alpha_2$  globulin 1.3 (0.54-0.93),  $\beta$  globulin 1.3 (0.64-1.06),  $\gamma$  globulin 2.8 (0.74-1.70). PPD #1 and 2 were negative. EKG was normal. Chest X-ray revealed prominence of the hilar areas and increased bronchovascular markings throughout both lungs. Liver scanning revealed hepatosplenomegaly and indicated diffuse parenchymal infiltrative disease. Skin biopsy of a lesion of the face and of the border of one of the leg ulcers both were interpreted as consistent with sarcoidosis (Fig. 2).

\* Assistant Clinical Professor of Medicine and Acting Director, Division of Dermatology, New Jersey College of Medicine and Dentistry.

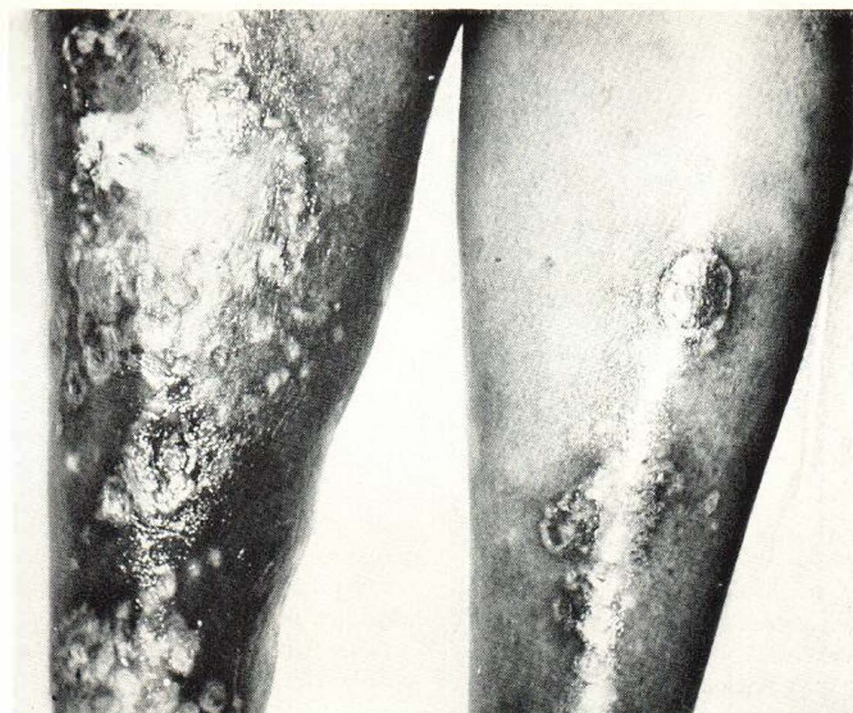

Fig. 1. Pretibial areas of Case I showing extensive leg ulcers. The borders are distinctly papular.

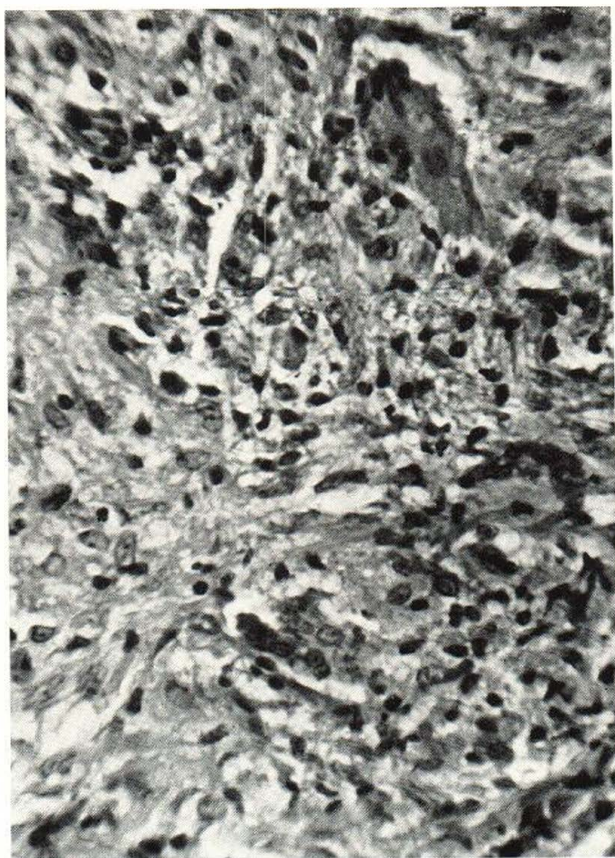


Fig. 2. Photo micrograph of biopsy of border of leg ulcer in Case I stained with H. and E., 500 $\times$ . Sheets of epithelioid cells are seen with giant cell formation.

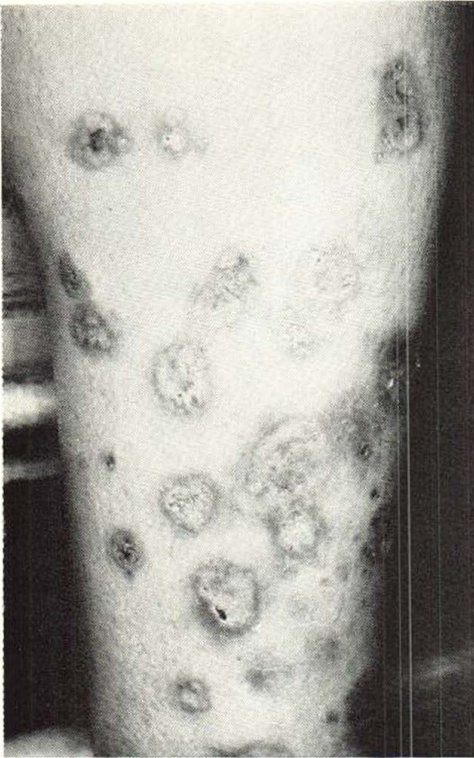

Fig. 3. Pretibial area of Case II. Note the hyperpigmented papular border of the ulcers.

*Case II.* The patient, a 24 year old negro female, was admitted to The Martland Hospital Unit of the New Jersey College of Medicine and Dentistry with complaints of a rash, shortness of breath and hemoptysis. She was born and raised in rural South Carolina. There had been no unusual illnesses or symptoms until about seven years before hospitalization when she developed asymptomatic "sores" on the legs and shortness of breath. A scalene node biopsy performed in South Carolina at that time was interpreted as sarcoidosis. Since that time she had been treated intermittently with small doses of steroids.

Physical examination on admission revealed no evidence of hyperadrenalism and no apparent distress at rest. Her cutaneous eruption was roughly symmetrical involving the lower legs and forearms. The individual lesions consisted of discrete and coalescent erythematous, hyperpigmented

papules which formed small plaques on the forearms. On the legs there were numerous plaques and ulcerations measuring 2-3 cm. in largest diameter, round or oval in shape, and with papular margins. The central areas of the plaques showed marked atrophy or ulceration with dry yellowish and hemorrhagic crusts (Fig. 3). She also presented marked hepatosplenomegaly and uveitis with chronic secondary glaucoma.

Laboratory findings disclosed a normal CBC, urinalysis, sickle cell preparation, FBS, BUN, S.T.S., electrolytes, CO<sub>2</sub>, L.E. preps., bilirubin, L.D.H. and Prothrombin time. The S.G.O.T. was 95 and the S.G.P.T. was 60. E.K.G. was normal. PPD # 1 and 2 were negative. Chest X-ray revealed a picture consistent with marked bilateral pulmonary fibrosis and several areas of emphysema. Biopsies of liver and the border of a leg ulcer were interpreted as compatible with sarcoidosis.

#### Comment

Sarcoidosis commonly involves the skin producing lesions of great variety and distribution. It has thereby earned the designation "great imitator". Ulcerated lesions are not uncommonly encountered and probably result from marked epithelioid cell proliferation in the dermis producing necrosis of the overlying epidermis rather than primary involvement of blood vessels.

In the first case the original presumed venous stasis may have provided a *locus minoris resistentiae* upon which plaques of sarcoidosis might be predisposed to ulcerate. In the second case, however, there was not detected peripheral vascular disease.

Sarcoidosis producing leg ulcers is probably not rare. It therefore deserves mention in the differential diagnosis of this important physical finding.

#### SUMMARY

In recent presentations sarcoidosis has not been listed among the granulomatous diseases producing leg ulcers. Two cases of sarcoidosis which began with ulcers of the

legs are now discussed to illustrate this finding. Sarcoidosis should be included in the differential diagnosis of leg ulcers.

#### REFERENCES

1. Roenigk, H. H. Jr., and Young, J. R.: Leg Ulcers-Differential Diagnosis and Treatment. *Exhibit at 26th Annual Meeting American Academy of Dermatology, 1967.*
2. Samitz, M. H. and Dana, A. S. Jr.: Cutaneous Lesions of the Lower Extremity. *Cutis*, Sept., Oct., Nov., 1966.

*Requests for reprints should be addressed to:*

Roger H. Brodtkin, M.D.  
40 Union Avenue  
Irvington, N.J. 07111  
U.S.A.