

## WOUND HEALING UNDER PLASTIC-COATED PADS

E. A. KNUDSEN AND G. SNITKER

Conflicting views are held on the importance of moisture in wound healing.

Using various experimental conditions Braun and Magazanik (2), Hinman and Maiback (4), Pories *et al.* (6), and Winter (11) found that occlusive dressing promoted wound healing, while exposure to air resulting in crust formation prolonged the healing time. In contradistinction, Schäffer (7) attributed to the crust a promoting function, and Smith *et al.* (8) observed a prolonged healing time when using occlusive therapy.

Plastic-coated, absorbent pads introduced a few years ago were advertised as follows: "Keeps wounds dry without sticking and speeds healing." Since it has been our impression that, on the contrary, occlusion with such pads inhibits wound healing, we investigated this matter. The wounds left by diagnostic punch biopsies were used in this study.

### Material and Method

The material comprises a total of 47 patients, selected at random, who had diagnostic punch biopsy. Five of the patients had two biopsies removed during the experimental period, so that the study comprises 52 wounds. Nine of the cases were diagnosed as psoriasis, 8 as benign or malignant tumours, 11 as dermatitis, while the

remaining 24 cases represented 16 different conditions.

The biopsies were removed with a 4 mm punch (in the face, however, with a 3 mm punch). In all cases it was attempted to get down into the subcutaneous fatty tissue.

Biopsies taken on even dates (a total of 26) were covered with a liberal-sized piece of plastic-coated pad<sup>1</sup> carefully fixed with adhesive tape. It was enjoined on the patients that the dressing was to be left until the wound had healed, and they were asked to take care not to wet it.

Biopsies taken on odd dates, also 26, were covered with an absorbent material<sup>2</sup> lightly fixed with a strip of adhesive tape. The patients were told to remove this dressing at the end of one—or exceptionally two—days and thereafter to leave the wound uncovered.

Both groups of patients were seen again not later than 7 days after the removal of the biopsy. In cases where the wounds had been covered with a plastic-coated pad the wounds were again covered in the same way and were kept thus covered until at one of the subsequent follow-up visits they had become completely covered with epidermis.

As a criterion of healing time, we took the time elapsing from the removal of the biopsy until the wound had just acquired a cover of epidermis. At this time there was frequently a small, thin, easily detached crust at the site of the wound.

<sup>1</sup> Telfa, Kendall Company, Chicago, U.S.A.

<sup>2</sup> Spongostan, Ferrosan, Copenhagen, Denmark.

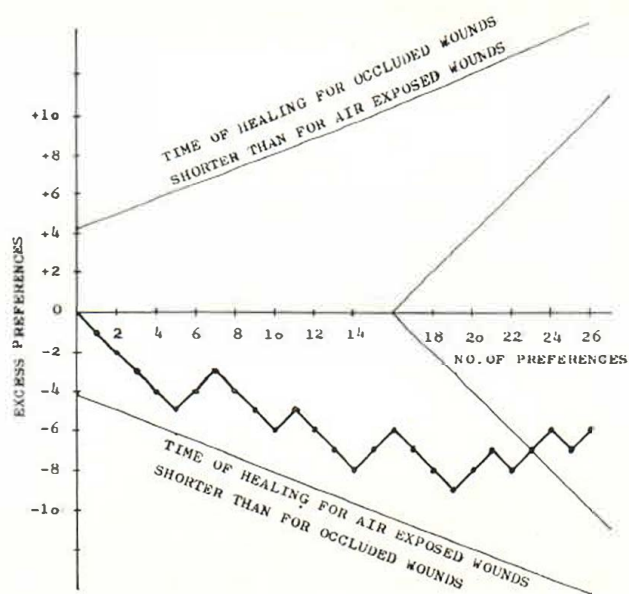


Fig. 1. Sequential clinical trial to compare the healing time for punch biopsy wounds treated under conditions of occlusion and by exposure.  
 $\phi = 0.85, N = 26, 2\alpha = 0.05, 1\beta = 0.95$  (Armitage 1960).

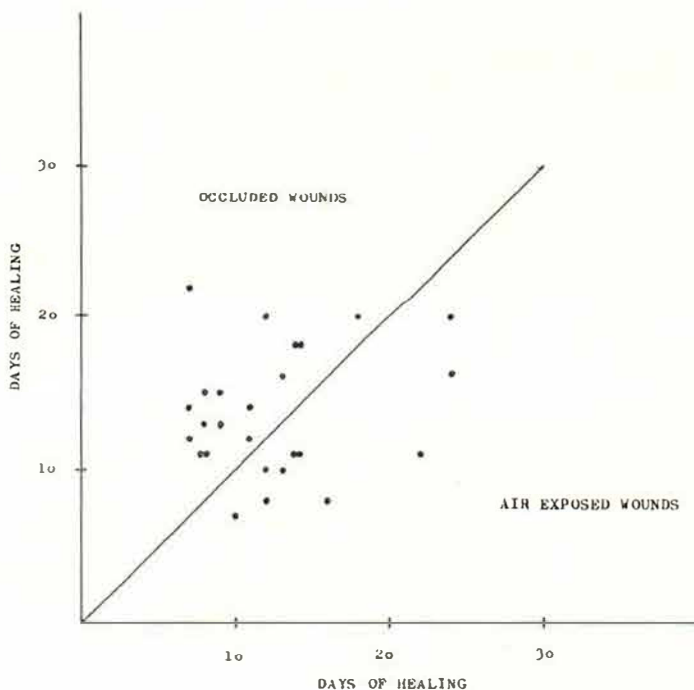


Fig. 2. Healing time for punch biopsy wounds from 26 patients treated under conditions of occlusion compared with wound healing time for similar biopsy wounds from another 26 patients treated by exposure. The dots are placed as one coordinate from each group. When the time of wound healing is longer for the former treatment, the dots are above the identity line, otherwise below it.

The two groups were comparable in respect to age, sex, diagnosis, and site of wound.

### Results

The constantly covered wounds healed in 8–22 days (mean 13.7 days), the air-exposed ones in 7–22 days (mean 12.5 days). The former were slightly macerated (but only exceptionally infected) and had no or only a loose crust during the healing period. The latter always got covered with a dry, firm crust. The findings were submitted to sequential analysis (1). From Fig. 1 it is apparent that the two therapeutic methods showed no difference in healing time.

In Fig. 2 the healing times are plotted in a coordinate system in relation to the identity line in such a way that wounds on the head-neck, trunk, arms and legs in one group are paired with wounds from the same regions in the other group. It may be seen that in 16 out of the 26 compared regions the healing time was longer for the occluded than for the exposed wounds, but the difference is not significant.

When considering the material as a whole, the average healing time for the 52 wounds was 13.1 days. When calculated by region, the head-neck wounds took an average of 9.9 days, the trunk wounds 12.1 days, the arm wounds 11.9 days, and the leg wounds 16.4 days to heal.

It was an incidental finding that in psoriasis the average healing time was 13.8 days, in the group of dermatitis 12.1 days, in the group of tumours 10.5 days (it should be mentioned that 4 out of the 8 tumour biopsies were from the head-neck or arms).

### Discussion

The physical-chemical mechanism of normal wound healing has been described in detail by several investigators (3, 5, 9, 10, 13).

In the present study we were interested only in the role of moisture and crusting respectively in wound healing. The crust

consists of fibrin, collagen, and white-cell debris (11, 13). According to Hinman and Maiback (4) and Winter (11) it delays epithelialization, as the epithelium from the marginal area has to grow at right angles to the skin surface in order to get beneath the crust. It has been hinted by Pories *et al.* (6) that the crust also inhibits another phase of wound healing, viz. wound contraction. On the other hand, Schäffer (7) believes that the crust promotes healing.

The role of hydration is apparent from the studies of Hinman and Maiback (4) who found that wounds induced by horizontal incision through the uppermost part of the dermis become more rapidly epithelialized under polyethylene occlusion than when exposed to air. Studying wounds in pigs Winter (11) found a similar effect of polyethylene. When he exposed the wound surface to drying, by a current of air of 20° and 40°C, he found epithelialization to be delayed. On the other hand, Smith *et al.* (8), treating ischaemic ulcers with gold leaf, aluminium foil, and polyethylene film, found the occlusion to inhibit epithelialization. Braun and Magazanik (2) found covering of the wounds of guinea-pigs with paraffin wax to promote epithelialization, while Schäffer (7), treating punch biopsy wounds in guinea-pigs, found petrolatum and several other ointment bases to delay the wound healing as compared with exposure.

In our study, we compared the effect of occlusion by plastic-coated pads with exposure treatment. In 16 out of 26 comparisons, the healing time was longer with occlusion than with exposure, but the difference was not significant. Thus, in the case of small, uninfected wounds like ours it seems immaterial whether the treatment is by occlusion or by exposure. However, the non-sticky property of the plastic-coated pads is considered to be an advantage.

### SUMMARY

Wounds caused by diagnostic punch biopsy were used for studying the role of plastic-coated pads in wound healing. There was

no difference in the healing time of wounds occluded by these pads and wounds treated by exposure.

#### REFERENCES

1. Armitage, P.: *Sequential Medical Trials*. Oxford 1960.
2. Braun, A. A. and Magazanik, G. L.: *Vopr. Kurort.* 4: 349, 1959 (cit. by Winter, G. D., ref. no. 11).
3. Dunphy, J. E. and Udupa, K. N.: Chemical and Histochemical Sequences in the Normal Healing of Wounds. *New Engl. J. Med.* 253: 847, 1955.
4. Hinman, G. D. and Maiback, H.: Effect of Air Exposure and Occlusion on Experimental Human Skin Wounds. *Nature* 200/1: 377, 1963.
5. Healing of Wounds. Leading Article. *The Lancet II*: 248, 1960.
6. Pories, W. J., Schear, E. W., Jordan, D. R., Chase, J., Parkinson, G., Whittaker, R., Strain, W. H. and Rob, C.: The Measurement of Human Wound Healing. *Surgery* 59/2: 821, 1966.
7. Schäffer, G.: *Effect of Ointment Base on Wound Healing*. Viborg. Thesis 1957 (in Danish).
8. Smith, K. V., Oden, P. W. and Blaylock, W. K.: A Comparison of Gold Leaf and Other Occlusive Therapy. *Arch. Derm.* 96: 703, 1967.
9. Vizian, C. B., Matoltsy, A. G. and Mescon, H.: Epithelialization of Small Wounds. *J. invest. Derm.* 43: 499, 1964.
10. Watts, G. T.: Wound Shape and Tissue Tension in Healing. *Brit. J. Surg* 47/2: 555, 1959/60.
11. Winter, G. D.: Comments for ref. 4. *Nature* 200/1: 378, 1963.
12. Winter, G. D.: In Montagna, W. and Billingham, R. E.: *Wound Healing*. Pergamon Press, 1964.
13. Zahir, M.: Formation of Scabs on Skin Wounds. *Brit. J. Surg.* 52: 376, 1965.