

ANGIOKERATOMA CORPORIS DIFFUSUM (FABRY'S DISEASE)

PASQUALE A. DILORENZO*, JEROME KLEINFELD**
WILLIAM TELLMAN*** AND LESTON NAY****

Angiokeratoma Corporis Diffusum (ACD)—an hereditary disorder with multisystem involvement—apparently results from an aberration of lipid metabolism. The purpose of this paper is to present a patient with this rare disease and to review briefly its systemic and cutaneous manifestations.

Case Presentation

A 34-year old man was initially hospitalized in October, 1964 at the Grand Island Nebraska Veterans Administration Hospital, following an episode of slurred speech and weakness involving both legs. Physical and neurological examination at that time revealed left-sided hyperreflexia, sustained left ankle clonus and an upward toe sign on the left as well as nystagmus and ataxic speech and gait. A diagnosis of brain stem hemorrhage was made. Subsequently, he was hospitalized several times for physical therapy, but had no new neurological symptoms. In 1966 he was transferred to the Denver Veterans Administration Hospital.

Since late childhood the patient had been aware of the presence of multiple lesions in the skin of his lower trunk and upper

thighs. These lesions were asymptomatic and appeared to be slowly increasing in number. There was no history of intolerance to temperature extremes. No one in the family is known to have had similar skin lesions and examination of available relatives revealed none. There was also no family history of renal disease, but one paternal aunt had had a cerebral vascular accident and myocardial infarction at the age of 41. The patient's father died in his early thirties as a result of cerebral hemorrhage incurred while playing football. The patient has two younger brothers, both in good health and without skin lesions.

Physical examination on admission to Denver Veterans Administration Hospital in August, 1966 revealed a lean young man with normal vital signs. Scattered over the lower trunk, upper thighs, scrotum and penis were multiple small rust-colored to violaceous punctate papular lesions with overlying hyperkeratosis. Similar lesions were present on the mucous membrane of the lower lip. A Grade II/VI early diastolic murmur and a short midsystolic Grade I/VI murmur were audible along the left sternal border, with radiation to the left axilla. An ejection click was also present. There was

* Resident in Dermatology, University of Colorado Medical Center, Denver, Colorado, U.S.A.

** Resident in Ophthalmology, University of Colorado Medical Center, Denver, Colorado, U.S.A.

*** Resident in Internal Medicine, University of Colorado Medical Center, Denver, Colorado, U.S.A.

**** Chief, Department of Neurology, Veterans Administration Hospital, Denver, Colorado, U.S.A.

Studies leading to this report were supported in part by USPHS Training Grant #AM-05527. Division of Dermatology, University of Colorado Medical Center, Denver, Colorado, U.S.A.

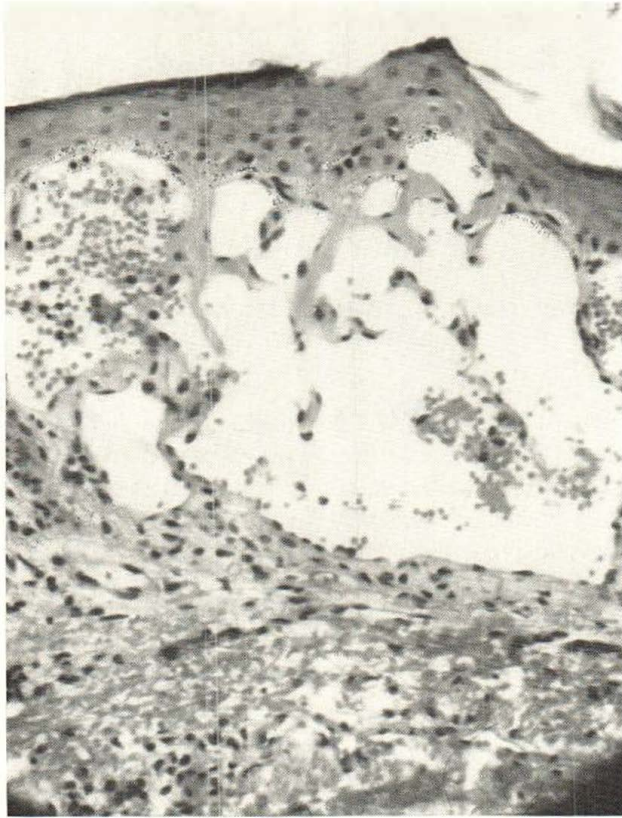


Fig. 1. Dilated blood vessels in the dermis with overlying hyperkeratosis.

no opening snap or gallop. The peripheral pulses were normal. The abdomen was flat, soft and without palpable organomegaly. Examination of the extremities revealed the left calf and thigh to be 1 cm smaller in circumference than the right. The patient complained of pain over the medial aspect of the left knee after internal or external rotational stress.

Neurological examination revealed cranial nerves 1 to 12 to be intact, except that there was sustained bilateral nystagmus at rightward gaze, and a minimal jawjerk and suck reflex. There was an increase in muscle tone of the left upper and lower extremities, with weakness of the left lower extremity. Ataxia was present in the left extremities. The deep tendon reflexes were hyperactive, with those of the left lower extremity more active than those on the right. The Babinski response was plantar bilaterally. The patient's gait was ataxic and somewhat spastic with circumduction

of the left lower extremity. Sensory nerve function and mental status were normal.

Cardiology consultants felt that the patient's heart murmur was the result of mild aortic insufficiency and aortic stenosis, either secondary to rheumatic heart disease or congenital bicuspid aortic valvular disease.

Ophthalmological evaluation revealed a visual acuity of 20/20 in both eyes without correction. The intraocular pressure was normal by Schiötz tonometry and the visual fields were also normal. There was a bilateral horizontal end point nystagmus, greater upon gaze to the left. Cover testing revealed a 10 prism diopter alternating exotropia at near and orthophoria at distance. No dilatations or aneurysms of the conjunctival vessels were present and the arterioles were normal. Corneal sensation was normal. The anterior chambers were normal with a pupillary membrane remnant in the right eye. The lenses were un-

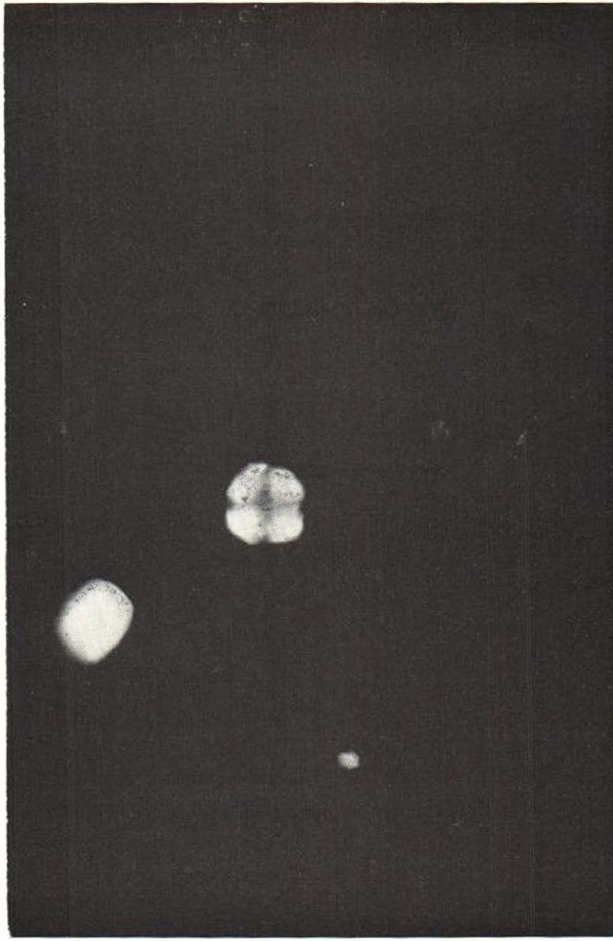


Fig. 2. Birefringen "Maltese Cross" in urinary sediment (polariscopic photomicrography).

remarkable. Fundiscopic examination revealed normal discs with sharp borders. The venules were very tortuous and even pig-tailed or corkscrew-like in areas. The arterioles and maculae were normal.

The admission hematocrit was 42 %, the white blood cells numbered 11,100 per cu mm, with a normal differential count. The platelet count was 370,000 per cubic millimeter, and the reticulocyte count 1.5 %. The urine was normal except that in one specimen, double refractile lipid bodies were seen in the sediment when it was examined in polarized light. The total 24 hour urine protein was 19 mg% and urine osmolarity 616 and 640 milliosmols on two separate occasions, without abstinence from water. Creatinine clearance was 114 mg/cc per minute. The serum creatinine level was

1.1 mg%. Blood urea nitrogen 14 mg%, uric acid 6.3 mg%, serum cholesterol 220 mg%, total serum protein 7.35 grams%, with albumin 4.41 grams%, alpha 1 globulin 0.1 grams%, alpha 2 globulin, .98 grams% and beta globulin 0.79 grams% and gamma globulin 1.08 grams%. A 4 hour glucose tolerance test was normal. The VDRL was not reactive.

Lumbar puncture revealed normal opening pressure and the cerebrospinal fluid was clear. It contained six cells per cubic millimeter of which three were polymorphonuclear leukocytes and three lymphocytes. Spinal fluid sugar measured 52 mg%; protein, 44 mg%, chlorides 120 mEq per liter and globulin 1+.

Bone marrow from the right iliac crest revealed a 40 : 60 marrow cell to fat cell

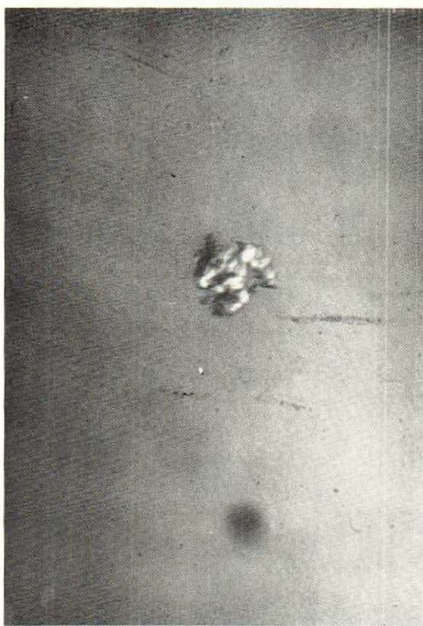

Fig. 3. Mulberry cell (degenerated macrophage) in urinary sediment.

ratio with a myeloid: erythroid ratio of 2 to 1. The cells appeared normal and no lipid filled macrophages were seen. On three occasions the stools were found to contain no occult blood, and biopsy of the rectal mucosa revealed no angiomatous vascular dilatations or foam cells. Biopsy of several of the cutaneous vascular lesions demonstrated dilated blood vessels in the dermis and lower epidermis with some overlying hyperkeratosis (Fig. 1). Vacuolated areas were also seen in the media of the blood vessels. Sudan Black B staining revealed doubly refractile bodies in the blood vessel walls when viewed with polarizing lenses.

The electrocardiogram indicated left ventricular enlargement but no other abnormalities. The electroencephalogram and chest, heart and skull roentgenograms were normal.

At the time of his discharge, the patient's gait had improved. There was no evidence of progression of his disease during the two months he was under our observation in the hospital.

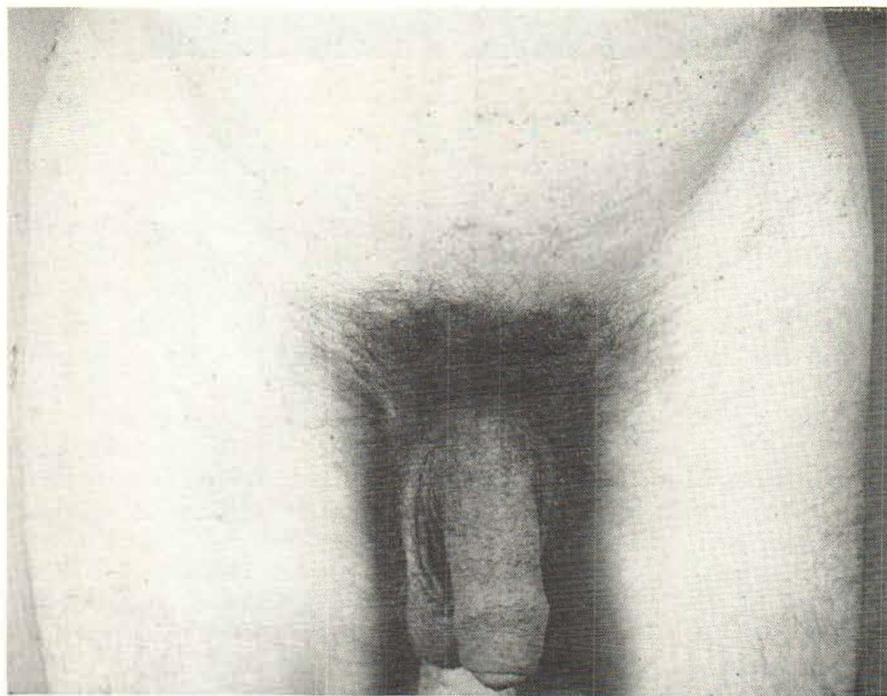

Fig. 4. Characteristic bathing trunk distribution of skin lesions.

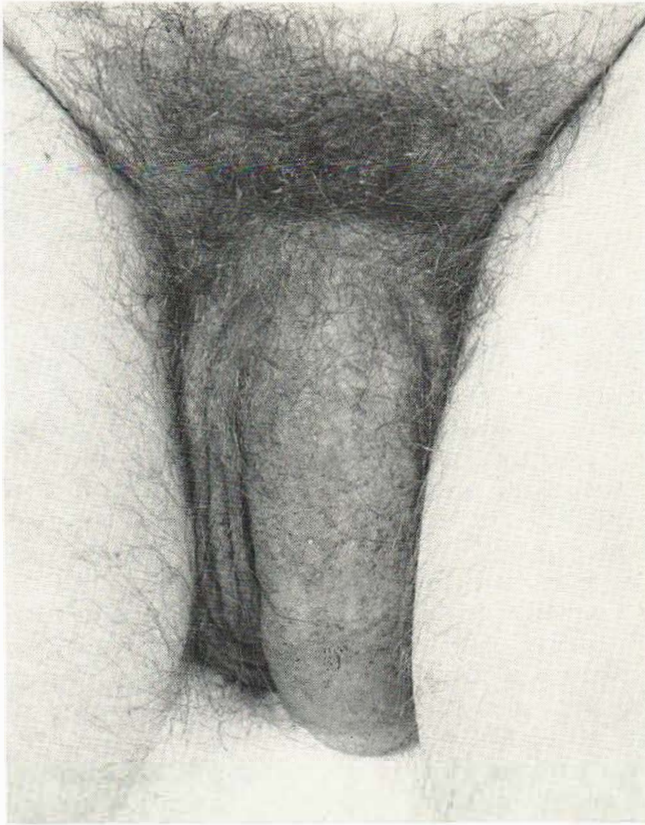


Fig. 5. Angiokeratomas on the shaft of the penis.

Discussion

The initial cases of ACD were described by Fabry and Anderson in 1898. Subsequently, other cases have been described with varied clinical manifestations. In 1947 Pompen reported the first two autopsied cases.

A substance identified as ceramide trisaccharide, birefringent under polarized light and stainable with Sudan Black B has been demonstrated in the media of the blood vessels of various organs, including the heart (5), kidney, brain and skin. This substance has also been found in the reticulo-endothelial cells of such organs as the adrenals, lymph nodes, spleen and liver (4). Macrophages filled with a lipid substance have been demonstrated in the bone marrow and urinary sediments where they appear as maltese cross figures (Fig. 2) and mulberry cells (Fig. 3) (2). In paraffin sections the lipid has been removed, leaving vacuolated areas.

The cutaneous lesions, while not affecting the patient's health or longevity, are of paramount importance, in that they are the clinical manifestation which usually leads to correct diagnosis (Fig. 4). Angiokeratomas of Fabry's type are typically located in greatest numbers on the genitalia (Fig. 5), the lower trunk, and thighs. The mucous membranes of the mouth may also be involved. Angiokeratomas usually appear early in childhood but may increase in number during the pubescent period, and in some cases have been known to slowly multiply during the ensuing years as well. In addition to the cutaneous angiomas, hypohidrosis, anhidrosis and/or relatively dry mucous membranes may be present.

The ophthalmologic manifestations of ACD were first reported by Weichsel in 1925 (7). He described two brothers with varicosities of the conjunctival vessels, marked tortuosity and variation in the caliber of the retinal vessels, and corneal opaci-

ties. The corneal lesion is the only ocular manifestation which is diagnostic. It is seen in both males and females and may be the only sign in the carrier female. The cornea shows a gold-colored epithelial haze which may be diffuse or localized in a whorl-like or wedge-like pattern. This haze starts peripherally and does not involve the central cornea (Fig. 6). It can be detected only with the aid of a slit lamp and is best seen by diffuse retroillumination. The epithelium is intact and does not stain with fluorescein. The corneal opacities are not dense enough to affect vision. Corneal sensation is normal. Grace (3) has noted endothelial pigmentation in two of his ten patients, however, this may be a coincidental finding.

Wallace in his post-mortem study of a patient who had corneal opacities noted thickening of the corneal epithelium due to edema and hyperplasia of the cells (9). Corneal epithelium was removed for histologic study in our patient. Microscopic examination was unremarkable. The regenerated epithelium initially was clear, however, it began to develop a golden haze approximately three months later.

Vascular changes may occur in both the tarsal and bulbar conjunctiva, they are bilateral but not necessarily symmetrical. Grossly the vessels are tortuous and may have a beaded configuration. Closer examination reveals focal dilatations along the venules. The arterioles are normal. There may be stagnation of blood flow peripherally.

The retinal vessels are dilated and markedly tortuous, with extreme spiralling in some cases (Fig. 7). The venules are involved more than the arterioles. The engorged venules and blurred disc margins have been erroneously interpreted as papilloedema. In advance stages of the disease, hypertensive retinal changes characterized by arteriolar narrowing, arteriolar spasm, hemorrhage and exudation may also be seen.

In 1958, Colley and his colleagues described the renal histologic abnormalities characteristic of this disease. They consist of vacuolation of the epithelial cells of the

glomerular tufts, distal convoluted tubules and loops of Henle, with sparing of the proximal convoluted tubules. Areas of cortical and glomerular fibrosis are noted, and involvement of the interlobular arteries, with edematous thickening of the intima and vacuolation of the media. In two of Pompen's patients, both of whom died in uremia, advanced degenerative changes were noted in the kidneys, with extensive hyalinization and fibrosis of the renal parenchyma. Thus a pathologic progression may occur in the kidneys, beginning with lipoid accumulation in the glomeruli, tubules, and media of blood vessels, and progressing to extensive destruction of renal tissue.

Hypertension is frequent; it is apparently secondary to renal disease. Cardiomegaly has been reported in the majority of cases. Paroxysmal pain, characteristically located in the toes, fingertips and glans penis is present in many patients. Attacks of pain seem to be more frequent in an extremely hot or cold environment. Neurologic involvement has been demonstrated in about 10% of cases. In 4 of 21 cases described by Wise and colleagues in 1962, sudden strokes occurred. Other frequent symptoms are edema of the lower extremities, aches in various muscles and joints, attacks of pyrexia, dizziness, headache, and weakness. It is unusual for these patients to have prolonged periods of well-being (8).

Fabry's disease occurs chiefly in males, and no cases have been reported in Negroes. Transmission from father to son has not been documented. Thus a sex-linked recessive inheritance has been postulated. The few occurrences reported in females suggest that the fault may show occasional penetrance in the heterozygous female, and constant penetrance in the heterozygous male (6). The hereditary defect in lipid catabolism whereby an excess of ceramide trisaccharide is accumulated and stored is believed due to a profound deficiency or absence of ceramide trisaccharide clearing enzyme (REF). Such an enzyme deficiency was noted by Brady *et al.* in preliminary experiments on intestinal preparations (1).

Treatment at present is unsatisfactory. Cortisone, estrogen, vitamin K, vasocon-

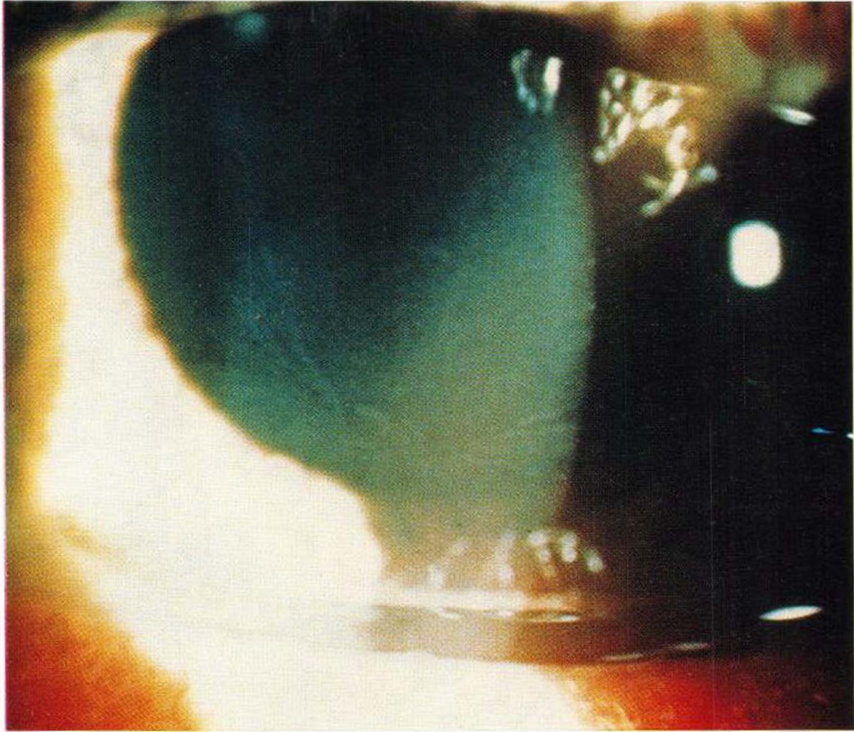


Fig. 6. Bronze-colored whorl-like pattern in the corneal epithelium.

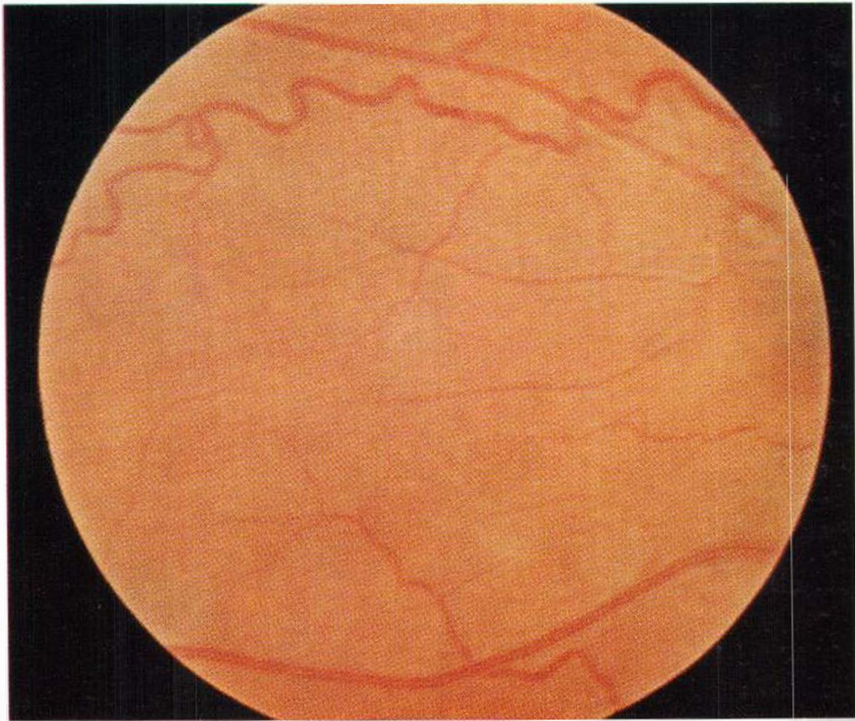


Fig. 7. Right fundus showing venous tortuosity. Note cork screw-like dilation of blood vessels.

strictors, vasodilators, antihistamines, chlorpromazine, reserpine and cobra venom have all been tried, with equivocal results. Protection from extremes of temperature should be attempted. If significant hypertension is present, reduction of blood pressure may be beneficial. The average age of death was 42 years.

SUMMARY

A patient with Fabry's Disease whose initial internal manifestation appeared as a cerebral vascular accident has been presented. Recognition of the cutaneous lesions lead to the correct diagnosis. The multisystemic involvement and pathogenesis of this disorder are discussed.

REFERENCES

1. Brady, R. O., Gal, A. E., Bradly, R. M. and Martenson, E.: The Metabolism of Ceramide Trihexosider. *J. Biol. Chem.* 242: 1021-1026, (March) 1967.
2. Von Gemmingen, G.: Angiokeratoma Corporis Diffusum. *Arch. Derm.* 91: 206-218, (March) 1965.
3. Grace, E. V.: Diffuse Angiokeratosis. *Amer. J. Ophthalm.* 62: 139, 1966.
4. Hartley, M. W.: Dysphospholipids in Fabry's Disease: A Light and Electron Microscopic Study. *Ala. J. Med. Science* 1: 361-367, (October) 1964.
5. Leder, A. A. and Bosworth, W. C.: Angiokeratoma Corporis Diffusum Universale With Mitral Stenosis. *Amer. J. Med.* 88: 814-819, (May) 1965.
6. Opitz, J. M.: The Genetics of Angiokeratoma Corporis Diffusum and Its Linkage Relations With the XG Locus. *Amer. J. hum. Genet.* 17: 325-342, (July) 1965.
7. Rahman, A. N.: The Ocular Manifestations of Hereditary Dystopic Lipidosis. *Arch. Ophthalm.* 69: 708, 1963.
8. Wachtel, H. L. and Mattei, I. R.: Angiokeratoma Corporis Diffusum Universale. *Arch. intern. Med.* 114: 805-811, (December) 1964.
9. Wallace, H. J.: Angiokeratoma Corporis Diffusum. *Brit. J. Derm.* 70: 354, 1958.

Requests for reprints to:

P. A. DiLorenzo, M.D.
 Division of Dermatology
 University of Colorado Medical Center
 4200 East Ninth Avenue
 Denver, Colorado 80220, U.S.A.