

MALIGNANT DEGENERATION OF SKIN LESIONS IN EPIDERMODYSPLASIA VERRUCIFORMIS

M. RUITER

In a previous study we reported a characteristic case of Epidermodysplasia Verruciformis (E.V.), demonstrating the presence of an intranuclear virus by means of electron microscopy (7). The patient was a 22-year-old man, institutionalised elsewhere because of imbecility. His skin condition reportedly commenced at the age of seven and the changes were very extensive. Besides skin lesions the patient showed a number of congenital changes (dystrophy of the nails of both hands and feet, bone deviations, etc.). Congenital anomalies also appeared to occur frequently in his family.

The virus was found in four skin biopsies (breast), which all showed a histological picture typical of E.V. The histological changes observed in E.V. lesions are characterized by nests of large clear cells within the epidermis (Fig. 1).¹ The lesions in which virus was found all showed this picture. The virus was demonstrated both in ultra-thin sections and in the supernatant of finely ground tissue. It proved to be identical or closely related to the virus of common warts. The presence of this virus in humans usually causes only benign acanto-papillomas, viz. common warts. It is therefore remarkable that in E.V. there is a marked tendency—according to Touraine in 27% of the cases—to malignant degeneration of the original lesions (8). More-

over, as a rule, these malignant changes already develop at an early stage (\pm 20 years). This was also the case with the present patient, in which lesions suspected of being malignant and covered with haemorrhagical crusts were observed on the forehead. In the present study the histopathological changes observed in such lesions are described and discussed. The histological examination was carried out on biopsies from these lesions.

The picture was found to be as follows:

The epidermis is much broadened by irregular acanthosis; the rete ridges are elongated and thickened to such a degree that the papillae located between them are reduced to thin strands. The stratum corneum has been replaced by fibrin or occurs in the form of parakeratosis. In the stratum spinosum bands of large clear cells are found with a partly vacuolized homogeneously stained cytoplasm and large irregular nuclei (Fig. 2). These bands extend downwards nearly from the parakeratotic layers to the underlying dermis and are embedded in the broadened epidermis. In the deeper-lying parts of these bands the clear cells show a tendency to individual keratinization and atypicity (Fig. 3). Between the bands of clear cells there are areas of more basophilic cells showing disorderly arrangement, atypicity with several mitoses and hyperchromatic nuclei often containing 2 or 3 nucleoli (Fig. 4). Here a few scattered cells show individual keratini-

¹ These histological characteristics are in our experience not equally pronounced in all E.V. lesions. They were much less apparent in a lesion (old?) on the back of the hand of the same patient.

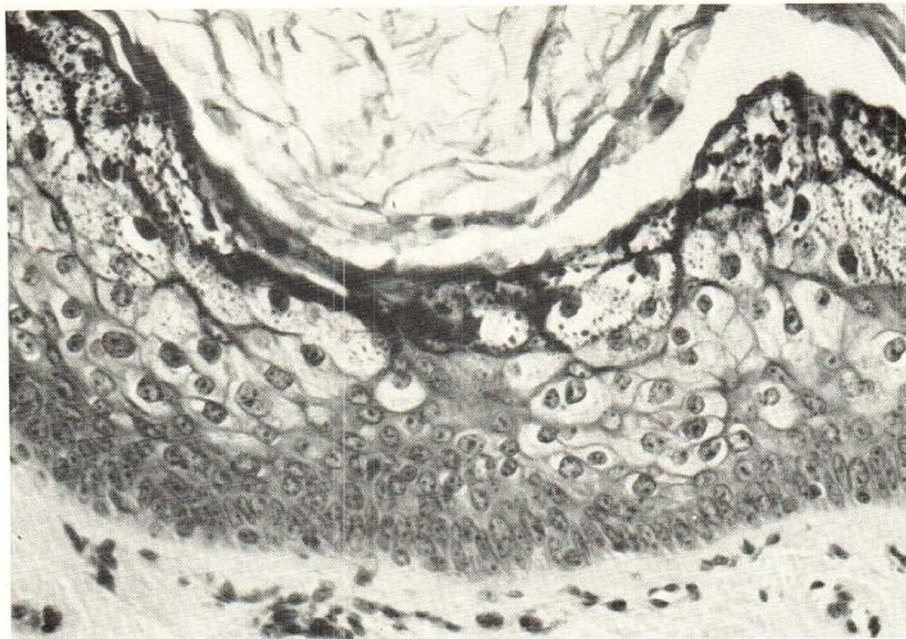


Fig. 1. Histology of a typical lesion on the breast. In the epidermis nests of large clear cells containing in the more superficial layers many keratin granules.

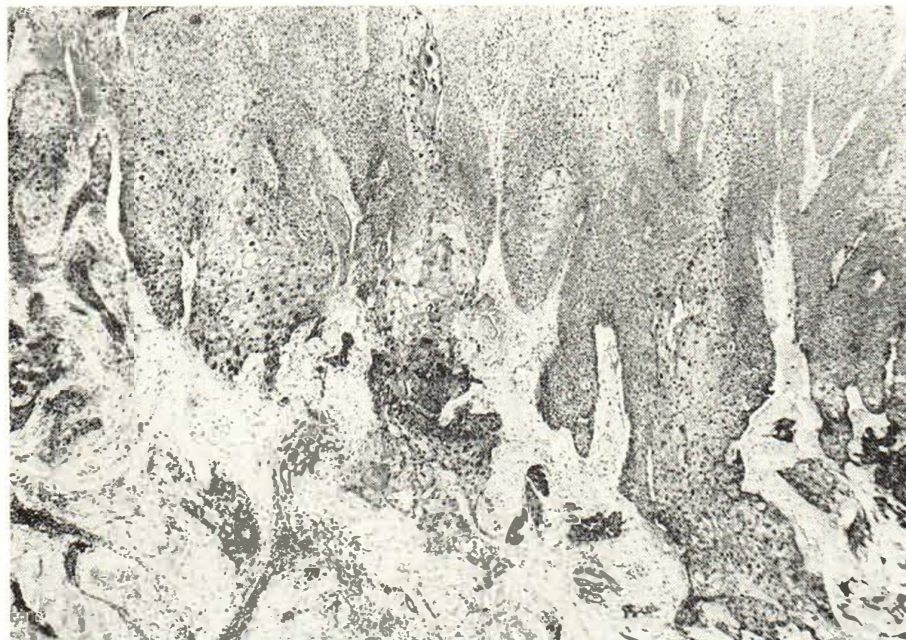

Fig. 2. Panoramic view. Papilloma-like proliferation of the epidermis showing many atypical cells. Between darker areas broad columns of clear cells are seen extending into the underlying dermis.

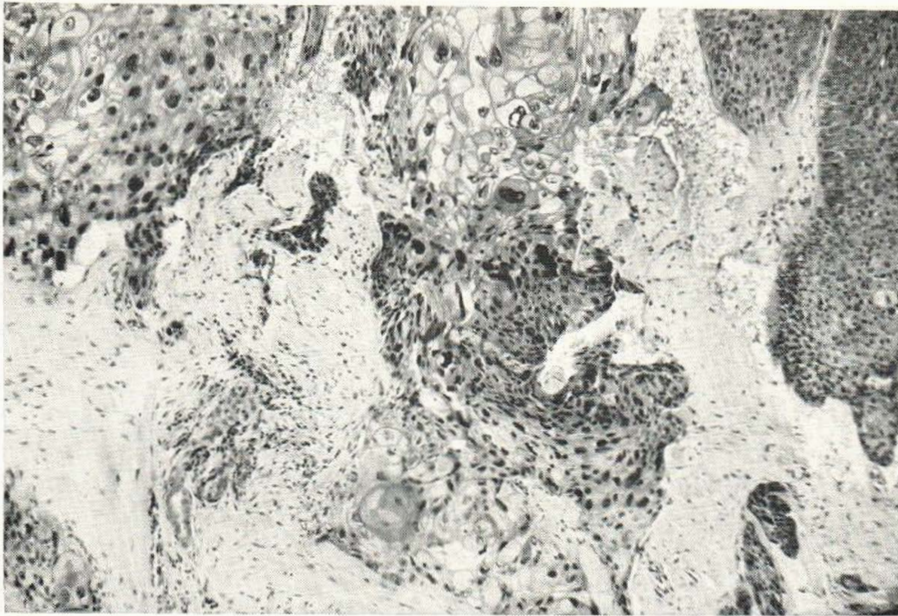


Fig. 3. Lower part of the proliferated epidermis. The cells of the rete Malpighii occur in a disorderly fashion, many of them are atypical. Also some of the clear cells (at the bottom) show atypicality. In the dermis a group of cells showing individual keratinization and incomplete horn pearl formation.

zation while incipient horn-pearl formation occurs locally. In addition there are seen in the dermis irregular groups of epithelial cells of various shape, which show atypicity and a rather pronounced tendency to individual keratinization, suggesting an invasive character of the epidermal changes (Fig. 2 and 3). In the upper layers of the dermis there is a moderate, chiefly perivascular inflammatory infiltration mainly of lymphocytes and plasma cells. A diagnosis of bowenoid carcinoma was made.

Some investigators are of the opinion that the malignant degeneration of skin lesions in E.V. is overemphasized and may be coincidental (5). We do not agree with this. Thus the early age at which malignant degeneration of lesions in E.V. is observed, is quite unusual. In addition the uncommon type of carcinoma or pre-carcinoma revealed by the histo-pathological examination is noteworthy. It appears from recent publications that such findings are not at all unusual for malignant degeneration of E.V. lesions. Jablonska *et al.* (4) already drew

attention to the remarkable histological picture observed in two patients. They also pointed out the similarity of their findings with those in Bowen's disease. Histopathological pictures completely identical to ours were also recently described by Oehlschlaegel *et al.* (6) in malignant degeneration of E.V. lesions of a patient who later died of metastases from a typically planocellular carcinoma. Finally, the opinion of Andrade (1) should be mentioned, namely that skin lesions in E.V. keep their own histological character when malignant degeneration occurs (epithelioma epidermodysplasique). In our own microscopical examination histological changes were found, which also closely resembled those of Bowen's disease. In addition a tendency to invasive growth was observed in some areas which suggests a transition to planocellular carcinoma. A conspicuous histological feature was the presence of bands of large clear cells extending downward from the upper layers of the thickened epidermis. In the upper parts of these bands of clear cells the latter were

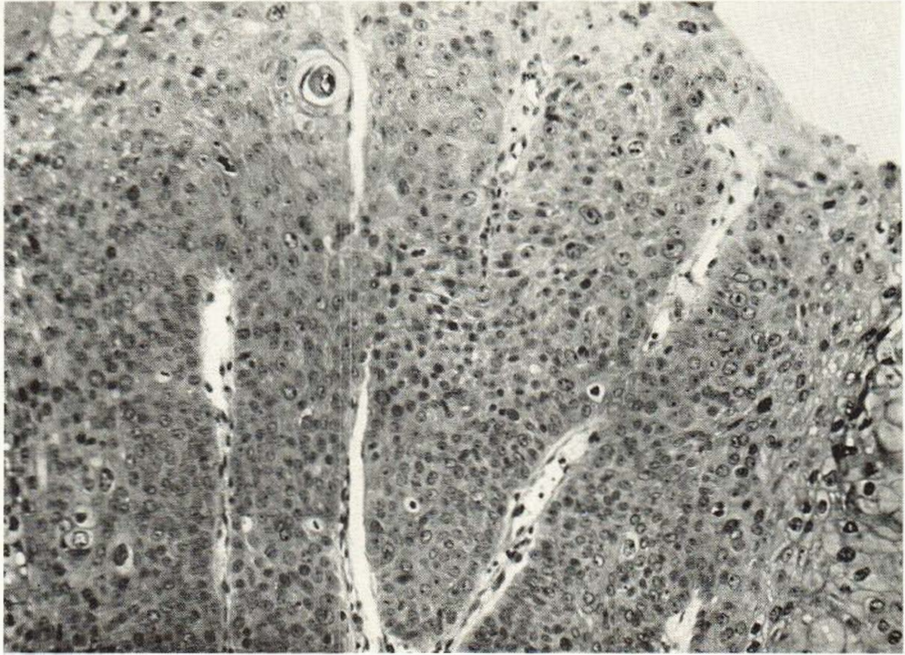


Fig. 4. Area of the proliferated epidermis showing a picture similar to that of Bowen's disease.

indistinguishable from those characteristic of E.V., although the amount of kreatine granules was less pronounced.

Discussion

Malignant degeneration of skin lesions in Epidermodysplasia Verruciformis is not only of academic interest. It may reasonably be assumed that the carcinomas found in this cutaneous condition originate from the original skin lesions. Therefore E.V. may be one of the rare conditions in human pathology in which a virus may be involved in carcinogenesis. It is noteworthy that the virus concerned is identical or closely related to the virus of the common wart, the latter representing a tumour of benign character. Nowadays, however, it is generally assumed that malignant changes are caused by a combination of various factors. In E.V., besides the possible role of the virus also additional unknown factors should be taken into account, e.g. the particular "terrain", viz. the genetically affected skin in this disease.

In an attempt to demonstrate an inter-relationship between the virus and the malignant degeneration of the epidermis cells a provisional electron microscopical examination of the malignant changes was performed (P. J. van Mullem, Ph.d.). However up till now no "complete" virus particles were observed. This does not necessarily mean that a connection between the virus in the original lesions and the malignant changes which occur should be rejected (2, 3). In tumours induced by animal viruses some authors assume that the virus in question triggers a cell mechanism and then drop out of the picture. Attention is also drawn to so-called "masking" of viruses, a phenomenon which is not uncommon in experimental virus-induced tumours. Whether or not such mechanisms also occur in tumours suspected to be induced by human viruses is still unknown. Possibly more extensive electron microscopical examination and more sensitive methods may in due course throw more light on the problems related to the findings in the present case.

SUMMARY

In a characteristic case of Epidermodysplasia Verruciformis the presence of an intranuclear virus had been demonstrated by means of electron microscopy. Malignant degeneration occurred in a number of typical lesions. The virus in question seems identical with or closely related to that of the common wart. The microscopical findings in the malignant changes are described. The histological picture corresponded to that of Bowen's disease or to that of a bowenoid carcinoma. The possible role of the virus in the malignant degeneration of the lesions in Epidermodysplasia Verruciformis is discussed.

REFERENCES

1. Andrade, R.: Die präcanceröse und canceröse Wucherung von Epidermis und Anhangsgebilden. In: *Handbuch der Haut- und Geschlechtskrankheiten*, hrsg. von J. Jadassohn, *Ergänzungswerk* 1/2.
2. Bryan, W. Ray: Viruses and carcinogenesis. *Proc. of the XII Internat. Congr. of Dermatology*. Washington D.C. 1962.
3. Evans, C. A., Rashad, A. L. and Mottet, N. K.: The papilloma of rabbits induced by the virus of Shope. In: *The Epidermis*, edited by Montagna, W. and Lobitz, W. C. New York, Academic Press Inc. 1964.
4. Jablonska, S., Fabjanska, L. and Formas, I.: On the viral etiology of epidermodysplasia verruciformis. *Dermatologica* 132: 360, 1966.
5. Montgomery, H.: *Dermatopathology*. New York, Harper & Row Publ. 1967.
6. Oehlschlaegel, G., Röckl, H. und Müller, E.: Die Epidermodysplasia verruciformis, eine sog. Praecancerose. *Der Hautarzt* 17: 450, 1966.
7. Ruitter, M. and van Mullem, P. J.: Demonstration by electronmicroscopy of an intranuclear virus in epidermodysplasia verruciformis. *J. Invest. Derm.* 47: 247, 1966.
8. Touraine, A.: *Épithéliomas et états pré-épithéliomateux*. Paris, Masson 1961.