

## THE CHICKEN COMB AND WATTLE AS EXPERIMENTAL MODEL FOR INVESTIGATIVE ARGON LASER THERAPY OF ANGIOMAS

EDMOND J. RITTER\*, LEON GOLDMAN\*\*, DANIEL RICHFIELD\*\*,  
R. JAMES ROCKWELL, JR.\*, AND MARILYN FRANZEN\*

Lesions of the portwine type do not spontaneously regress. The methods in general use for their treatment frequently fail to bring about the desired cosmetic effect (1). Consequently, the laser irradiation in the clinical treatment of hemangiomas has been under investigation in the authors laboratories for the past five years. During this period 89 patients with various types of portwine lesions have been treated with laser irradiation (3, 4, 6).

In the course of this work an animal model was developed suitable for determining the effects of laser variables on vascular tissues. This is the chicken comb, wattle and ear lobe, which exhibit a high degree of capillary proliferation, and bear to some degree a histological resemblance to the human portwine lesion and to the so-called senile angioma (2, 5).

The color of the chicken comb as well as the color of the portwine lesion is due mainly to the color of the red cells at different depths in the tissue. The rationale behind the laser therapy of angiomas was that laser irradiation might more or less selectively be absorbed by the red blood cells, leading to thrombus formation and capillary destruction. In the early animal studies, which were done with ruby and neodymium lasers, this did not appear to occur. The main effect was coagulation

necrosis involving dermis, epidermis, capillaries and collagen tissue, with consequent development of scar tissue. This scarring resulted in blanching of the laser irradiated area. In the chicken this blanching was not permanent, the normal color returning in about eight weeks, at which time microscopic sections showed no evidence of permanent capillary damage. However, ruby or neodymium laser treatment of the portwine lesion in man produces blanching which in some cases has lasted for more than four years. The blanching effect here appears to be due to the same mechanism as in the chicken, i.e. coagulation necrosis of the epidermis and dermis occurs, involving chiefly the collagenous tissue, and to some extent the blood vessels; scarring and consequent decreased vascularity produce blanching of the lesion. In some patients the blanching was only transient and there was revascularization of this area, in spite of the fact that the portwine lesion is considered a fixed structure.

These results are in line with theoretical considerations. The ruby laser emits red light (6943 Å). It is likely that the red blood cells, because of their color, would largely reflect this light rather than absorb it. The red cells are not, however, completely reflective to red light, so that some absorption does occur which could result

\* Laser Laboratory, Children's Hospital Research Foundation of the Medical Center of the University of Cincinnati, Cincinnati, Ohio, U.S.A. Supported by a grant from the John A. Hartford Foundation.

\*\* Departments of Dermatology and Pathology, Medical Center, University of Cincinnati, Cincinnati, Ohio, U.S.A.

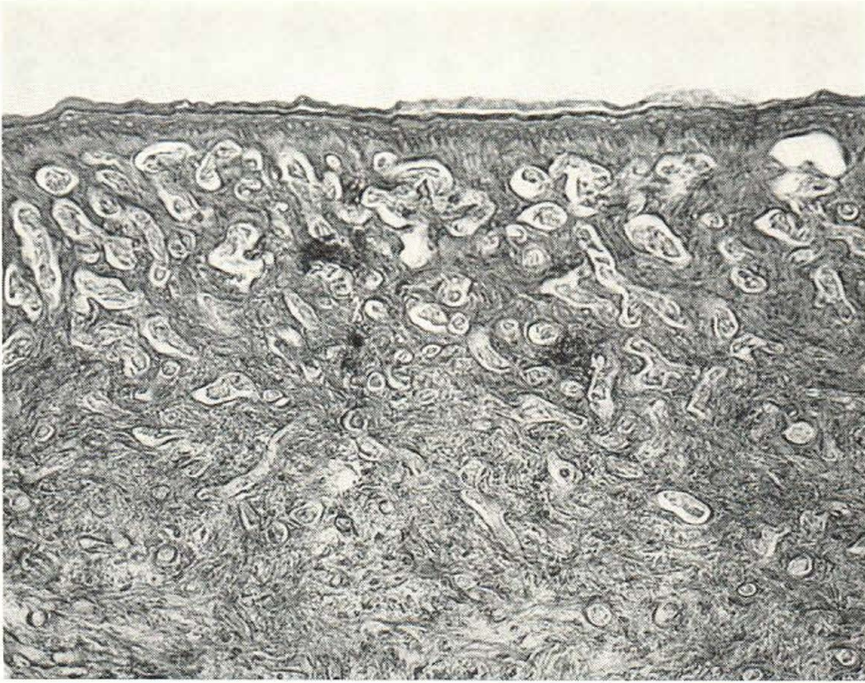


Fig. 1. Control Section. Untreated Chicken Comb. Hematoxylin-eosin  $\times 200$ .

in cellular destruction by irradiation with a red light source of sufficiently high energy density. It appears, however, that the amount of ruby laser radiation reaching the deeper capillaries in the dermis was insufficient to cause extensive damage to the red cells. On the other hand, because of the absorption spectrum of hemoglobin, it is possible that red blood cells might preferentially absorb green or blue light, resulting in some degree of selective absorption, as compared to the white cells and adjacent tissues. The argon continuous wave laser emits blue and green wavelengths. Consequently, it was of interest to evaluate the argon laser as a tool in hemangioma therapy. Our investigation of the effects of the argon laser on chicken tissue is the subject of this report. Clinical studies will be reported later.

#### Materials and Methods

The laser used was a Spacerays model 5800. In some cases the mixed wavelength beam was used. This contained seven wavelengths

ranging from 4545 Å to 5145 Å. In other cases a prism was used to split it into components permitting use of a dark blue beam at 4765 Å, a light blue beam at 4880 Å, or a green beam at 5145 Å. A convex lens was used to enlarge the beam cross section to spot sizes in the range of 3–5 mm in diameter. Typically a light output of 0.45 watts was applied to a spot 3 mm in diameter.

In early studies the chickens were anesthetized with intravenous pentobarbital. This was discontinued since either pulsed or continuous wave laser radiation at the dosage levels used appeared to cause them very little discomfort. The number of irradiation sites depended on the size of the comb, but in most cases twelve lesions were placed on the comb with two more on each wattle. Non-irradiated areas served as controls, since no effect is seen in non-target areas. Eighteen chickens were used in the argon laser study. Irradiation was carried out by holding the chicken against a hole in a plastic plate mounted in line with the argon laser beam. An electrical

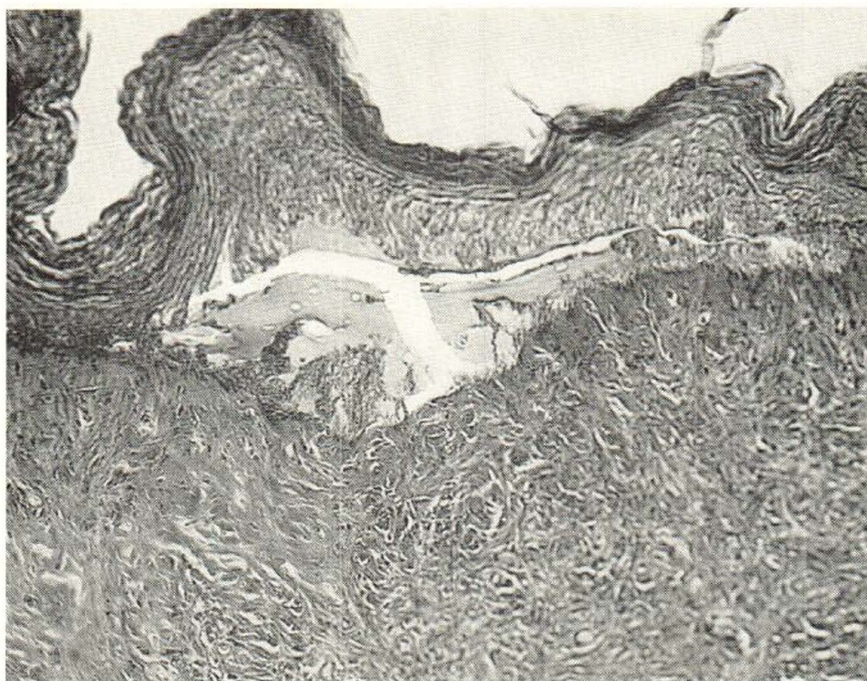

Fig. 2. Chicken Comb. One Day Post Irradiation. Hematoxylin-eosin  $\times 200$ .

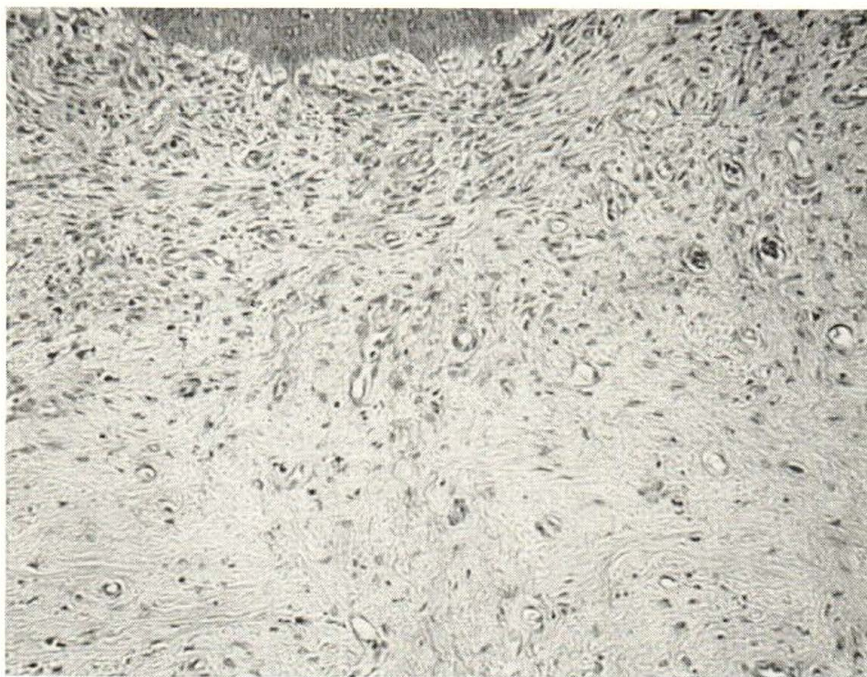


Fig. 3. Chicken Comb. Two Weeks Post Irradiation. Hematoxylin-eosin  $\times 200$ .

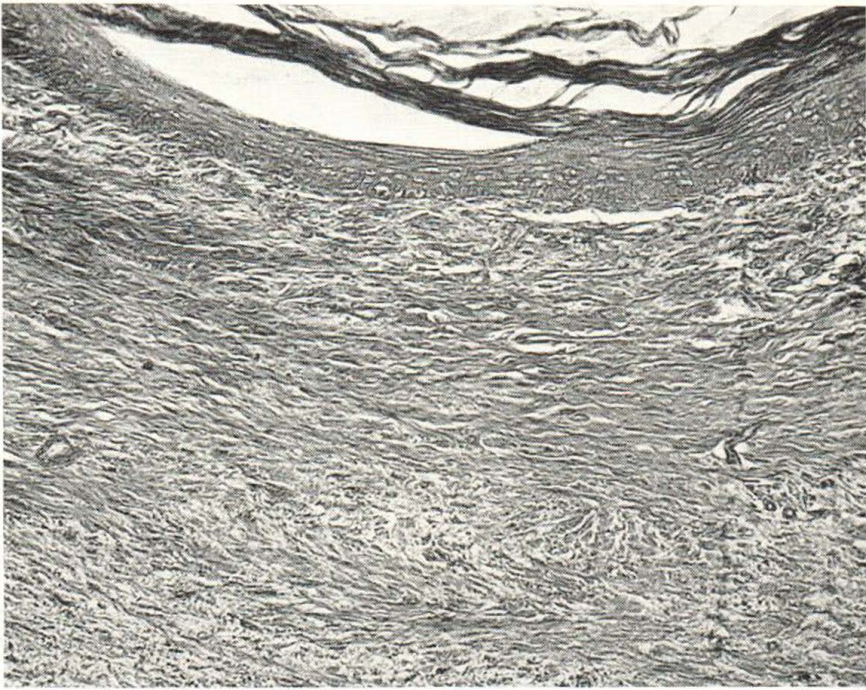


Fig. 4. Chicken Comb. Thirty Days Post Irradiation. Hematoxylin-eosin  $\times 200$ .

timer was used to interrupt or to pass the beam for periods from 5 to 30 seconds.

The animals were sacrificed at 1 day, 2 weeks, or 30 days after irradiation. The comb and wattle tissues were then subject to conventional histological techniques and staining.

#### Results

Figure 1 shows a control section, the untreated chicken comb. Normally the superficial vasculature of the comb and wattle consists of a rich open capillary dermal network, similar to that seen in erectile tissues.

Figure 2 shows a section of the chicken comb, one day post irradiation, where the dosage was 0.45 watts, the area a 3 mm diameter spot, and the time 20 seconds at 4765 Å. Here it is seen that the argon laser beam causes a sharp zone of epidermal coagulation necrosis; the epidermis lifts away from the underlying dermis producing a shallow cleft. The dermis shows a well defined zone of injury characterized

by vascular wall compression, endothelial cell and collagen tissue coagulation. This zone is shallow and is bordered by a zone of vascular dilation and engorgement which starts superficially a little in advance of the end point of the epidermal injury and forms a shallow dermal arc around the zone of vascular compression.

Figure 3 shows a section two weeks post irradiation. Laser parameters were the same as in the previous section. At this time the epidermis as well as the dermis is seen to be thinned significantly. There is loss of dermal mucin and there is beginning fibrosis. The vessels of the superficial network are markedly diminished in number (90-95% decreased) and the deeper dermal zone of vascular engorgement has disappeared. This should correspond with the period of greatest pallor in the comb.

Figure 4 shows a section 30 days post irradiation. The dosage was 1.5 watts to a 5 mm diameter spot for 30 seconds, using an argon beam containing mixed wavelengths. At this time the zone of injury shows atrophic epidermis, extensive fibro-

sis and beginning superficial revascularization due to the growth of capillary buds into the injured zone from superficial dermal vessels lateral to the site of the injury.

The main variables studied were wavelength and dosage. While significant capillary damage was obtained in all cases, no significant difference was found in the range of dosage studied, nor with the different wavelengths used.

#### Discussion

Under the conditions of our experimentation it appears that irradiation of the chicken comb and wattle with argon light does indeed result in significant capillary damage with some fibrosis, but without significant permanent damage to other skin structures, although there is initially extensive damage to the epidermis. In the chicken blanching does not appear permanent; that is, twelve weeks after irradiation the blanched areas on the chicken comb show some reversion to their normal red color, and this is also indicated in histological sections showing revascularization. However, this may not be important, because the chicken comb has considerable regenerative properties, probably much more so than is the case with human fixed portwine lesion. The important thing is that argon irradiation of the chicken tissue does result in damage to superficial capillaries.

#### SUMMARY

Laser irradiation of the chicken comb with argon laser, under a wide range of dosage, produced significant damage to the super-

ficial capillaries, as well as some fibrosis. Revascularization occurred eventually, and the normal color appeared to return to the chicken comb.

In view of the results obtained, it seems desirable to evaluate the argon laser as a clinical tool in investigative therapy of angiomas, to determine if there is more selective vascular damage with the argon than with the ruby and neodymium lasers, and to what degree a favorable cosmetic effect can be achieved.

#### REFERENCES

1. Conway, H. and Montroy, R. W.: Permanent Camouflage of Capillary Hemangiomas of Face by Intradermal Injection of Insoluble Pigments (Tattooing). *New York State Journal of Medicine* 65: 876, 1965.
2. Goldman, L. and Richfield, D. F.: Acquired Angioma. *Acta derm.-venereol.* 46: 177, 1966.
3. Goldman, L., Rockwell, Jr., James R. and Meyer, R.: Preliminary Report on the Laser Treatment of Hemangioma. *Proceedings of the 13th International Congress of Dermatology*, Munich, August, 1968.
4. Goldman, L., Wilson, R. and Kitzmiller, K. W.: Preliminary Report. Investigative Studies of Laser Treatment of Angiomas. Presented at the Noah Worcester Dermatological Society, Palm Beach, Florida, April 1966.
5. Ritter, E. J.: The Chicken Comb and Wattle as an Experimental Model for the Therapy of Hemangiomas. Preliminary Laser Studies. *Life Sciences* 5: 1903, 1966.
6. Solomon, H., Goldman, L., Henderson, B., Richfield, D. and Franzen, M.: Histopathology of the Laser Treatment of the Portwine Lesion. *J. Invest. Dermatology*, in press.