

PASSIVE TRANSFER TO HUMAN RECIPIENTS OF THE CAPILLAROTOXIC SERUM FACTOR STIMULATED BY HEPARIN

J. KOZŁOWSKI AND E. MAŁASZYŃSKA-OLKIEWICZ

In many patients with acute vascular purpura the serum has the potency of causing haemorrhagic changes, as observed i.a. by Stefanini and Mednicoff (20). Bernard *et al.* (1) called the agent responsible for such haemorrhagic changes a capillarotoxic factor. Lovell *et al.* (13) believe it to be identical with the necrotising factor in the serum of patients with tuberculosis (9) and rheumatic fever (13, 2). It is, however, possible that antibodies detected in serum by complement fixation, precipitation or human antiglobulin consumption tests using specific vascular antigen (21, 15, 8) are different from the capillarotoxic factor. The capillarotoxic necrotising factor can be demonstrated by intradermal injection of 0.1 ml of a patient's serum into white guinea pigs. A haemorrhagic spot, sometimes developing into a necrotic focus, can be observed at the place of injection.

The nature of the capillarotoxic factor is not known, but it has been shown to be related to the serum gamma globulin fraction and to be thermostabile (14). Israel *et al.* (6) believe it to be antibody directed against the capillary endothelium. The nature of the capillarotoxic factor in cases of hyperergic purpura is very similar to the antivessel antibodies produced experimentally (17).

The capillarotoxic factor does not show species-specificity but rather organ-specificity (the human serum capillarotoxic factor is acting on the vessels of small animals). Apparently some factors are stimulating the activity of the capillarotoxic factor

(12). This activity appears to be stimulated or strengthened by heparin.

In the present study we draw attention to the capacity of the capillarotoxic factor and heparin together to cause haemorrhagic changes in healthy humans. The role of heparin as a pathogenic auxiliary factor in haemorrhagic diathesis was formerly discussed but has really not been clarified. Storck (22) established a high heparin serum level in some cases of haemorrhagic vasculitis. Koller (10) indicated an excess of heparin-antithrombin in purpura anaphylactoides Glanzman, purpura Schönlein and purpura abdominalis Henoch. Smith and Korff (19), Ruiter and Oswald (18) reported the occurrence of elevated levels of a heparin precipitable fraction (HPF) in the serum of patients with necrotizing vasculitis. Ruiter and Oswald (18) found a correlation between the blood level of HPF and the amount of fibrinoid material deposited in and around blood vessels of the dermis. This role of HPF in acute hyperergic purpuras has been recently discussed (5, 7).

Intradermal heparin testing in cases of acute hyperergic purpura is also of interest. Korting and Adam (11) and Göltner (4) called attention to skin inflammatory reactions at the site of intracutaneous injection of heparin in patients with purpura hyperglobulinaemica and purpura Schönlein. Apparently there was no allergic effect following heparin administration in these cases. On the other hand Rajka and Skog (16) described allergic reactions after hepa-

Table 1. Results of passive transfer of the capillarotoxic factor to human healthy individuals

Donor's No	Donor's Diagnosis	Animal test /transfer of 0,1 ml of patient's serum to white guinea pig/	Human recipient's No.	Transfer of 0,1 ml of patients serum/intradermal injection/	Transfer of 0,1 ml of patient's serum with 500U. heparin/intradermal injection/
1	Purpura Schönlein	+++	1	-	++
			2	-	-
			3	-	-
2	Arteriolitis allergica	++	4	-	++
			5	-	-
3	Erythema multiforme	++	6	-	-
4	Vasculitis necrotisans	++	7	-	-
5	Toxicodermia haemorrhagica	+++	8	-	-
			9	-	-
6	Erythema scarlatini forme	++	10	-	++
			11	-	-
7	Toxicodermia haemorrhagica	++	12	-	-
			13	-	-
8	Purpura Schönlein	+++	14	-	-
9	Syndr. Stevens-Johnson	++	15	-	-
			16	-	-
			17	-	-
10	Toxicodermia haemorrhagica	++	18	-	++
			19	-	+

Code:

+++ : denotes positive result with inflammatory haemorrhagic papule and necrotic focus.

++ : positive result with inflammatory haemorrhagic papule.

+ : weakly positive result with inflammatory haemorrhagic macule.

- : negative result with inflammatory papule only.

rin treatment with different clinical symptoms.

In a previous report (12) we showed the ability of intracutaneously administered heparin to stimulate or strengthen the activity of the capillarotoxic factor and to develop inflammatory and frequently even haemorrhagic changes in cases with hyperergic exanthems. Those symptoms usually do not occur in healthy individuals. Our present study is concerned with the possibility of passive transfer to healthy indi-

viduals of the capillarotoxic agent stimulated by heparin.

Materials and Methods

Blood samples were obtained from 10 patients hospitalized in the Postgraduate Training Center of Dermatology, Bydgoszcz, during 1966-1968. The donors had symptoms of purpura Schönlein, erythema exudativum multiforme, erythrodermia scarlatiniformis etc.

Nineteen voluntary men were injected intracutaneously with the patient's serum or serum with heparin as indicated in table 1. The presence of the capillarotoxic factor was in each instance ascertained in advance on guinea pigs. The methods applied are described in the following:

2-3 ml of venous blood was taken from the forearm vein and centrifugated. The serum was first used to ascertain on guinea pigs the presence of the capillarotoxic agent and to perform passive transfer of the capillarotoxic factor to healthy human recipients.

White guinea pigs were injected with 0.1 ml serum intracutaneously on the animals back on either side of the spine, using the patient's serum on one side and the control serum on the other side. The inflammatory, haemorrhagic reaction and necrotic efflorescences were observed after 24 and 48 hours. The results were rated: *highly positive* (+++) in case of necrotic changes, *positive* (++) in case of inflammatory papules and haemorrhagic spots, *weakly positive* (+) when erythematous haemorrhagic macules were present and *negative* (—) when rapidly disappearing inflammatory papules without haemorrhagic changes were observed.

In passive transfer of capillarotoxic serum potency to humans the following procedures were used:

Healthy humans were injected intracutaneously in the back at 5 points with distance of 5 cm each using (1) 0.1 ml of the patient's serum, (2) 0.1 ml of the patient's serum + 0.1 ml heparin,¹ (3) 0.1 ml heparin same dosage, (4) 0.1 ml control serum from a healthy individual and (5) 0.1 ml control serum + 0.1 ml heparin (500 U.). The results were observed after 24 and 48 hours. Inflammatory efflorescences, haemorrhagic and necrotic changes were appraised.

Results

The results are seen in table 1. We succeed in transmitting the capillarotoxic serum fac-

tor from 10 patients to 5 out of 19 healthy persons—but only when serum was injected mixed with heparin. There were no signs of necrosis and all positive results showed solely the coincidence of inflammatory and haemorrhagic changes. One patient's serum with capillarotoxic potency and added heparin did not elicit positive results in any recipients.

Discussion

Passive transfer of the human capillarotoxic factor in serum is possible in the white guinea pig (6). This phenomenon can be utilised as a biological test. Similar experiments with other animals (cats, dogs, mice, rats) failed (13). The results of passive transfer to healthy persons of the capillarotoxic factor were also negative (15). When mixed with heparin the capillarotoxic factor can be transferred to human recipients. It thus appears that the capillarotoxic serum factor acts more strongly in the presence of heparin. It is possible that the protein of the capillarotoxic agent conjugated with heparin results in a complex with greater antiendothelial potency.

Cohen stated (3) that heparin in skin reactions to chromium is a specific carrier of the sensitivity of this element. In hyperergic purpura we believe that the action of heparin is indirect by stimulating the capillarotoxic factor which cause haemorrhagic changes. However, heparin is not a specific stimulator. Possibly, different chemical agents may act to stimulate the capillarotoxic factors (12). These agents, when injected intracutaneously, can cause local izomorphic reactions in patients with symptoms of acute hyperergic purpura (4).

In conclusion it may be said that the capillarotoxic serum factor stimulated by heparin in certain cases can be passively transferred to the skin of healthy human recipients from patients with acute hyperergic purpura, but that necrotic changes are not observed in these cases.

The presence of heparin, necessary in the passive transfer of the capillarotoxic factor

¹ "Polfa" 0.1 ml = 500 U. = 5 mg.

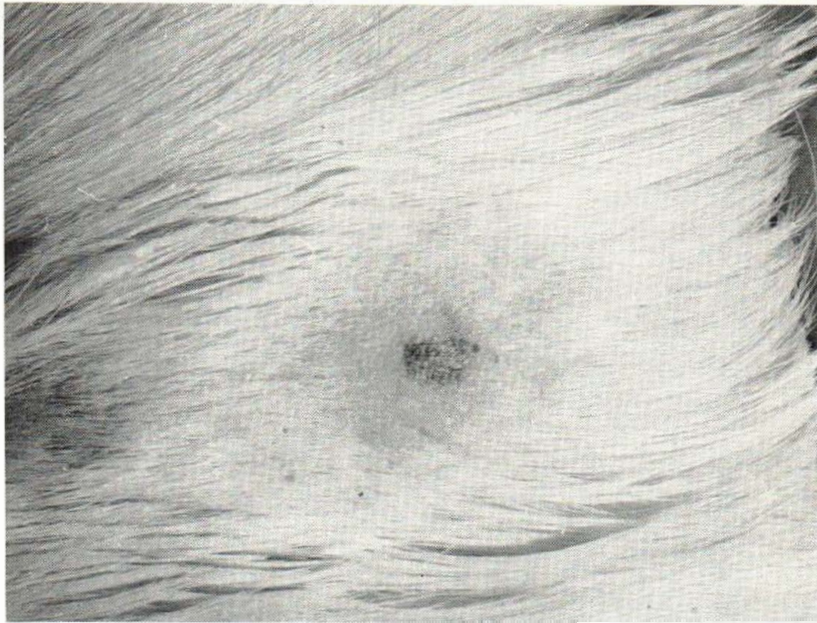


Fig. 1. A positive result of the animal test: inflammatory papule and haemorrhagic spot.

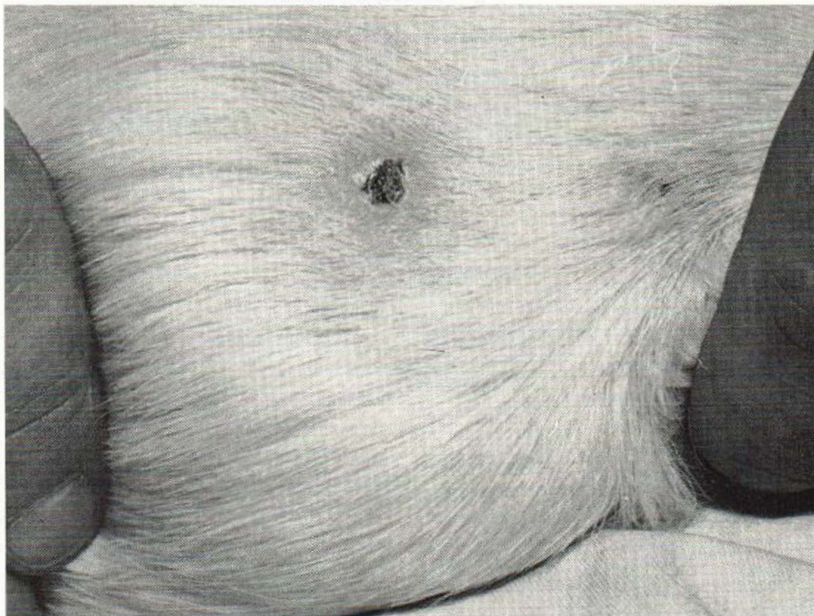


Fig. 2. A highly positive result of the animal test: necrotic focus at the site of injection with the serum of a patient with hyperergic purpura.

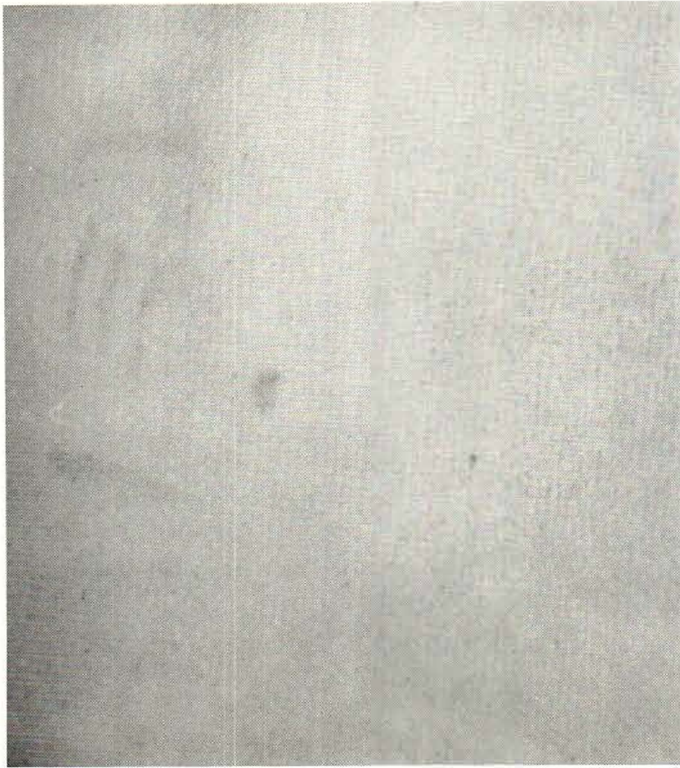

Fig. 3. The skin of a human recipient: positive result of passive transfer of capillarotoxic serum factor stimulated by heparin.

to healthy individuals suggests an indirect and auxiliary role of this mediator by causing haemorrhagic changes in patients with acute hyperergic purpura.

SUMMARY

Passive transfer to human recipients of the capillarotoxic serum factor stimulated by heparin was attempted. Heparin was added to serum from 10 donors with symptoms of acute hyperergic purpura and injected intracutaneously into 19 healthy recipients (0.1 ml of the patient's serum and 0.1 ml (500 U.) of heparin). The presence of the capillarotoxic factor in the donor's serum was previously tested on white guinea pigs. The experiment was positive in 5 cases. No necrotic changes appeared in the area of the injection such as is common in animals. The assays of passive transfer of potent capillarotoxic serum without heparin were

always negative. On the basis of these experiments the authors discuss briefly the likely indirect and auxiliary role of heparin in evoking haemorrhagic changes in patients with hyperergic vascular purpura (stimulation of the capillarotoxic factor).

REFERENCES

1. Bernard, J., Mathé, G. and Israel, L.: *Presse méd.* 65: 759, 1957.
2. Boake, W. C. and Lovell, R. R.: *Brit. J. Exper. Path.* 35: 350, 1954.
3. Cohen, H. A.: *Arch. of Derm.* 94: 409, 1966.
4. Göltner, E.: *Derm. Wschr.* 143: 485, 1961.
5. Harville, D. D., Owen, Ch. A. and Winkelmann, R. K.: *Arch. of Derm.* 93: 287, 1966.
6. Israel, L., Mathé, G. and Bernard, J.: *Sang* 36: 603, 1955.
7. Jabłońska, S., Rzęsa, G. and Kalinowska, J.: *Dermatologica* 133: 402, 1966; 133: 487, 1966.

8. Jilek, M.: *Cs. Derm.* 40: 427, 1965.
9. Klemperer, F., Fried, R. and Stark, K.: *Brit. J. Exper. Path.* 43: 116, 1962.
10. Kaller, F.: *Dermatologica* 102: 189, 1951.
11. Korting, W. G. and Adam, W.: *Derm. Wschr.* 131: 121, 1955.
12. Kozłowski, J., Małazyńska-Olkiewicz, E., Wankiewicz, R. and Lipski, L.: *Derm. Wschr.* 15: 484, 1965.
13. Lovell, R. R., Pryce, D. M. and Boake, W. C.: *J. Exper. Path.* 35: 345, 1954.
14. Łukasiak, B.: *Przegl. Derm.* 51: 427, 1964.
15. Miescher, P.: in *Immunopathologie in Klinik und Forschung*. Miescher, P. and Voraender, K. O.—Georg Thieme Verlag, Stuttgart, 1961.
16. Rajka, E. and Skog, G.: *Acta dermat.-venereol.* 42: 27, 1962.
17. Rasponi, L. and Rafanelli, A.: *Arch. Ital. Derm.* 30: 322, 1960.
18. Ruiter, M. and Oswald, F. H.: *Hautarzt* 14: 6, 1963.
19. Smith, R. T. and Korff, R.: *J. Clin. Invest.* 36: 596, 1957.
20. Stefanini, M. and Mednicoff, I. B.: *J. Clin. Invest.* 33: 967, 1954.
21. Steffen, C.: *Wien. Z. inn. Med.* 37: 452, 1956.
22. Storck, H.: *Dermatologica* 102: 197, 1951.