

SWEAT GLAND NECROSIS AND BULLOUS SKIN CHANGES IN ACUTE DRUG INTOXICATION

EVA BREHMER-ANDERSSON AND NIELS BANG PEDERSEN

Forensic medicine has reported that acute barbiturate poisoning can give rise to red patches or bullae on different areas of the body (1, 5, 6, 8). Adebahr has drawn attention to the fact that these changes have a characteristic histological picture, namely necrosis of the sweat glands and their ducts, with or without vesicles in the overlying epithelium (1). These changes have generally been interpreted by the clinicians as decubital ulcers. The dermatologist can occasionally be confronted with skin changes of this type, as in the present case study.

Case Report

The patient, a 25 years old man, had on three previous occasions been admitted to the Psychiatric department in a state of acute alcohol intoxication. Following this he was treated in the out-patients department with meprobamate, methylhomatropine-bromide, caffeine,¹ propiomazine² and disulfiram.³ On the evening of the 16th of August 1966 he was found alone in a dazed condition in his room. The following day he was admitted to the Dermatology department because of his skin condition. He was not completely orientated on admission, but after a few hours he was able to give a comprehensive history. He said he

had stopped his Antabus treatment on the 7th of August. On the 13th he consumed some alcohol, after which he remembered nothing until the evening of the 16th. There was no definite evidence concerning misuse of any of the mentioned or other drugs.

Skin condition: Over the right greater trochanter there was a 5×5 cm sized, well defined, reddish and markedly tender plaque. On the surface there were a number of very small vesicles and on the edge a 15×10 mm sized bulla, which contained clear fluid (fig. 1). In the corresponding area on the left side there was a reddish plaque about 8×8 cm. It showed no vesicles. On the medial border of each foot a 4×4 cm sized bulla was seen, overlying a reddened skin.

A biopsy was taken from the lesion over the right greater trochanter. It comprised the bulla and macroscopically normal skin.

Histological examination: The biopsy was serially cut and stained with hematoxylin-eosin and van Gieson. It showed a large subepidermal bulla and a row of small intra-epidermal vesicles (fig. 2). The intra-epidermal vesicles were of the type usually met with in eczema and even the bulla gave the impression that it had originally been intra-epidermal. Several of the small vesicles lay perpendicular to the epithelial sur-

¹ Sinedyl®.

² Propavan®.

³ Antabus®.

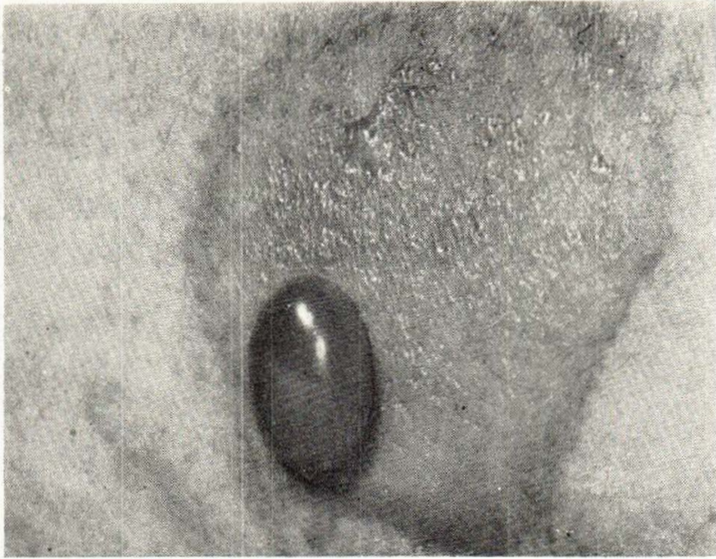


Fig. 1. Right greater trochanteric region with a bulla and a number of small vesicles on a 5×5 cm sized, well defined, reddish plaque.



Fig. 2. A large subepidermal bulla and a row of small intra-epidermal vesicles. Van Gieson ×63.

face. The bulla and vesicles contained an eosinophilic exudate and a number of polynuclear leucocytes. The epithelium around them showed no sign of infarction.

Several groups of sweat glands were seen in the fat tissue underlying the vesicles. These were either completely or partially necrotic (fig. 3). Even the gland ducts were

necrotic. A necrotic duct, which could be followed through the middle and superficial parts of the dermis led into the subepidermal bulla (fig. 4). Another duct could be traced for the whole of its length through the epidermis. The deeper intra-epidermal parts were necrotic and surrounded by a vesicle (fig. 5).

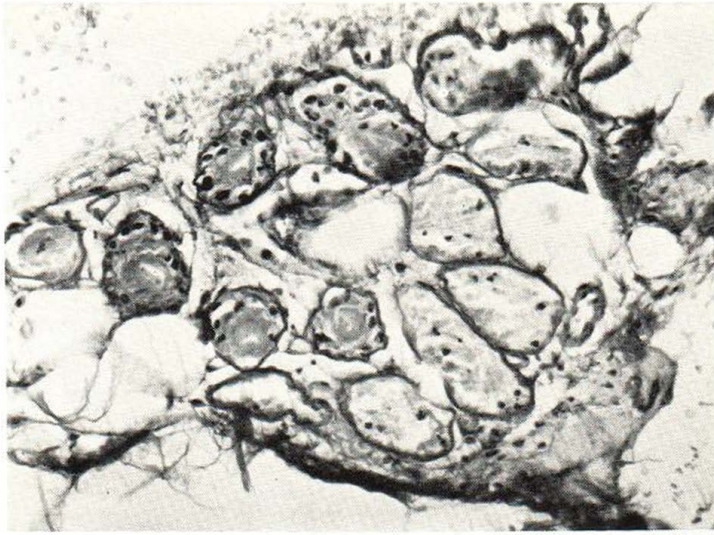


Fig. 3. A group of necrotic sweat glands at the border between the dermis and the subcutaneous fat. Van Gieson $\times 160$.

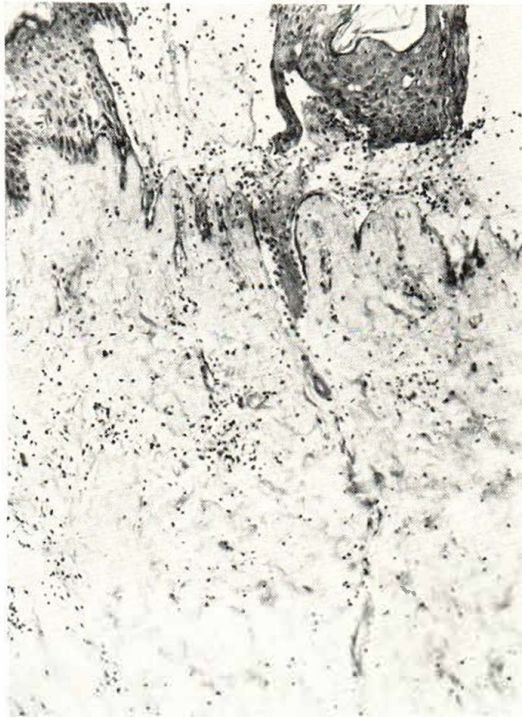


Fig. 4. A necrotic sweat duct can be followed through the middle and superficial parts of the dermis to the subepidermal bulla. Hematoxylin-eosin $\times 100$.

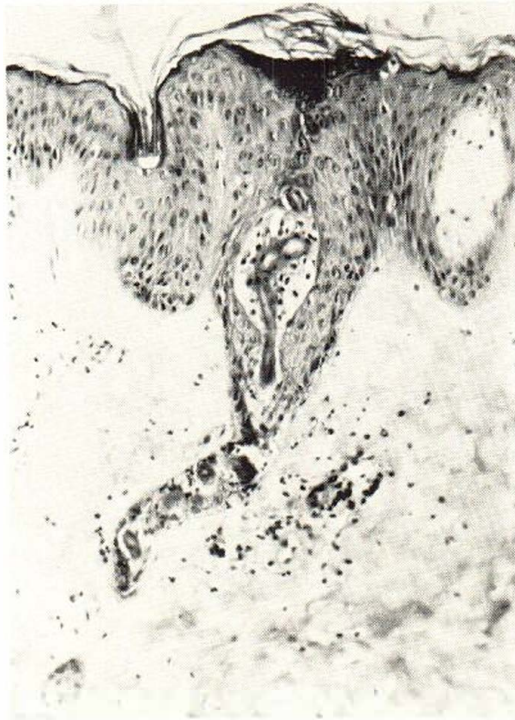

Fig. 5. An intra-epidermal sweat duct. The deeper parts are necrotic and surrounded by a vesicle. Hematoxylin-eosin $\times 160$.

The connective tissue in the upper part of the dermis was oedematous and contained a number of inflammatory cells, mostly polynuclear leucocytes. A few small areas of fibrinoid necrosis were seen, particularly in the deeper dermis. Some small vessels showed fibrinoid necrosis of their walls and were surrounded by an infiltrate of polynuclear leucocytes and nuclear fragments. These vessels were often situated near the necrotic sweat glands or necrotic ducts. However, the changes both in the vessels and the connective tissue were sparse and the histological picture was completely dominated by the lesions in the sweat glands and the epidermis.

Discussion

Skin changes in acute narcotic poisoning have been described not only in autopsies,

e.g. by Adebahr (1), but also in clinical material by Holten (4), Sørensen (7), and Beveridge and Lawson (3) among others. Holten's investigation comprised 501 cases of acute barbiturate poisoning. Skin changes occurred in 4 per cent of the patients. Of these one died. Holten described in one of the cases histological changes which were non-specific.

Sørensen's investigation was based on 1173 cases of poisoning, of which sixty (5.1 per cent) had skin lesions. In nine of the cases the poisoning was elicited by drugs other than barbiturate, i.e. imipranin,⁴ glutethimide,⁵ meprobamate, carbon monoxide or by meprobamate, methadone, dihydrocodeinone in combination with alcohol.

Beveridge and Lawson (3) gave an account of bullous skin changes in patients with acute barbiturate poisoning. Out of 290 patients 19 or 6.5 per cent showed

⁴ Tofranil®.

⁵ Doriden®.

skin changes. A skin biopsy was taken in 4 cases. Only the appearance of the vesicles and the condition of the superficial part of the dermis were discussed. Sweat gland changes were not described. In 69 patients poisoned by preparations other than barbiturates no skin changes occurred.

Adebahr's investigation (1) was based on 300 autopsy cases of barbiturate poisoning. Of these approximately 40 per cent had skin changes. His work contained in addition to macroscopic descriptions a careful report of the histology.

The macroscopic skin changes were similarly described by all these authors. As a rule they started as distinct circumscribed reddish patches which subsequently acquired a cyanotic hue and eventually changed into bullae. Bullae also appeared directly on normal skin and sometimes reached a considerable size. The largest seen by Adebahr was $12 \times 8 \times 2$ cm. The changes were solitary or multiple. The latter were often symmetrical. They sometimes appeared over pressure areas, but frequently also over non-pressure areas. In a number of cases deep ulcers developed, which healed with difficulty.

As a rule the cause of the skin changes has been believed to be pressure. They have therefore been diagnosed clinically as decubital ulcers. In Holten's material (4) some patients had been unconscious only for a short period before admission and became conscious several hours before the appearance of the skin lesions. Changes sometimes appeared in the same patient in different areas at intervals of many hours. Multiple lesions were irregular and often so widespread that pressure could not possibly explain them all. Because of these observations Holten considered that pressure could not be the sole nor the most important cause of this skin phenomenon. He considered it to be a specific toxic effect of the barbiturate. Beveridge and Lawson (3) supported Holten's views.

Sørensen (7), on the other hand, considered decubital ulcers as the correct diagnosis because in his material the poisoning in 9 cases was produced by drugs other than barbiturates and because in clinical

material no positive correlation was found between the amount of the drug taken and the incidence of skin changes. The high frequency of skin changes in Adebahr's autopsy material suggests, however, that the size of the dose is of importance.

In autopsy specimens Adebahr observed both intra-epidermal and subepidermal vesicles and in a number of cases, surviving for 2-3 days, he also found thrombosis in some small dermal blood vessels. The most significant findings were, however, seen in the sweat glands. These showed partial or total necrosis, even in early lesions, where very little or no changes were found in the epidermis. The surrounding inflammatory changes were insignificant. He therefore thought it possible that sweat gland changes are of importance, at least when the skin lesions appear in pressure free areas. He considered that if the barbiturate concentration is sufficiently high it causes necrosis of the sweat glands and their ducts and is thus released into the surrounding tissue. The reaction is most severe in the epidermis. Small intra- or subepidermal vesicles appear around the necrotic sweat ducts. These small vesicles enlarge and coalesce to form bullae. The fact that barbiturates and other drugs can be excreted via sweat glands has been pointed out by Weinig and Jahn (10) among others. Together with Reissland, Adebahr (2) was also able to measure the amount of barbiturate in a bulla, in a patient who died of barbiturate intoxication.

Voigt and co-workers (9) have shown in autopsied cases that the same type of skin lesions can be produced by methaqualone.

The patient described in this case study appears to be the first in which the sweat gland lesions have been found by biopsy. The drug involved has not been identified. The case is published partly to draw the attention of colleagues to this type of change, and partly because of the histopathological picture, viz. the necrotic sweat glands and ducts, which can be followed from the dermis up to the epidermal vesicles. This finding supports the observations made previously by Adebahr.

SUMMARY

In forensic medicine it is known that acute barbiturate intoxication may produce reddish and sometimes bullous skin lesions with a characteristic histological picture. Lesions of this type have also been observed in clinical material, where, as a rule, they have been interpreted as decubital ulcers.

The present case study reports a patient with bullous skin lesions following acute drug intoxication and where the diagnosis was established by skin biopsy. The histological picture showed necrotic sweat glands and sweat ducts. Some of the latter could be followed up into epidermal or subepidermal vesicles.

Skin lesions of this type can be produced not only by barbiturates but also by other narcotic drugs.

REFERENCES

1. Adebahr, G.: Hautveränderungen bei Schlafmittelvergiftung. *Der Landarzt* 30: 1302, 1963.
2. Adelbahr, G. and Reissland, G.: Quantitativer Nachweis von Veronal im Inhalt einer Hautblase bei einer tödlichen Veronalvergiftung. *Archiv für Toxikologie* 16: 408, 1957.
3. Beveridge, G. W. and Lawson, A. A. H.: Occurrence of Bullous Lesions in Acute Barbiturate Intoxication. *Brit. Med. J. I*: 835, 1965.
4. Holten, C.: Cutaneous Phenomena in Acute Barbiturate Poisoning. *Acta dermatovenerol., suppl.* 27, 162, 1951-1952.
5. Holzer, F. J.: Leichenbefunde nach Schlafmittelvergiftung. *Dtsch. Z. gerichtl. Med.* 34: 307, 1940.
6. Schollmeyer, W.: Zur histologischen Differentialdiagnose der Hautblasen nach Hitzeinwirkung und nach Barbituratvergiftung. *Dtsch. Z. gerichtl. Med.* 51: 180, 1961.
7. Sörensen, B. F.: Skin Symptoms in Acute Narcotic Intoxication. *Danish Medical Bulletin* 10: 130, 1963.
8. Taschen, B. and Bergeder, H. D.: Über Hautveränderungen bei akuten Vergiftungen durch Barbitursäurederivate. *Dtsch. Z. gerichtl. Med.* 40: 353, 1951.
9. Voigt, G.: Personal communication.
10. Weinig, E. and Jahn, G.: Die kriminalistische Bedeutung der Ausscheidung von Arzneimitteln in Schweiß. *Dtsch. Z. gerichtl. Med.* 43: 370, 1954.