

ULTRASTRUCTURE OF MAST-CELL GRANULES IN BASAL CELL CARCINOMA

TAKASI KOBAYASI AND GUSTAV ASBOE-HANSEN

In the dermis of basal cell carcinomas numerous mast-cells are found under the light microscope (1, 3). The functional significance of these mast-cells is still a mystery. Under the electron microscope, granules of normal human mast-cells show two subgranular components, a lamellar structure and a fine granular material (2). In the present paper, ultrastructural studies have revealed changes of these structures in basalioma tissue.

Material and Method

Specimens were taken from four different patients, three males and one female, aged 58-84 years, with basal cell carcinomas on the face. All specimens were fixed in 4% glutaraldehyde solution buffered at pH 7.2 with 0.1 mol veronal acetate buffer containing 4.5% sucrose for 60 minutes, and washed in the same buffer overnight. After washing, the specimens were fixed again in 1% osmic acid solution buffered with the same solution for one hour. All fixation procedures were carried out in a refrigerator at 4°C. The specimens were washed again with the buffer at 4°C and dehydrated in graded alcohols. The tissue was embedded in Durcupan, a water-soluble aliphatic polyepoxide, or in the water-insoluble Epon 812. Ultrathin sections were cut with an LKB ultramicrotome and stained with uranyl acetate and lead citrate. A Siemens electron microscope "Elmiskop I A" was operated at 80 kV with double condensers.

Observations

The mast cells in the corium of the basal cell carcinomas showed various forms and organelles according to their sites, *i.e.* outside or in the cell infiltrate or in the close surroundings of the neoplasm.

Outside the cell infiltrate, the mast cells were oval or spindle-shaped with a few cytoplasmic protrusions (Fig. 1 a). The mast cells contained an oval nucleus, a few mitochondria, a smooth endoplasmic reticulum and ribosomes. A Golgi area could not be identified. Most of the cell body was filled with granules. The granules showed two subgranular components like the mature granules described previously by Kobayasi *et al.* (2) (Fig. 1 a, b). The granular material was fine, though of uneven density. In some granules, circumscribed dense masses like subgranules were covered all over by a crystalline pattern similar to that of the mature granules described in the paper mentioned above (2). The lamellar structures were multilayered, each layer showing short, straight, or curved figures with regular banding. Real scrolled forms were rarely found. A partial membrane could be demonstrated around each granule. The largest granules covered an area of approximately $0.38 \mu^2$ (diameter 0.7μ).

In the cell infiltrate, the electron micrographs showed destruction of the normal pattern of dermal tissues. The mast cells in this area showed wide variations in forms and organelles (Fig. 2-8).

The cells were rounded, oval or spindle-

shaped with numerous finger-like protrusions from the cytoplasm. The nuclei were oval, now and then with deep clefts, nucleoli, and lucent spots in the chromatin pattern. The Golgi zones of these mast cells were wide containing dilated vesicles. Mitochondria, ribosomes and endoplasmic reticulum were demonstrated. The ultrastructure of the granules was as follows.

Type I granules were dense, almost polygonal or oval covering a maximum area of approximately $0.05 \mu^2$ (diameter 0.25μ) (Fig. 2 a, b). The lamellae were multilayered, straight or curved with or without periodicity. Scrolls were rare, and most of the lamellae were not parallel. The granular material was fine and dense without crystalline structures. No granule membrane could be seen.

Type II granules were dense, round, oval or polygonal covering a maximum area of approximately $0.2 \mu^2$ (diameter 0.5μ) (Fig. 3). The lamellar structures were multilayered, straight curved or scrolled. Each lamella showed a periodicity and was parallel to its neighbour. The granular material was fine and dense with a faint crystalline structure. A few granules of this kind appeared more like intermediates between this and type IV granules (Fig. 4 b). A single membrane was enclosing a few granules.

Type III granules (Fig. 4 a, b) showed multilayered lamellar structures in the peripheral zone. The lamellae, which were not parallel to the neighbouring lamellae, showed straight, curved or wavy forms without periodicity. The granular material was coarse and dense with a round dense central core. Crystalline structures were not found. The maximum area covered by these granules was approximately $0.2 \mu^2$ (diameter 0.5μ). No granule membrane could be demonstrated.

Type IV granules showing round or oval forms and varied densities covered a maximum area of $0.28 \mu^2$ (diameter 0.6μ) (Fig. 4 c, 5 a-d). The lamellar structures were single- or multilayered, straight, curved or parallel, and scrolled. Each lamella showed a periodicity. The material around the lamellae was almost homogeneous.

Faint crystalline patterns were found in a few granules (Fig. 5 b). Here and there confluence of two or three granules was observed (Fig. 5 b). Some granules were composed of extremely low-density granular material appearing almost homogeneous, and even showing central lucent spots (Fig. 5 c). The lamellar figures of some granules were single-layered and surrounding the granules almost like a membrane (Fig. 5 c). Single-layered membranes appeared around a few granules (Fig. 5 a, d).

Type V granules were round or oval covering a maximum area of $0.09 \mu^2$ (diameter 0.33μ) (Fig. 6, 7 a-b). The granules showed figures equivalent to types I, II, and III, but their classification was difficult. The lamellae formed single or multiple layers, and they were straight or curved. They showed a faint periodicity and almost parallel arrangement. The granular material was fine or, rarely, relatively coarse with a central dense core. A few showed a distinct membrane.

Type VI granules were round or oval covering a maximum area of $0.04 \mu^2$ (diameter 0.23μ) (Fig. 7 b, 8). The granule figures were similar to the type IV granules, only they had two indistinct subgranular components. The lamellar structures showed a few parallel layers, here and there forming scrolls. Each lamella was delicate with faint periodicity and straight or curved forms. The granular or almost homogeneous material showed a low density with or without a crystalline structure. No membrane could be seen around the granules. Most of the mast cells in the cell infiltrate contained granules of types I, II, III, and IV, the latter being most frequently observed (Table 1). Coexistence of these four types of granules are listed in Table 1. Types V and VI granules were small and showed no coexistence with type I, II, III, and IV granules.

The mast cells in the areas close to the tumors were spindle-shaped or bifurcated with cytoplasmic protrusions of various lengths (Fig. 9 a, b). The nuclei were oval with a cleft and lucent spots in the chromatin-rich areas. The smooth endoplasmic reticulum was dilated. The Golgi zone was

Table 1

Location of mast cells	Granule type	Frequency of appearance (%)	Maximum area of granules (μ^2)	Maximum diameter of granules (μ)	Coexistence with	Membrane-enclosed granules *) (%)
Outside cell infiltrate			0.38	0.7	—	0
In cell infiltrate	I	4.7	0.05	0.25	II, III	0
" " "	II	21.3	0.2	0.5	I, III, IV	2.7
" " "	III	0.6	0.2	0.5	I, II, IV	9.0
" " "	IV	60.4	0.28	0.6	II, III	10.6
" " "	V	11.1	0.08	0.33	VI	10.1
" " "	VI	1.9	0.04	0.23	V	11.1
Close to tumor			0.13	0.41		5.3

Average: 6.1

* Numbers of membrane-enclosed granules in relation to total number of each granule type.

wide with dilated vesicles. The granules were dense, of round, oval or polygonal forms covering a maximum area of $0.13 \mu^2$ (diameter 0.41μ) and showing subgranular patterns resembling those of type I and II granules (Fig. 9 a, b). Some showed blurred figures like Type V granules. No type IV and VI granules were found. A few granules were enclosed by a membrane.

Discussion

The granules of mast cells in basalioma stroma showed electron microscopical patterns, which were considered to correspond with immature, mature, and disintegrating granules (2).

Outside the cell infiltrate, the patterns of the mast cell granules were like those of mature granules as estimated by the two subgranular components and the membrane (Fig. 1 a, b) (2, 3).

Inside the cell infiltrate, the *first* granule type was considered to indicate immaturity because of the unparallel lamellae (Fig. 2 a, b). The long lamellae and frequent occurrence of these granules in some mast cells suggest an accelerated formation of granules by some factor in the basalioma. This consideration is supported by the wide Golgi zone with dilated vesicles. The *second* type of granules (Fig. 3) often covered larger areas than normal mature granules and showed distinct multilayered figures

made up of long straight lamellae with distinct periodicity and dense fine granular material. Therefore this type of granule was considered mature the substructures being large because of stimulated production. Crystalline structures were rarely found in these granules. This presumably suggests a lower protein content. The unparallel arranged lamellar structures of the *third* granule type (Fig. 4 b) reminded of immaturity, and the coarse granular material suggested disintegration of the granular material. The *fourth* granule type was characterized by swelling either of normal mature or of the second type granules (Fig. 5 a-d). This is concluded, because the lamellar structures were identical with those of normal mature granules and because of the low density of the granular material as well as the central lucent areas contained in the large, round granules (Fig. 4 c, 5 c). The swelling presumably conceals the density of the membrane, the granules with low density showing no dense membrane (Fig. 4 c, 5 a, 5 c, 5 d). Thus, the swelling of the granules may be considered an abnormal disintegration of the subgranular components brought about by unknown factors, possibly originating from destroyed corium. The *fifth* granule type probably reflects a restricted formation of the granules. The small sizes of the granules and few, indistinct lamellae indicated this. The

sixth granule type probably reflects swelling of type I granules. The wide Golgi area in the mast cells containing the fifth and the sixth granule type was probably hypofunctioning and influenced by the basalioma.

Close to the tumors, the granule figures were similar to those in the cell infiltrate with the exception of swelling granules.

The facts that approximately 6.1 % of all granules were enclosed by a membrane (Table 1) and that no signs of release or honey-comb like areas were found, suggest that degranulation of mast cells was scarce in the stroma of basal cell carcinomas. The problem, why increased numbers of mast cells were found in basalioma tissue, might be explained by 1. increased migration of mast cells into the basalioma area, 2. accelerated production of granules, 3. swelling of granules, 4. little discharge of granules.

SUMMARY

Granules of mast cells in the connective tissue of basal cell carcinomas were studied by the electron microscope. Outside the cell infiltrate, the granules showed figures similar to mature granules in normal human dermis. In the cell infiltrate, the figures of

the granules were classified by six different patterns. These granules showed two subgranular components like those of normal mature and immature granules, but their sizes and densities were different. Numerous granules in this area showed swelling. Close to the basal cell carcinoma the granule figures were similar to those in the cell infiltrate, only without granule swelling. Granules enclosed by a distinct membrane were found at a rate of 6.1 %.

Acknowledgement

Thanks are due to Mrs. Ruth Vetter, Mrs. Ursula Frank-Wüthrich, and Mr. John Winther for their technical assistance.

REFERENCES

1. Cawley, E. P. and Hoch-Ligeti, C.: Association of Tissue Mast-Cells and Skin Tumors. *AMA Arch. of Dermat.* 83: 146-50, 1961.
2. Kobayasi, T., Midtgård, K., and Asboe-Hansen, G.: Ultrastructure of Human Mast-Cell Granules. *J. Ultrastruc. Res.* 23: 153-155, 1968.
3. Lascano, E. F.: Mast Cells in Human Tumors. *Cancer* 11: 1110-1114, 1958.

FIGURES

- Fig. 1 a.* A mast cell outside the cell infiltrate. The cell contains a nucleus (N), scarce endoplasmic reticulum (R), a few mitochondria (M), and numerous granules. Dense masses of fine granular material were seen like subgranules (arrows). Cytoplasmic protrusions were scarce and small. $\times 24,000$.
- Fig. 1 b.* High magnification of a detail of Fig. 1 a. The dense masses in the granules show crystalline structures (arrows). All granules contain lamellae and fine granular material. $\times 60,000$.
- Fig. 2-8.* Granules of a mast cell in the cell infiltrate.
- Fig. 2 a.* Arrows indicate granules of the first type. The others are of the second type. $\times 60,000$.
- Fig. 2 b.* Arrows indicate granules of the first type. The framed arrow indicates a granule of the third type, while the rest are of the second type. G indicates the wide Golgi zone with dilated vesicles; C a centriole. Cytoplasmic protrusions are manifest. $\times 60,000$.
- Fig. 3.* All granules belong to third type. $\times 60,000$.
- Fig. 4 a.* Mast cell with numerous cytoplasmic protrusions and a nucleus with a deep cleft. The Golgi area (G) is wide with dilated vesicles. The granules are of the first, second, third, and fourth types. $\times 15,000$. Two granules (arrows) are shown in Fig. 4 c.
- Fig. 4 b.* Detail of Fig. 4 a. Arrows indicate granules of the third type; G the Golgi area. $\times 60,000$.
- Fig. 4 c.* Two type IV granules pointed out in Fig. 4 a. They show central lucent areas and lamellae in the peripheral zones. $\times 120,000$.
- Fig. 5.* Swollen granules of the fourth type and their variations. $\times 60,000$.
- Fig. 5 a.* A thin arrow shows a distinct membrane. One granule in the center of the photograph (framed arrow) shows extremely low density and no lamellar structures or membrane. Endoplasmic reticula (R) are dilated.
- Fig. 5 b.* Confluence of granules (arrows). Framed arrows indicate faint crystalline structures.
- Fig. 5 c.* Framed arrows indicate granules with central lucent areas. Thin arrows indicate single lamellae illustrating a membrane.
- Fig. 5 d.* Thin arrows indicate membranes. The granules pointed by the framed arrows show no or faint lamellae and no membrane. Endoplasmic reticula are dilated (R).
- Fig. 6.* Type V granules. The blurred patterns of the granules are different suggesting correspondence to types I, II, and III. Thin arrow indicates discharge of granule. Long cytoplasmic protrusions are evident. $\times 60,000$.
- Fig. 7 a, b.* Type V granules. Small granules show blurring of the subgranular components under high magnification. Some granules reveal lamellar structures. Arrow indicates faint crystalline structures. $\times 120,000$.
- Fig. 8.* Binuclear mast cell containing granules of the sixth type. Some of the granules show a distinct membrane. The cytoplasmic protrusions are long and well-developed. The Golgi area (G) is wide with dilated vesicles. C indicates a centriole, M mitochondria. $\times 60,000$.
- Fig. 9 a, b.* Two mast cells close to tumor border. The numbers indicate granule types equivalent to those in the cell infiltrate. The pattern of some granules in Fig. 9 b is blurred. Arrow indicates granule discharge. M: mitochondrion. Cytoplasmic protrusions of both cells are long and well-developed. $\times 60,000$.

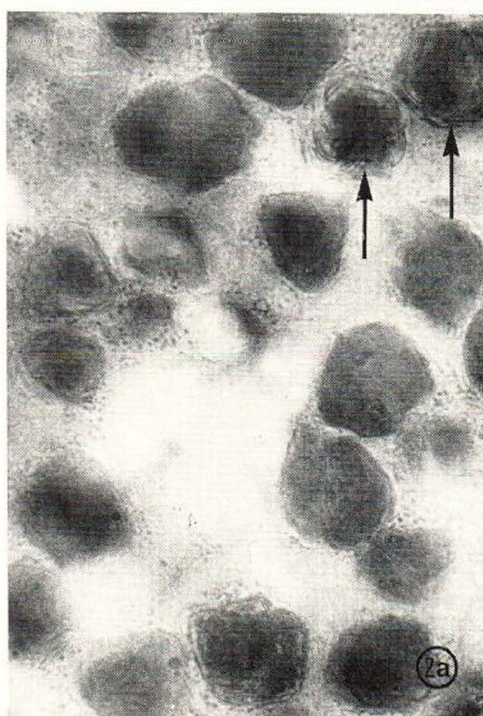
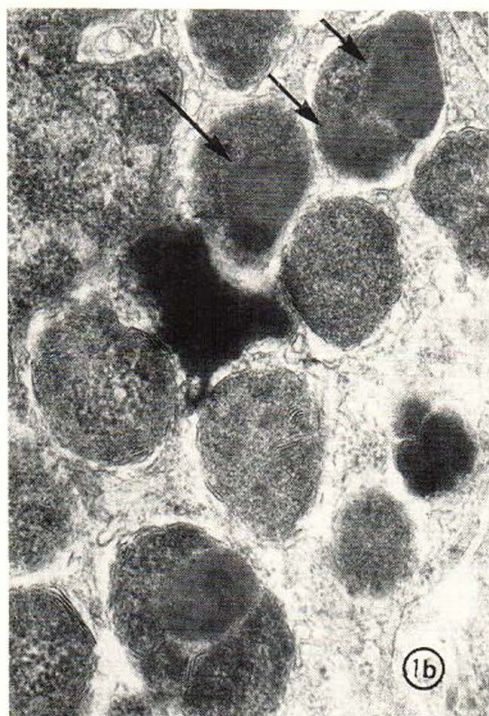
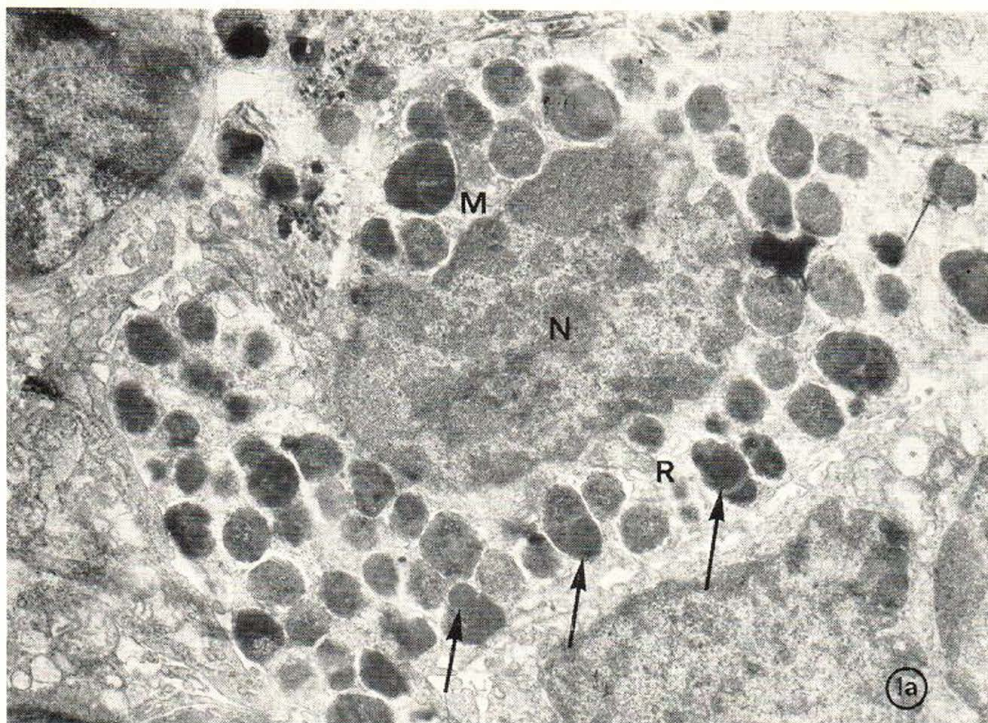


Fig. 1 a-b. — Fig. 2 a.

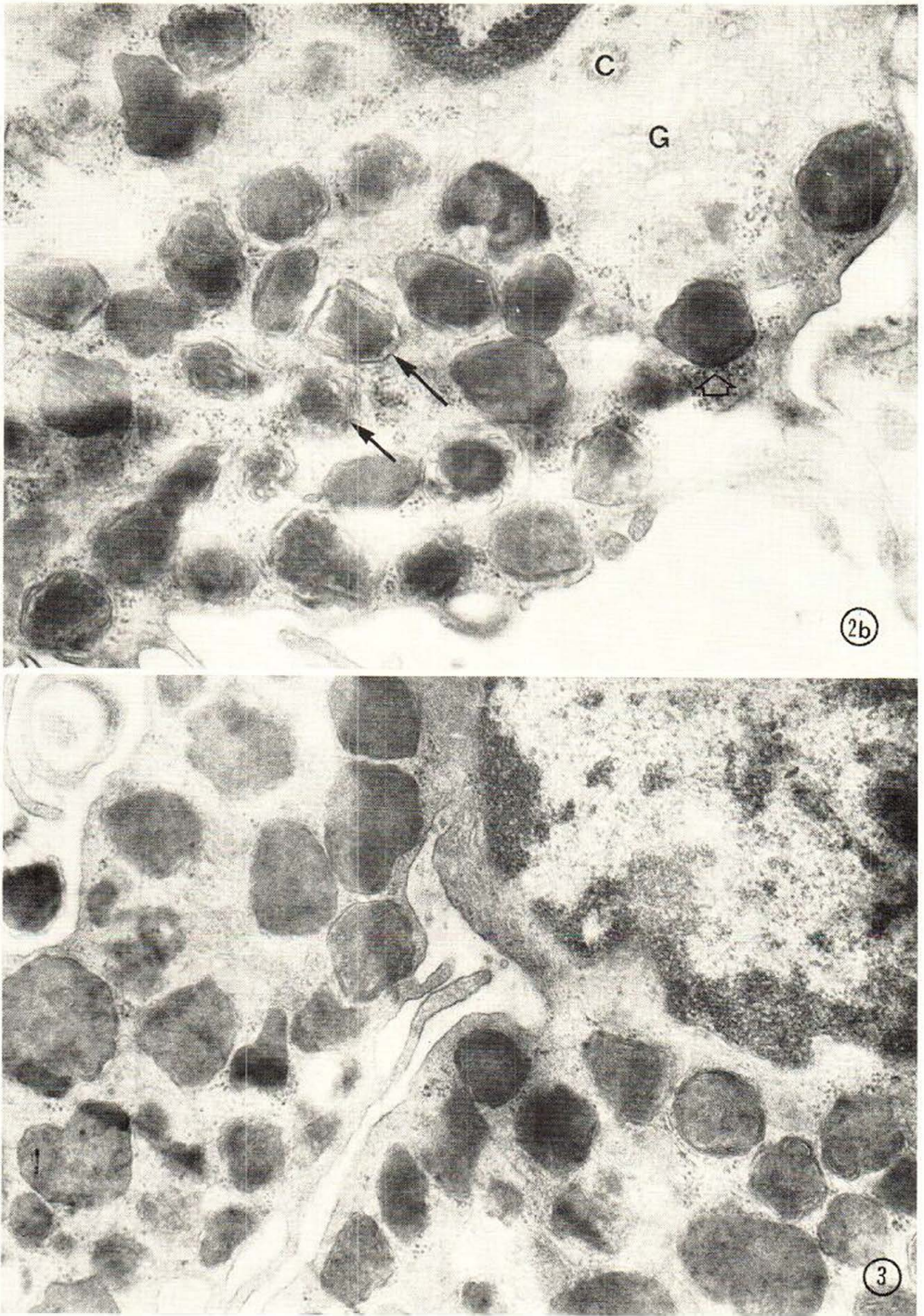


Fig. 2 b.—Fig. 3.

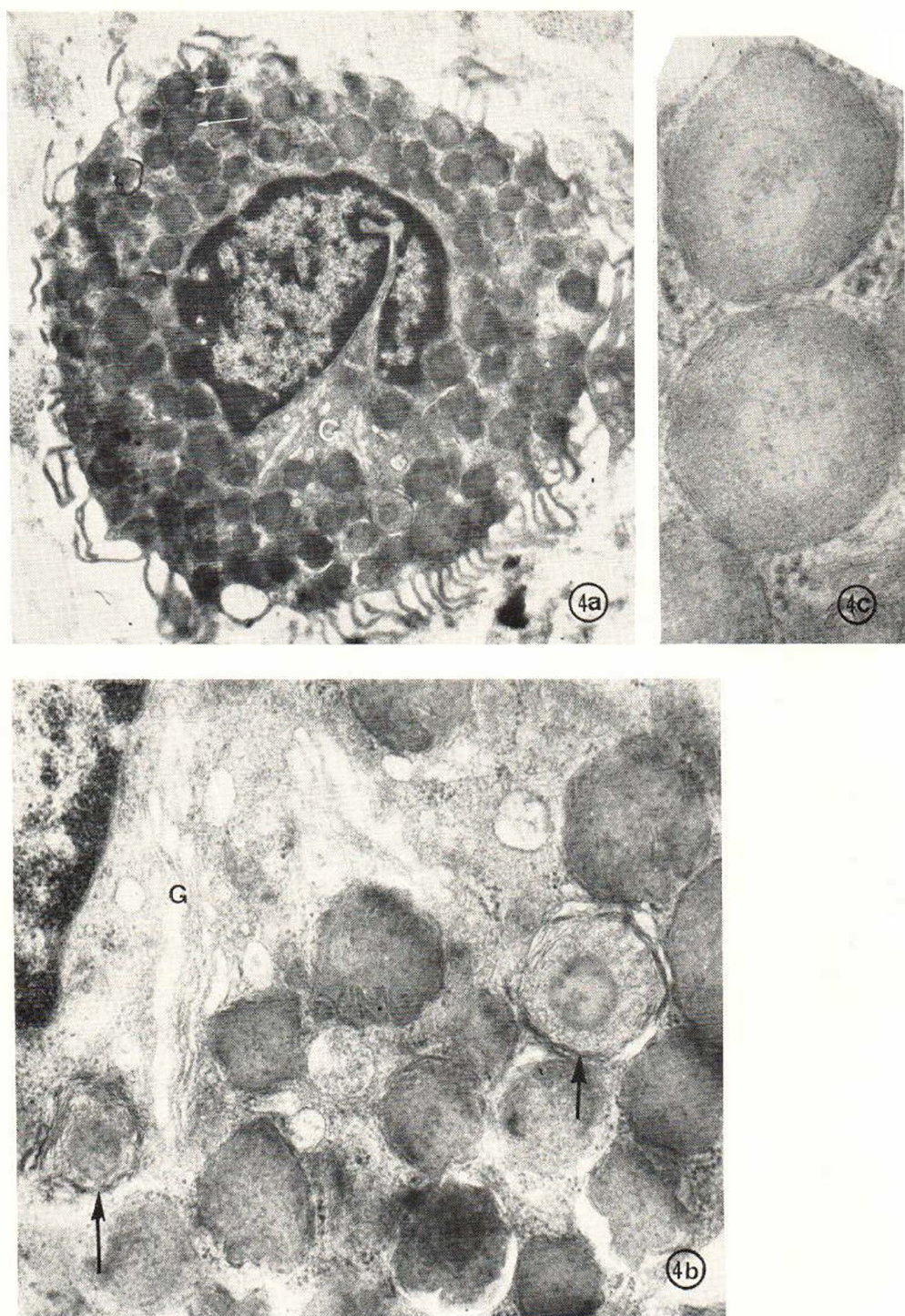


Fig. 4 a-c.

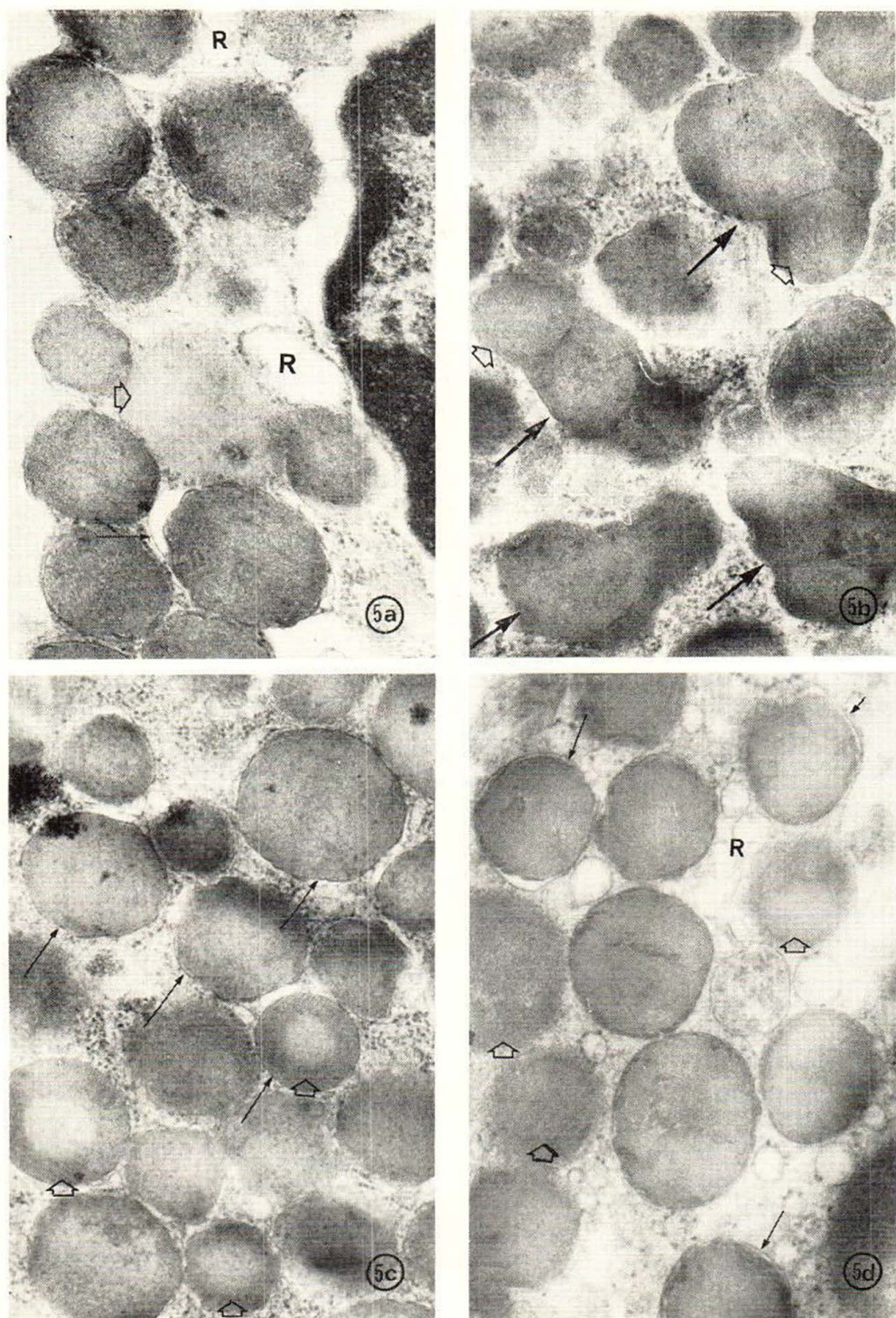


Fig. 5 a-d.

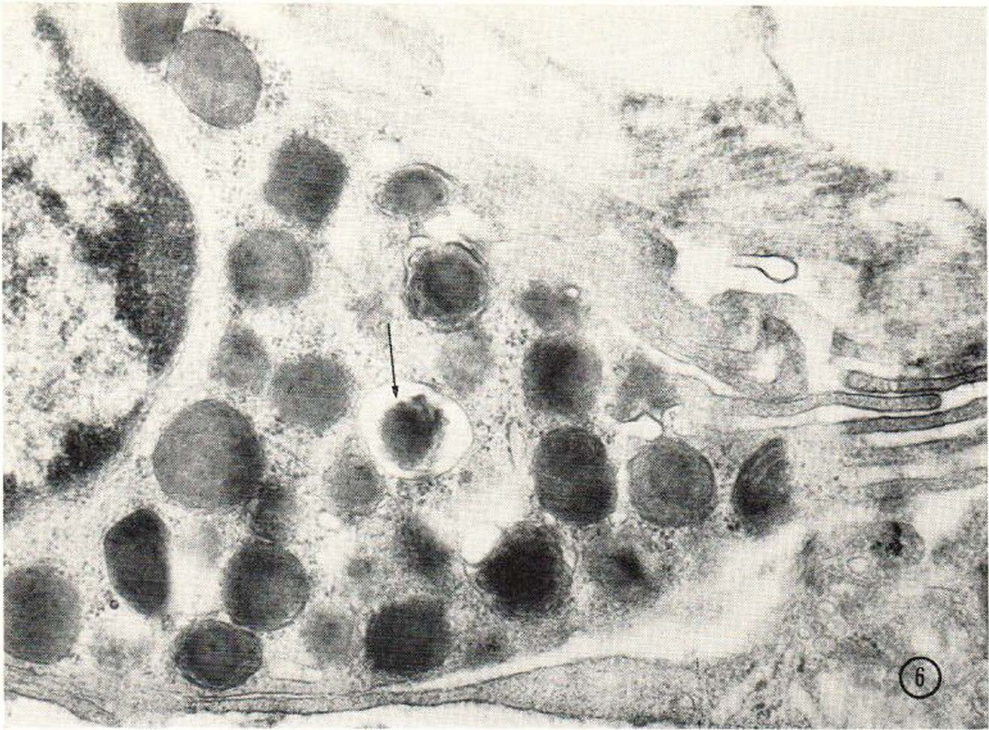


Fig. 6.

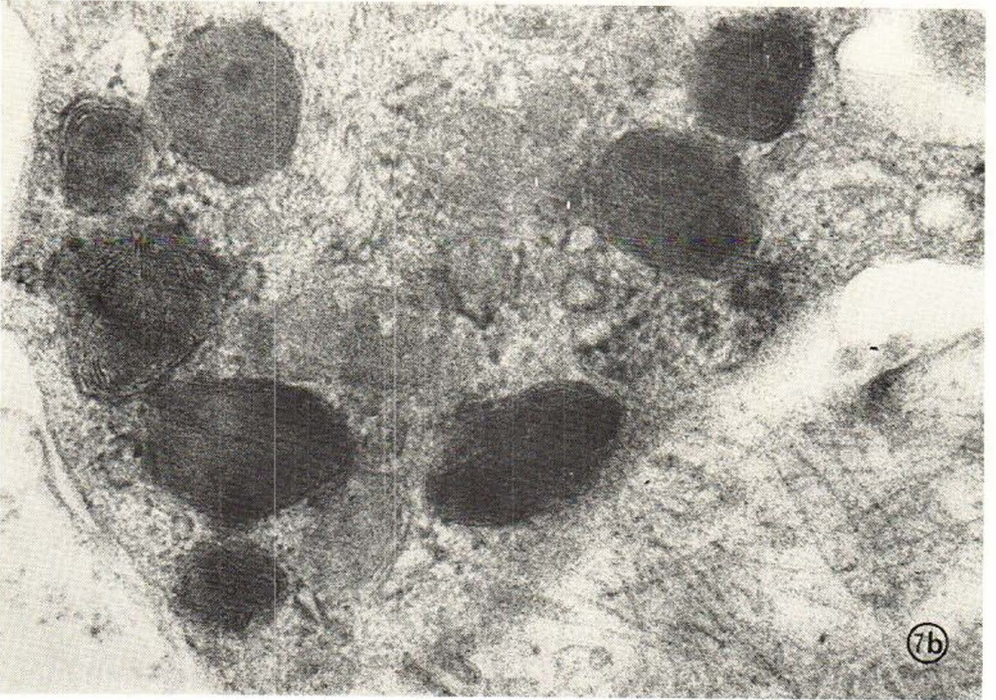
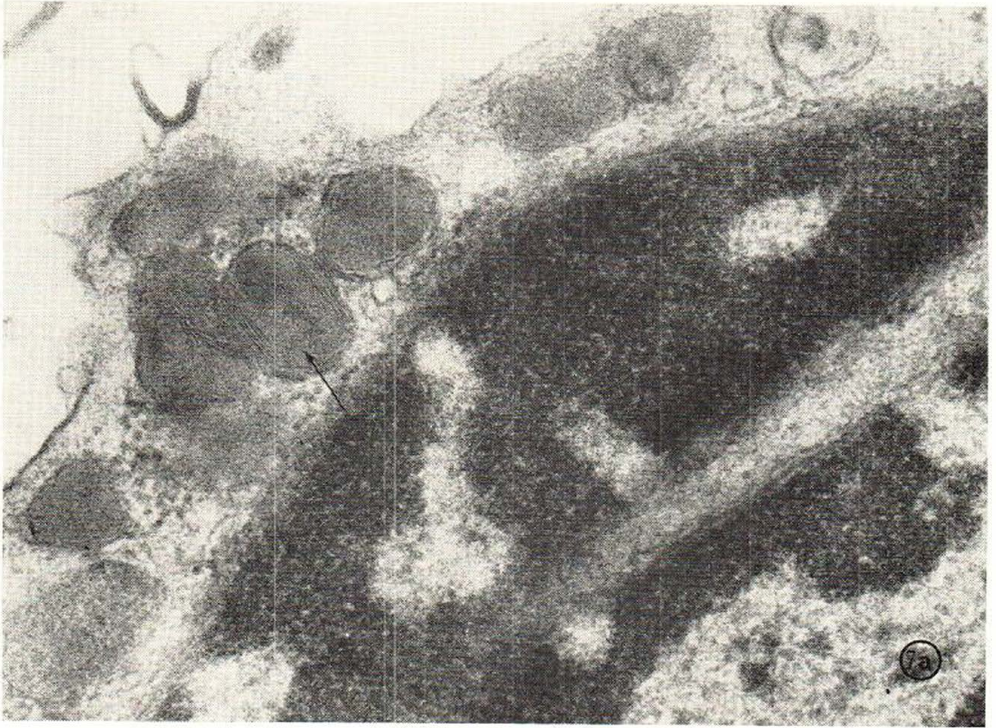

Fig. 7 a-b.

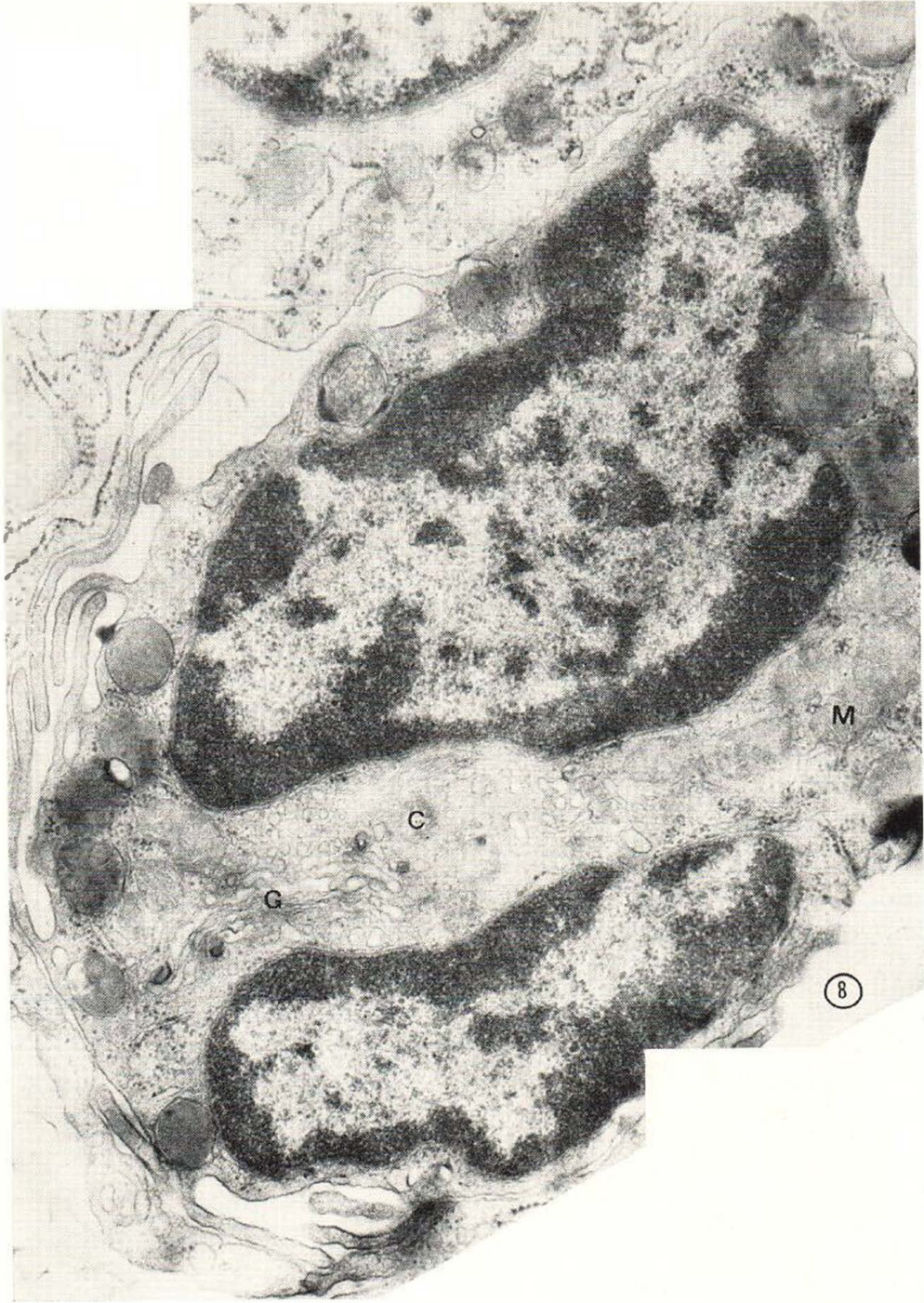

Fig. 8.

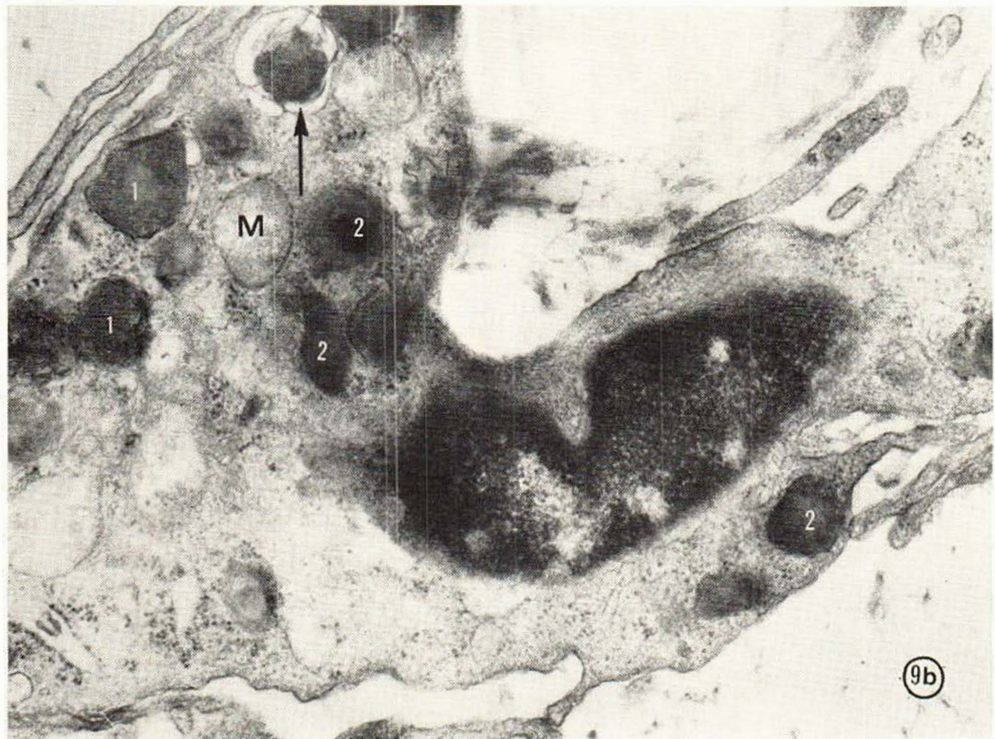
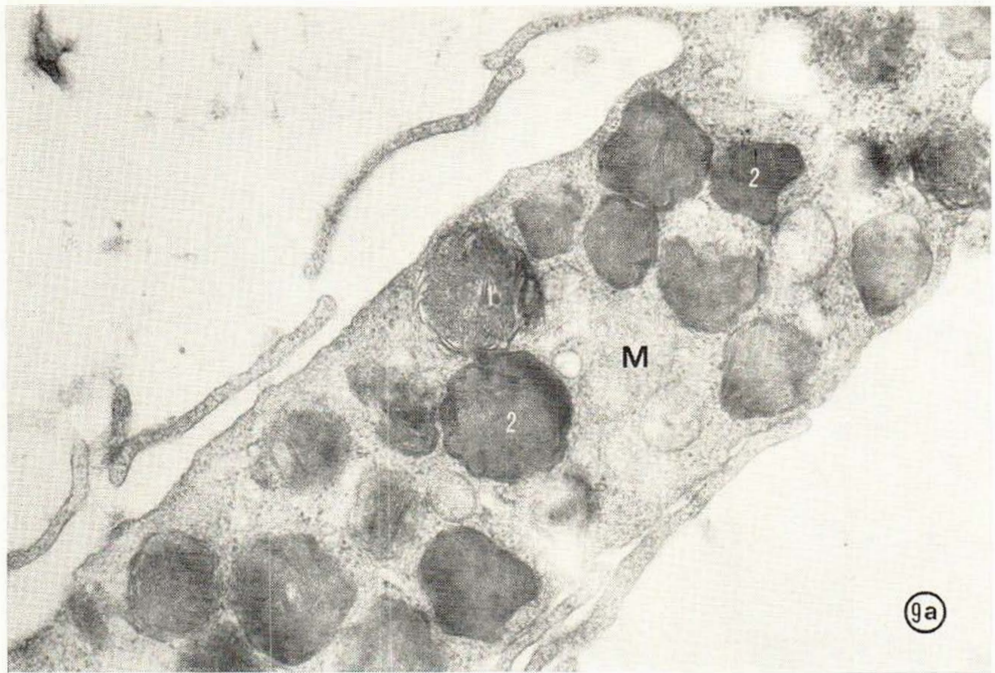
Fig. 9 a-b.