

Straight-hair Nevus in a Patient with Straight Hair

G. LANGE WANTZIN, T. POULSEN and
K. THOMSEN

*Departments of Dermatology and Pathology, The Finsen Institute,
Copenhagen, Denmark*

Lange Wantzin G, Poulsen T, Thomsen K. Straight-hair nevus in a patient with straight hair. *Acta Derm Venereol (Stockh)* 1983; 63: 570-571.

A case of straight-hair naevus in a 12-year old Korean boy with straight hair is presented. (Received March 19, 1983.)

G. Lange Wantzin, Department of Dermatology, The Finsen Institute, 49. Strandboulevarden. DK-2100 Copenhagen, Denmark.

Straight-hair nevus is a rare condition which has previously been reported in two Negro children, first by Day (1) in a 6-year-old Negro girl who also had ichthyosis hystrix and leukokeratosis, and in addition to normally curly Negro scalp hair she had distinct areas of the scalp with straight hairs. Later Gibbs & Berger (2) presented a 10-year-old Negro girl with extensive verrucous plaques of irregular outline limited to the right side of the scalp, with sparse, short and straight hairs in contrast to normal curly hairs on the remaining scalp.

Here we present a third case of straight hair nevus which differs from the first reported cases by occurring in a child with straight hair.

CASE REPORT

A 12-year-old Korean boy developed at the age of 2 years a linear verrucous scaly plaque on the right side of the vertex. The lesion increased in size in tact with the child's growth. The hairs in the

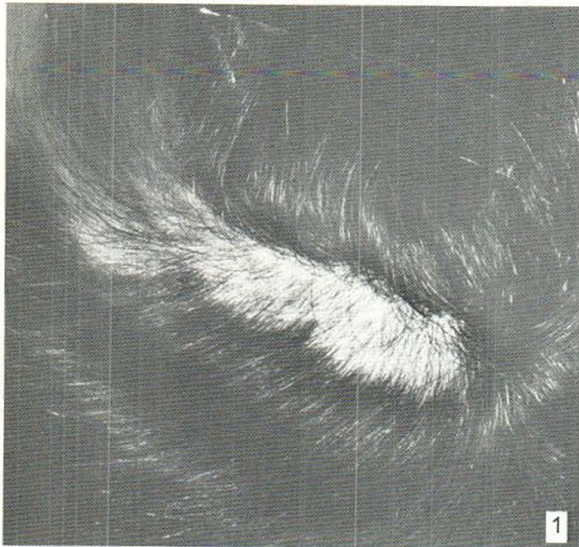


Fig. 1. The linear verrucous scaly plaque on the right side of the vertex.

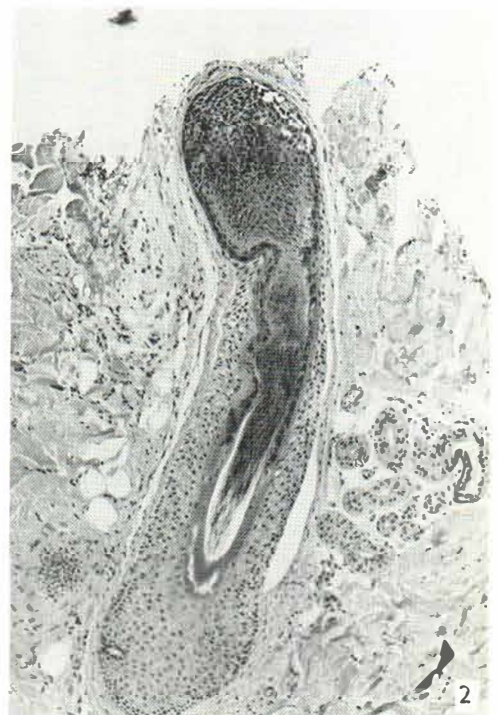


Fig. 2. Histology demonstrates a sharp bend of the follicular neck ($\times 100$).

involved area (Fig. 1) of the scalp were sparse, thin, short (average 1 cm), fair and straight, in marked contrast to the remaining black, thick, shiny and long hairs. All hairs in the affected area could easily be pulled out. A biopsy from the involved part of the scalp showed normal epidermis and dermis. In spite of numerous sections, only one hair follicle was found. This hair follicle demonstrated a sharp bend in the follicular neck (Fig. 2).

Examination of roots of plucked hairs from the involved scalp area showed approximately 90% in telogen phase.

DISCUSSION

Straight-hair nevus has previously been published in two Negro girls with curly Negro hair. Our patient is a Korean with straight hair and an almost linear unilateral lesion. The normal hair was black and thick, whereas the lesional hair was lighter, thin and short, and could easily be pulled out. The similarity between our patient and the patient reported by Gibbs & Berger (2) is striking. Like us, they found a sharp bend in the follicular neck. The significance of this finding is inexplicable. The increased proportion of hairs in telogen phase could explain the short length of the hairs and why the hairs were easy to pull out.

REFERENCES

1. Day TL. Straight-hair nevus, ichthyosis hystrix, leukokeratosis of the tongue. *Arch Dermatol* 1967; 96: 606.
2. Gibbs RC, Berger RA. The straight-hair nevus. *Int J Dermatol* 1970; 9: 47.