

Ultrastructural Localization of *in vitro* Binding Sites of Circulating Anti-basement Membrane Zone Antibodies in Bullous Pemphigoid¹

YUUCHIRO YAMASAKI and TAKEJI NISHIKAWA

Department of Dermatology, Keio University School of Medicine, Shinanomachi 35, Shinjuku, Tokyo 160, Japan

Yamasaki Y, Nishikawa T. Ultrastructural localization of *in vitro* binding sites of circulating anti-basement membrane zone antibodies in bullous pemphigoid. *Acta Derm Venereol (Stockh)* 1983; 63: 501-506.

Ultrastructural localization of the *in vitro* binding sites of circulating anti-basement membrane zone antibodies was investigated using two immunoperoxidase methods: the ordinary IgG indirect immunoperoxidase method and the complement immunoperoxidase method. The results indicated that the binding sites of the circulating autoantibodies were diverse. It is postulated that those antibodies demonstrable by the ordinary IgG indirect method and those antibodies possessing capacity to fix complement should bind to different sites of the basement membrane zone. Conventional electron microscopic observation of one lesional skin from bullous pemphigoid confirmed this possibility. (Received December 23, 1982.)

Y. Yamasaki, Department of Dermatology, Keio University School of Medicine, Shinanomachi 35, Shinjuku, Tokyo 160, Japan.

The presence of circulating autoantibodies to the basement membrane zone (BMZ) at the dermo-epidermal junction (DEJ) demonstrable by the indirect immunofluorescence (IIF) method is regarded as one of the characteristic immunopathological findings of bullous pemphigoid (BP). Jordon et al. (1) reported that most of the anti-BMZ antibodies (BP antibodies) have capacity to fix complement *in vitro* with the use of complement immunofluorescent (CIF) staining method. Recently, Nishikawa et al. (2) reported different immunofluorescent staining patterns of BP antibodies using CIF method.

In the present study, the immunoperoxidase method was used to investigate ultrastructural localization of the binding sites of anti-BMZ antibodies (BMZ-Ab) *in vitro*, according to the procedures described in the previous reports (3-11), with slight modifications, paying attention to the binding sites of both BMZ-Ab demonstrable by the indirect immunoperoxidase (IIP) method (IIP demonstrable BMZ-Ab) and complement fixing BMZ-Ab demonstrated with the complement immunoperoxidase (CIP) method (CF BMZ-Ab) comparatively.

MATERIALS AND METHODS

Sera. Seven serum samples from the 7 patients with BP were used, whose antibody titres are shown in Table I. As for cases 2 and 4, purified IgG fractions were used. Fresh normal human serum (NHS) was used as a source of C3.

Antigenic substrate. Normal human skin samples used as antigenic substrates in both IIP and CIP staining were immersed immediately after biopsy without fixation to preserve the antigenicity of the BMZ substances into 0.01 M PBS with 20% sucrose and 10% glycerol, pH 7.2 at 4°C for 90 min to minimize the possible destruction of the morphological details. They were thereafter embedded in

¹ This investigation was reported at the International Workshop of Investigative Dermatology in Kyoto, Japan, on June 1st, 1982.

Table I. The titre of the BMZ-Ab detected using both IIF and CIF staining methods

Sera	IIF	CIF
Case 1. Y. F.	320×	20×
Case 2. H. T.	640×	160×
Case 3. T. H.	320×	Not detected
Case 4. I. N.	10 240×	Not detected
Case 5. U. J.	10 240×	160×
Case 6. N. S.	160×	10×
Case 7. K. R.	160×	Not detected

OCT and stored in a deep freezer at -70°C . These frozen skin samples were cut into 6- μm frozen sections in a cryostat immediately before each experiment.

Horseradish peroxidase labelled antibodies. Horseradish peroxidase labelled rabbit antisera against human IgG (DAKO Lot 080, 20× diluted) and those against human C3 (DAKO Lot 020, 5× diluted) were used.

Staining procedure. Indirect IP and CIP methods were performed according to the IIF and CIF methods described by Nishikawa et al. (12) with slight modification for electron microscopic immunoperoxidase staining (9, 13). Briefly, in IIP, 4 drops of the BP serum diluted 1:10 with PBS were applied to the sections, which were then incubated in a moist chamber at room temperature or 37°C for 60 min. Following a PBS rinse, the sections were treated with the labelled anti-IgG for 60 min. In CIP, 2 drops of the BP serum, diluted 1:5 with PBS containing Mg^{2+} and Ca^{2+} , were applied to the sections and the same amount of fresh NHS diluted 1:5 with the same solution were overlaid on them. The sections were incubated in a moist chamber at 37°C for 60 min. Following a PBS rinse, the sections were treated with the labelled anti-C3 for 60 min.

These sections were then rinsed again in PBS and thereafter fixed in 2% glutaraldehyde solution at 4°C for 20 min. Following a PBS rinse and preincubation in 3,3'-diaminobenzidine (DAB) solution, the sections were incubated in DAB- H_2O_2 solution for 3 to 7 min. Following a PBS rinse, the sections were postfixed with 1% OsO_4 solution for 30 min and were dehydrated in graded alcohols. Finally, they were embedded in epoxy resin with the inverted gelatin capsule method. Ultrathin sections, both with and without electron staining, were observed with a JEM 100B electron microscope.

Negative control staining. Normal HS were used in place of BP sera in both IIP and CIP methods. In CIP method, heat-inactivated NHS were also used in place of the fresh NHS as a negative source of complement.

Lesional skin. As for case 6 only, an electron microscopic observation of the biopsied lesional skin could be done, although the lesional skin samples of the other cases were not available at that time.

RESULTS

Indirect IP demonstrable BMZ-Ab could be detected in all 7 BP sera. However, CF MBZ-Ab were detected in 4 of the 7 BP sera (Table II). Although the fine structure of the

Table II. The ultrastructural deposition patterns and sites of the reaction products

Mass. & discont = massive and discontinuous, BCC = basal cell cytomembrane, cont. = continuous, LL = lamina lucida

Serum	IIP	CIP
Case 1 Y. F.	Mass. & discont., BCC	Cont., LL
Case 2 H. T.	Mass. & discont., BCC	Cont., LL
Case 3 T. H.	Mass. & discont., BCC	Not detected
Case 4 I. N.	Mass. & discont., BCC	Not detected
Case 5 U. J.	Mass. & discont., BCC	Mass. & discont., BCC, cont., LL
Case 6 N. S.	Mass. & discont., BCC	Cont., LL
Case 7 K. R.	Mass. & discont., BCC	No detected

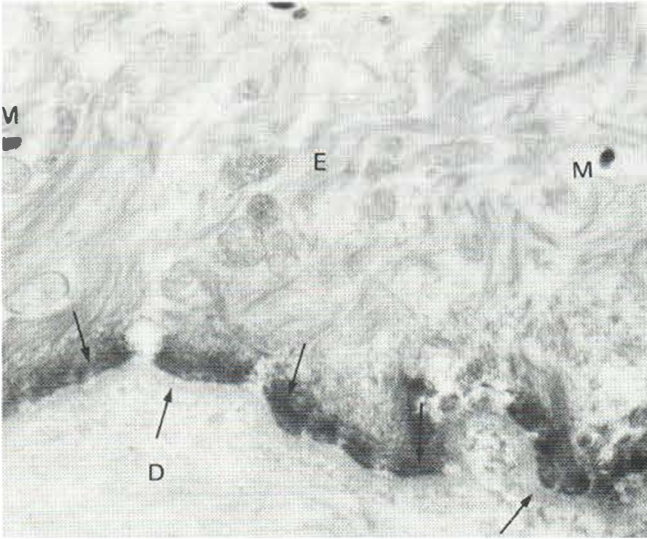


Fig. 1A. IIP. Unstained ultrathin section. Case 7. The reaction products (*arrows*) are deposited along the basal cell cytomembrane in a massive and discontinuous fashion. *E*, epidermis; *D*, dermis; *M*, melanin granules ($\times 18\,000$).

epidermis, especially the intercellular region including the cytomembrane, revealed considerable evidence of destruction, BMZ at DEJ retained a relatively well-preserved morphology (Figs. 1A, 1B, 2).

Ultrastructural localization of the *in vitro* binding sites of BMZ-Ab was demonstrated as deposition of the electron-dense reaction product in the unstained ultrathin sections (Figs. 1A, 2). IIP-demonstrable BMZ Ab were localized along the basal cell cytomembrane at DEJ in a massive and discontinuous fashion (Table II, Fig. 1A, B). The deposition of the reaction product was dense at its lowermost portion, with a well-demarcated lower border, and the deposited reaction product extended towards the intracellular direction with apparent continuity to the tonofilaments (Fig. 1A, B). By contrast, CF BMZ-Ab were localized along the lamina lucida in a continuous fashion (Table II, Fig. 2). The reaction product was deposited densely immediately below the basal cell cytomembrane and revealed extension towards the basal lamina with decreasing density (Fig. 2). The only

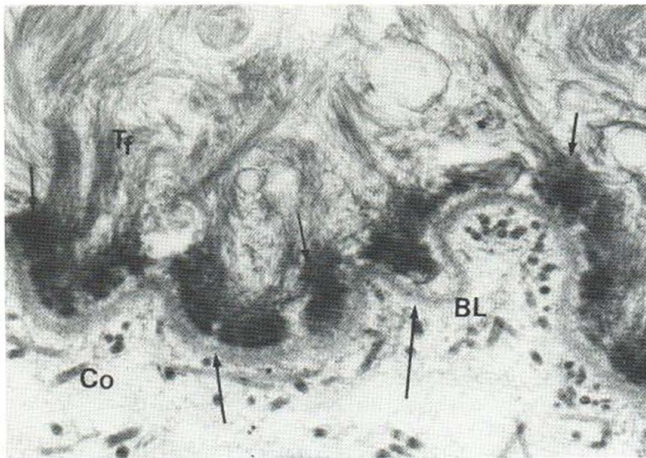


Fig. 1B. IIP. Stained ultrathin section. Case 7. The deposition of the reaction products (*arrows*) is dense at its lowermost portion, with well-demarcated lower border, and the deposited reaction products extend in an intracellular direction with apparent continuity with the tonofilaments (*Tf*). *Co*, dermal collagen; *BL*, basal lamina ($\times 27\,000$).

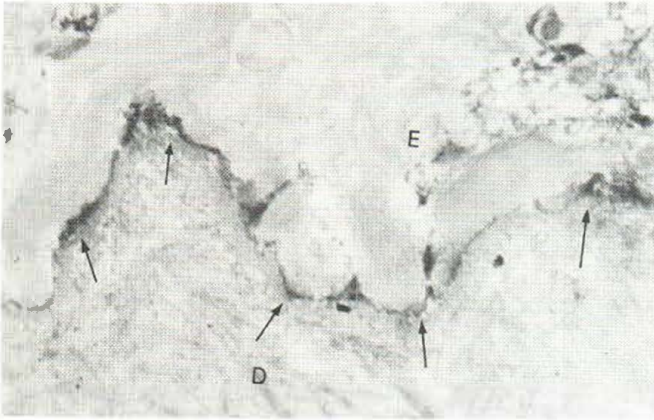


Fig. 2. CIP. Unstained ultrathin section. Case 6. The reaction products (arrows) are deposited along the lamina lucida immediately below the basal cell cytomembrane in a continuous fashion. E, epidermis; D, dermis ($\times 18\,000$).

exceptional case, case 5, revealed both continuous and discontinuous deposition simultaneously, when using CIP method (Table II).

Negative control staining resulted in absence of the deposition of the reaction product.

With the ultrastructural observation of the lesional skin of case 6, it was found that the basal cell itself revealed occasional evidence of cellular degenerative change. The basal cell was occasionally torn off at the lowermost part of the cytoplasm, apparently leaving small residual amounts of cytoplasm still attached to the DEJ (Fig. 3). The basal portion of

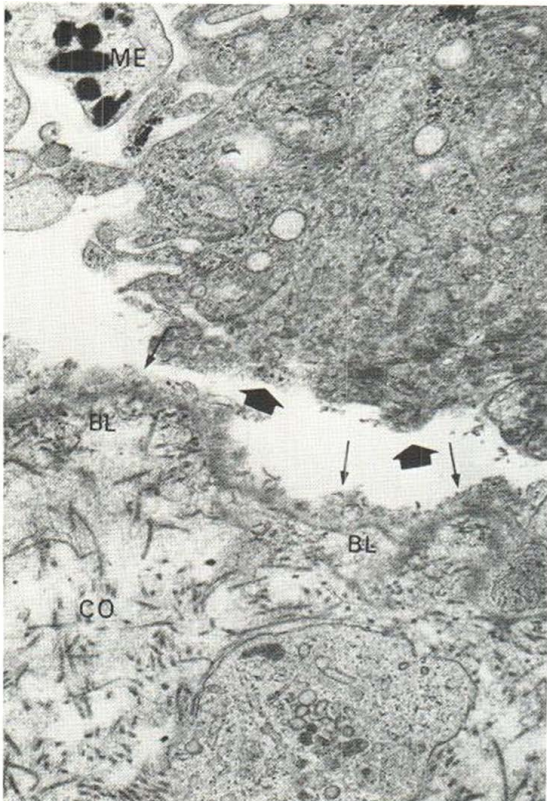

Fig. 3. Ultrastructural observation of the lesional skin. Case 6. The basal cell (BC) is torn off at its lowermost portion, leaving apparently small residual amounts of cytoplasm (small arrows) still attached to the DEJ. The basal portion of the basal cell cytomembrane can no longer be identified either on the roof (larger arrows) or on the base (small arrows) ($\times 18\,000$).

the basal cell cytomembrane could no longer be identified either on the roof or on the base (Fig. 3).

DISCUSSION

In the present study, in vitro binding sites of IIP-demonstrable BMZ-Ab were localized at the inner part of the basal cell cytomembrane in a massive and discontinuous fashion, showing apparent continuity with the tonofilaments, while CF BMZ-Ab bound to the lamina lucida with linear continuity. Most previous works using the direct method indicate that bound IgG and C3 in BP patients' skin are localized at the lamina lucida with linear continuity (3-5, 7-9), while only Schmitt et al. (6) reported massive and discontinuous localization of bound immunoglobulins almost identical with that demonstrated by the ordinary IgG IIP method in the present study. The in vitro binding sites of BMZ-Ab in the previous reports (10, 11) are identical with those in vivo, i.e. linear continuous deposition along the lamina lucida, although in those in vitro studies, non-frozen small skin pieces were incubated in the BP sera (1, 11), which is methodologically different from the ordinary IIF staining.

As regards the bound IgG and C3 in BP patients' skin, the present authors have already confirmed their linear continuous localization along the lamina lucida (9), but the ultrastructural localization of the in vitro binding sites of BMZ-Ab demonstrated in the present study were not entirely identical with those of the previous reports (10, 11). The identical ultrastructural localization of CF BMZ-Ab as demonstrated by us, vis-à-vis that of BMZ-Ab as demonstrated by other workers, led us to speculate that BMZ-Ab detected by others had in fact a capacity to fix complement. The fine structure of the blister-forming skin lesions in BP has already been reported in detail, and junctional separation is a well-established phenomenon (14-18). The fact that CF BMZ-Ab bind to the lamina lucida with linear continuity may indicate the possible pathogenetic significance of CF BMZ-Ab and the complement system. However, the reason why this linear localization pattern as demonstrated by the CIP method is not demonstrable using the ordinary indirect method is still a problem to be solved.

Apart from the above strange phenomenon, the difference in the binding sites and patterns between IIP-demonstrable BMZ-Ab and CF BMZ-Ab may suggest the existence of heterogenous BMZ-Ab in BP (2). Indirect IP-demonstrable BMZ-Ab appeared to gain access to and bind the inner portion of the basal cell cytomembrane of the frozen-sectioned skin substrates used in the present study, but not to that of the non-frozen ones used by most other workers (10, 11). The electron microscopic findings of one lesional skin in the present study suggested that not only junctional separation but also basal cell destruction or degeneration may occur in BP. Yoshioka also reported similar findings based on her electron microscopic observation (19). The present authors therefore speculate that IIP-demonstrable BMZ-Ab are the heterogeneous autoantibodies against the degenerated basal cell cytomembrane produced during the blister-forming process in BP, and that these can gain access to and bind to the antigen which may exist at the inner portion of the basal cell cytomembrane, when frozen-sectioned skin substrates are employed, probably because freezing can induce degeneration of the membrane components and can also alter the penetration characteristics of membranes.

ACKNOWLEDGEMENTS

The authors are grateful to Dr. H. Hatano, Emeritus Professor, Department of Dermatology, Keio University School of Medicine, for his kind review of the manuscript. This study was supported by the research grant from Keio University School of Medicine.

REFERENCES

1. Jordon RE, Sams Jr WM, Beutner EH. Complement immunofluorescent staining in bullous pemphigoid. *J Lab Clin Med* 1969; 74: 548.
2. Nishikawa T, Kurihara S, Harada T, Hatano H. Binding of bullous pemphigoid antibodies to basal cells. *J Invest Dermatol* 1980; 74: 389.
3. Schaumburg-Lever G, Rule A, Schmidt-Ullrich B, Lever F. Ultrastructural localization of in vivo bound immunoglobulins. A preliminary report. *J Invest Dermatol* 1975; 64: 47.
4. Holubar K, Wolff K, Konrad K, Beutner EH. Ultrastructural localization of immunoglobulins in bullous pemphigoid skin. *J Invest Dermatol* 1975; 64: 220.
5. Schmidt-Ullrich B, Rule A, Schaumburg-Lever G, Leblanc C. Ultrastructural localization of in vivo bound complement in bullous pemphigoid. *J Invest Dermatol* 1975; 65: 217.
6. Schmitt D, Germain D, Thivolet J. A simple technique for immunoelectronmicroscopic localization of Ig on tissue sections with special reference to cutaneous pathology. *Arch Dermatol Res* 1977; 259: 235.
7. Masutani M, Ogawa H, Taneda A, Shoji M, Miyazaki H. Ultrastructural localization of immunoglobulins in the dermo-epidermal junction of patient with bullous pemphigoid. *J Dermatol (Tokyo)* 1978; 5: 107.
8. Maciejewski W, Braun-Falco O, Scherer R. Immunoelectronmicroscopical localization of in vivo bound complement C3 in bullous pemphigoid with the use of the peroxidase-antiperoxidase multistep technique. *Arch Dermatol Res* 1979; 266: 205.
9. Yamasaki Y. Immunopathological study on perilesional pemphigus skin. A comparative light and electron microscopic study of the localization of in vivo bound IgG and C3. *J Dermatol (Tokyo)* 1981; 8: 165.
10. Albini B, Holubar K, Shu S, Wolff K. Enzyme antibody methods in immunodermatology. In: Beutner EH, Chorzelski T & Bean SF, eds. *Immunopathology of the skin*, 2nd edn. New York: Wiley. 1979: 93-134.
11. Pehamberger H, Gschnait F, Konrad K, Holubar K. Bullous pemphigoid, herpes gestationis and linear dermatitis herpetiformis: Circulating anti-basement membrane zone antibodies; in vitro studies. *J Invest Dermatol* 1980; 74: 105.
12. Nishikawa T, Kurihara S, Harada T, Sugawara M, Hatano H. Capability of complement fixation of pemphigus antibodies in vitro. *Arch Dermatol Res* 1977; 260: 1.
13. Yamasaki Y, Hashimoto T, Nishikawa T. Dermatitis herpetiformis with linear IgA deposition: Ultrastructural localization of in vivo bound IgA. *Acta Derm Venereol (Stockh)* 1982; 62: 401.
14. Braun-Falco O, Rupec M. Elektronenmikroskopische Untersuchungen zur Dynamik der Blasenbildung bei bullösem Pemphigoid. *Arch Klin Exp Dermatol* 1967; 230: 1.
15. Kobayashi T. The dermo-epidermal junction in bullous pemphigoid. An electron microscopic study. *Dermatologica* 1967; 134: 157.
16. Schaumburg-Lever G, Orfanos CE, Lever WF. Electron microscopic study on bullous pemphigoid. *Arch Dermatol* 1972; 106: 662.
17. Caputo R, Bellone AG, Crosti C. Pathogenesis of the blister in cicatricial pemphigoid and bullous pemphigoid. A comparative ultrastructural study. *Arch Dermatol Forsch* 1973; 247: 181.
18. Dabrowski J, Jablonska S, Chorzelski TP, Jarzabek-Chorzelska M, Maciejewski W. Electron microscopic studies in dermatitis herpetiformis in relation to the pattern of immune deposits in the skin. *Arch Dermatol Res* 1977; 259: 213.
19. Yoshioka J. Studies of pemphigoid. 2. Histopathological and electron microscopic investigations. *Skin Research (Osaka)* 1981; 23: 55. (In Japanese.)