

# Are Hyperlinear Palms and Dry Skin Signs of a Concomitant Autosomal Ichthyosis Vulgaris in Atopic Dermatitis?

MANIGÉ FARTASCH, THOMAS L. DIEPGEN and OTTO PAUL HORNSTEIN

Department of Dermatology, University of Erlangen, F.R.G.

In 30% to 40% of cases atopic dermatitis (AD) is believed to be associated with autosomal dominant ichthyosis vulgaris (ADI). The diagnosis of ADI can be proved by the ultrastructural demonstration of a defective keratohyalin (KH) synthesis, resulting in minute granules of crumbly appearance in only one layer of granular cells. To investigate the suggested frequent association of ADI with AD, ultrastructural examination of dry skin of 49 AD patients was performed. Only in 2 patients abnormal KH was demonstrated by electron microscopy. 17 patients, including the 2 patients with abnormal KH, showed hyperlinear palms. The present study shows that hyperlinear palms and dry skin are in most cases a phenotypic marker of AD alone and not a sign of concomitant ADI. A histologically one-layered or absent stratum granulosum may occur in the dry skin of patients with only AD and does not indicate a manifestation of concomitant ADI in all cases. **Key words:** Ultrastructural analysis; Atopic dermatitis; Ichthyosis.

Dr med. M. Fartasch, Department of Dermatology, University of Erlangen, Hartmannstr. 14, D-8520 Erlangen, West-Germany.

Atopic dermatitis (AD) and autosomal dominant ichthyosis (ADI) is believed to be frequently associated. The incidence of ichthyosis in atopic dermatitis ranges widely, from 2% to 40%, according to different studies (1-6). Some atopic features are seen in at least 50% of patients with ADI (7-9). Recent studies (2, 4-6) concluded that in 30% to 40% of the cases AD is associated with ADI. In these studies determination of the percentage of patients with both AD and ADI was based on clinical signs such as hyperlinear palms, keratosis pilaris and dry skin, as well as on the histological features of a reduced granular layer thickness (2, 4-6, 10). Depending on the time of year when the patients were examined, clinical features of ichthyosis vulgaris may be inapparent, but palmar hyperlinearity is usually a persistent finding. This feature has been described in one-third to one-half of patients with AD (10, 11).

Ultrastructural analyses of ADI performed by An-

ton-Lamprecht (12) demonstrated a severe disturbance of keratohyalin (KH) synthesis resulting in fewer and abnormal KH-granules. This abnormal KH is present in all ADI patients also in clinically unaffected skin (12-14). Thus, the defective KH of ADI can be used as a genetic marker to control the presence of the ADI gene (13).

In order to investigate the suggested frequent association ultrastructural analysis of AD patients was performed.

## PATIENTS AND METHODS

Noneczematous but dry skin of 49 atopic patients (31 males, 18 females) aged 15-36 years was investigated using light and electron microscopy. The diagnosis of AD was established according to Haniffin and Rajkas (1). Further requirements for inclusion were a history of persistent dry skin and the absence of eczema on the lateral aspect of the buttock. All patients were examined for the presence of hyperlinear palms (i.e., deep linear grooves crossing perpendicular to the thenar and/or hypothenar eminences (15)) and soles.

Punch biopsy specimens (4 mm) were taken from the skin of the upper outer quadrant of the buttock and fixed in 2.5% glutaraldehyde and postfixated with osmium tetroxide. The samples were then dehydrated in a graded series of ethanol and then embedded in Epon 812. Semithin sections of 1-2 µm were cut and stained with 1% methylene blue and examined by light microscopy. Ultrathin sections were stained in uranyl acetate plus lead citrate prior to the examination in a JEOL 100 CX transmission electron microscope.

## RESULTS

Light microscopic examination of semithin sections showed a normal thickness (16) of the granular layer

Table 1. Light microscopic examination

Str. granulosum (layers)	Number of patients <i>n</i> = 49
2-3	21
1-2	17
0-1	11

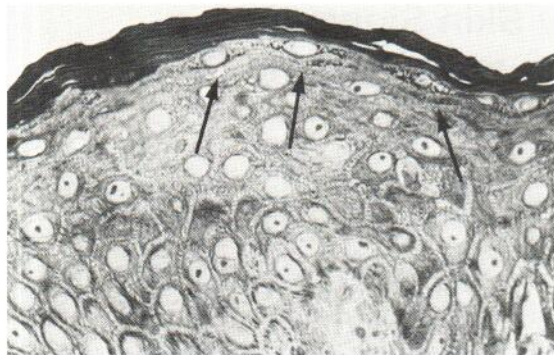


Fig. 1a. Semithin section: two-layered str. granulosum (-->) in atopic dermatitis ( $\times 1000$ ).

(2–3 layers) in 21 patients and a thinned granular layer (1 or 1–2 layers) in 17 patients (Fig. 1a), while 11 patients exhibited an absent or interrupted one-cell layer (Fig. 1b, Table I). Electron microscopy demonstrated typical abnormal KH granules of crumbly appearance in only 2 patients (Fig. 2a). The 9 remaining subjects with absent or interrupted stratum granulosum showed ultrastructurally normal KH (Fig. 2b). Three patients had histological signs of eczematous inflammation with dermal infiltration of mononuclear cells. 17 patients (35%), including the patients with abnormal KH, showed hyperlinear palms.

## DISCUSSION

The small percentage of patients with associated ADI (2 of the 49 AD patients (4%)) is in contrast with the

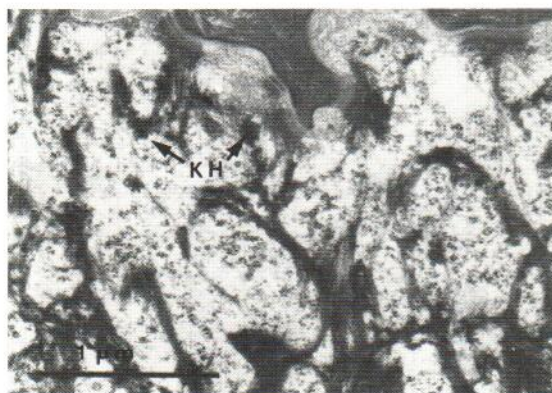

Fig. 2a. Abnormal crumbly keratohyalin (KH) proving autosomal dominant ichthyosis vulgaris (ADI) in atopic dermatitis (AD) ( $\times 19000$ ).

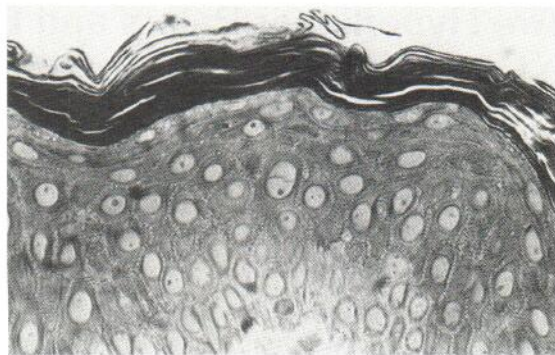


Fig. 1b. Absence of str. granulosum in an atopic patient without ADI ( $\times 1000$ ).

findings of those investigators who did not perform ultrastructural analyses (4–7). Whether hyperlinear palms in a patient with AD is unique for AD or a manifestation of ichthyosis vulgaris has been unclear.

On the basis of ultrastructural investigations (3, 13) it seems most reasonable to assume that palmar hyperlinearity (ichthyotic hand) and dry skin (17) are in fact mainly traits of atopic dermatitis.

Though it has been widely believed that a one-layered or absent stratum granulosum indicates a concomitant manifestation of ADI, the present ultrastructural study clearly demonstrates that a one-layered or absent stratum granulosum in fact does not indicate a manifestation of concomitant ADI in all cases of AD. 9 subjects with a one-layered or absent stratum granulosum in light microscopy had ultrastructurally normal KH.

The reduction of KH may be due to the suppressive

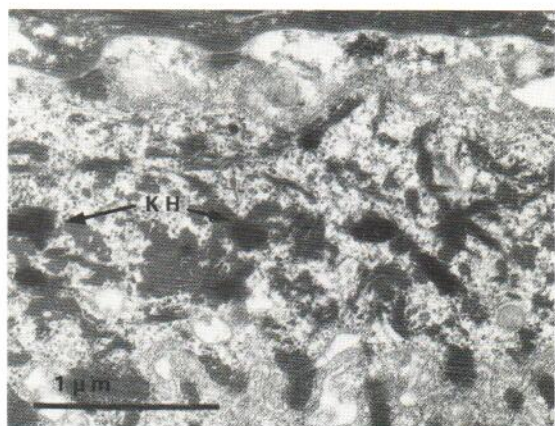


Fig. 2b. Structurally normal but minute KH-granules, too small to be identified by light microscopy ( $\times 19000$ ).

influence of AD on keratinization and KH synthesis. This is supported also by the observation that bone marrow transplantation in children with Wiskott-Aldrich syndrome caused a simultaneous disappearance of AD and xerosis associated with skin lesions (18). Thus, dry skin in AD appears, at least partly, to be related to the immune dysfunction and is not due to a primary defect of keratinization.

## REFERENCES

- Hanifin JM, Rajka G. Diagnostic features of atopic dermatitis. *Acta Derm Venereol* (Stockholm) 1980; Suppl 92: 44-47.
- Leutgeb CH, Bandmann HJ, Breit R. Handlinienmuster. Ichthyosis vulgaris und Dermatitis atopica. *Arch Dermatol Forsch* 1972; 244: 354-356.
- Fartasch M, Hancke E, Anton-Lamprecht I. Ultrastructural study of the occurrence of autosomal dominant ichthyosis vulgaris in atopic eczema. *Arch Dermatol Res* 1987; 279: 270-272.
- Uehara M, Hayashi S. Hyperlinear palms. *Arch Dermatol* 1981; 117: 490-491.
- Uehara M, Miyauchi H. The morphologic characteristics of dry skin in atopic dermatitis. *Arch Dermatol* 1984; 120: 1186-1190.
- Uehara M. Clinical and histological features of dry skin in atopic dermatitis. *Acta Derm Venereol* (Stockh) 1985; Suppl 114: 82-86.
- Frost P, van Scott EJ. Ichthyosiform dermatoses. Classification based on anatomic and biometric observations. *Arch Dermatol* 1966; 94: 113.
- Rajka G. *Atopic dermatitis*. Saunders, London 1975.
- Wells RS, Kerr CB. Clinical features of autosomal-dominant and sex linked ichthyosis in an English population. *Br Med J* 1966; 1: 947-950.
- Mevorah B, Marazzi A, Frenk E. The prevalence of accentuated palmoplantar markings and keratosis pilaris in atopic dermatitis, autosomal dominant ichthyosis and control dermatological patients. *Br J Dermatol* 1985; 112: 679-685.
- Hoyer H, Agdal N, Munkvad M. Palmar hyperlinearity in atopic dermatitis. *Acta Derm Venereol* (Stockholm) 1982; 62: 346-347.
- Anton-Lamprecht I. Zur Ultrastruktur hereditärer Verhornungsstörungen. III. Autosomal-dominante Ichthyosis vulgaris. *Arch Dermatol Forsch* 1973; 248: 149-172.
- Berndt-Schumann C. Neurodermitis atopica und autosomal-dominante Ichthyosis vulgaris: eine ultrastrukturelle Studie zur genetischen Korrelation beider Dermatosen anhand eines ausgewählten Patienten-Kollektivs. Dissertation 1982. University of Heidelberg, Heidelberg, Department of Dermatology.
- Papst B. Vergleichende ultrastrukturelle Untersuchungen an befallener und nicht befallener Haut von Patienten mit autosomal-dominanter Ichthyosis vulgaris und primärem Strukturdefekt des Keratohyalins. Dissertation 1979, University of Heidelberg, Heidelberg, Department of Dermatology.
- Leung DJM, Rhodes AR, Geha SR. Atopic dermatitis. In: Fitzpatrick TB, ed. *Dermatology in general medicine*. 3rd ed. New York: McGraw-Hill, 1987; Vol. 1: 1385-1408.
- Erickson L, Major MC, Kahn U, Kahn G. The granular layer thickness in atopy and ichthyosis vulgaris. *J Invest Dermatol* 1970; 54: 11-12.
- Finlay AY, Nicholls S, King CS, Marks R. The dry non-eczematous skin associated with atopic eczema. *Br J Dermatol* 1980; 102: 249-256.
- Saurat JH, Woodley D, Helfer N. Cutaneous symptoms in primary immunodeficiencies. *Curr Probl Derm* 1985; 13: 50-91.