

Clinical Studies of 20% Azelaic Acid Cream in the Treatment of Acne Vulgaris

Comparison with Vehicle and Topical Tretinoin

A. KATSAMBAS,¹ K. GRAUPE² and J. STRATIGOS¹

¹Department of Dermatology and Venereology, Medical School, University of Athens, A. Sygros Hospital, Greece, and ²Department of Dermatology, Clinical Research Division, Schering AG, Berlin

20% azelaic acid cream was compared clinically with its vehicle in a 3-month double-blind study of 92 patients with moderate inflammatory acne. In a single-blind study of 289 patients with comedonal acne, the topical azelaic acid preparation was compared with 0.05% tretinoin cream over a period of 6 months. In both controlled studies, 20% azelaic acid cream significantly reduced the number of acne lesions and yielded clinically relevant improvement rates. Azelaic acid cream was significantly and substantially more effective than its vehicle, indicating that the dicarboxylic acid itself is an active drug in acne treatment. In the study of comedonal acne, 20% azelaic acid cream was equally effective as 0.05% tretinoin cream in reducing the number of comedones and with respect to overall response. However, azelaic acid cream was better tolerated, causing fewer local side effects than the topical retinoid.

INTRODUCTION

Current management of acne comprises various topical and systemic drugs, including benzoylperoxide, antibiotics and retinoids. However, despite the established therapeutic efficacy of these drugs, recurrences with acne are nevertheless frequently encountered due to the chronic nature of the disease. Thus repeated, long-term courses of treatment may be required, which emphasizes the need for therapy safety.

Azelaic acid (AA) is a C-9 dicarboxylic acid which has been reported to be neither toxic nor teratogenic (1) and which in an open study was shown to be of therapeutic benefit in acne (2).

Azelaic acid is an antibacterial agent (3). This has prompted the clinical comparison of topical azelaic acid with oral tetracycline in inflammatory acne (4). Recent data suggest that AA also hinders directly the pathological hornification process in acne (5, 6).

The purpose of our two controlled studies was to answer the following questions:

1. Is azelaic acid indeed an active drug in acne therapy, i.e., is a 20% AA cream clinically superior to its vehicle?
2. How effective is AA cream against comedonal acne, e.g. as compared with topical tretinoin?

MATERIAL AND METHODS

Azelaic acid vs. vehicle ('placebo')

92 patients with papulo-pustular acne (degree II/III of Plewig-Kligmann) were enrolled in a 3-month, double-blind study (Table I). The papulo-pustular type of acne was characterized by a clinical predominance of small inflamed lesions. A few non-inflamed lesions, i.e. open and closed comedones, were almost invariably present. Patients with multiple large nodules, cysts and draining sinuses were not admitted.

Allocation to treatment with 20% azelaic acid cream ($n=43$; cream provided by Schering AG, West Berlin) or with the cream base ($n=49$; vehicle, 'placebo') was random. Following a wash-out period of 2-4 weeks the topical preparations were applied liberally twice daily to the affected areas. No additional therapy for acne was permitted during the study period.

Azelaic acid vs. tretinoin

In the second investigation 20% azelaic acid cream was compared with 0.05% tretinoin cream (Airof®, Hoffmann-La Roche, Basle, Switzerland). 289 patients with comedonal acne were enrolled in this (multicentre) study (Table I). The patients were randomly assigned to treatments and were instructed to apply the creams once a day for the first 2 weeks, then twice daily. The wash-out period was 2-4 weeks. No treatment for acne other than the study preparations was permitted.

In both studies a clinical assessment was made at the beginning of the study and then at monthly intervals. The number of inflamed lesions (papules, pustules) and the number of non-inflamed lesions (closed and open comedones) were counted. Side effects were recorded at each visit.

RESULTS

87% of the patients completed the 3-month vehicle-controlled study. 5 patients in the AA group and 3 in the vehicle group discontinued treatment due to local

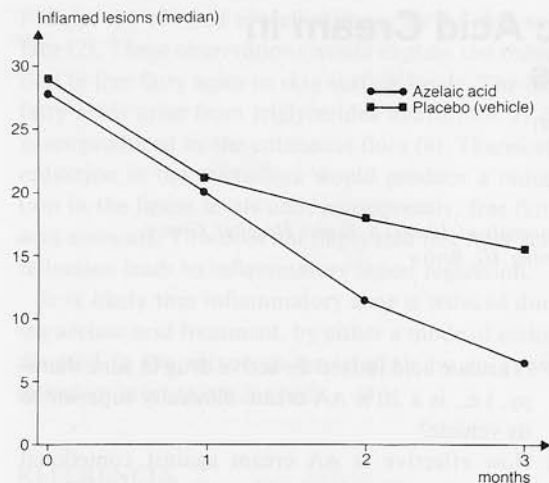


Fig. 1. 20% AA cream vs. vehicle: effect of therapy on the median number of inflamed lesions (papules and pustules) during the 3-month study period.

irritant effects; 2 patients in each group stopped treatment because of insufficient efficacy.

With respect to the median number of inflamed lesions (Fig. 1) significant differences between the two treatment groups were observed after 2 and 3 months (Mann-Whitney U-test, $\alpha=0.05$). After 3 months a reduction of the initial median count by 72% was found in the AA group, while in the vehicle group a reduction by 47% was noted. Pustules responded slightly better than papules. However, for both types of lesion the effect of the AA cream was significantly greater than that of the vehicle alone.

When considering the median reduction rate of comedones (Fig. 2), significant differences, in favour of AA cream, were observed at all visits (Mann-Whitney U-test, $\alpha=0.05$). After 3 months the median reduction rate was 55.6% in the AA group and 0% in the vehicle group. However, the result in the vehicle group does not indicate a general lack of effect on the comedones, but arises due to the fact that the poor reduction rates found in 57% of the patients are coun-

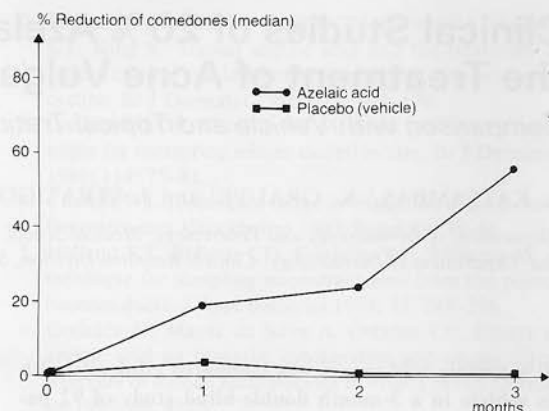


Fig. 2. 20% AA cream vs. vehicle: effect of therapy on the median reduction rates of comedones (in %) during the 3-month study period.

terbalanced by moderate to excellent reduction rates in the remaining 43% of the patients. In contrast, 75% of the patients using AA cream had moderate to excellent reduction rates of their initial comedone count.

With regard to overall evaluation, as determined from the reduction in total lesion counts, 64% of the AA patients completing the study had a good to excellent improvement (a reduction of the initial total lesion count by 75–100% was regarded as an excellent response, 50–75% reduction as a good response, and 25–50% as a moderate response). This result differed significantly from the 36% achieved in the vehicle group (Fisher's exact test, $\alpha=0.05$).

It should be emphasized that, as was observed in the second study, major improvement with AA cream is achieved after 4 months of therapy. However, for ethical reasons the placebo study was not conducted for longer than 3 months. It is likewise noteworthy that the vehicle, i.e. the cream base of the AA cream, yields an overall result better than the 25% customarily anticipated for a placebo.

In the study of comedonal acne, 71% of the pa-

Table I. Demographic patient data

	AA	Vehicle	AA	Tretinoin
Number of patients	43	49	143	146
Sex (M/F)	17/26	10/39	71/72	66/80
Median age (range)	19 y (13–27)	19 y (14–34)	18 y (12–38)	17 y (11–47)
Previous duration of acne		2.2 years	2 years	2 years
Previously treated	74.4%	73.5%	64.3%	66%

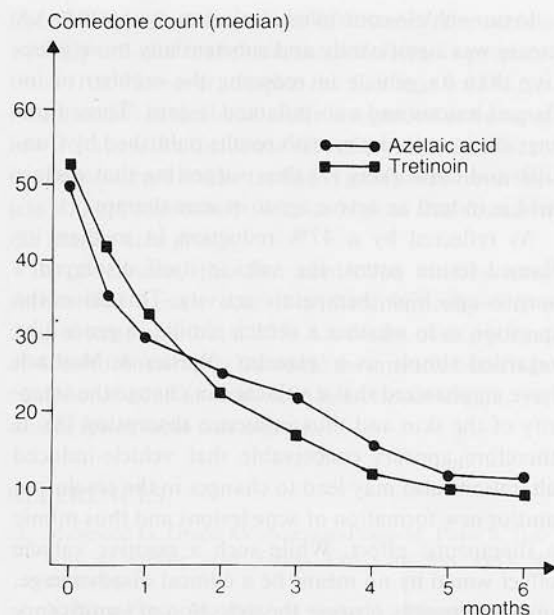


Fig. 3. 20% AA cream vs. 0.05% tretinoin cream: effect of therapy on the median number of comedones (open plus closed) during the 6-month study period.

tients completed the full 6-month course of treatment. With respect to the non-inflamed lesions, i.e. open and closed comedones, time course and the magnitude of response were both similar in the two treatment groups (Fig. 3).

Both topical preparations significantly reduced the initial comedone counts. The major reduction in comedone counts was achieved after 4 months of therapy; during months 5–6 only small additional changes were observed. Globally, i.e. including the drop-outs, 65% of the AA patients and 69% of the patients on tretinoin had a good to excellent reduction of their comedones (75–100% reduction of initial comedone count: excellent; 50–75% reduction: good; 25–50% reduction: moderate, less than 25% reduction: poor). For both variables, no significant differences between treatments were found (Mann-Whitney U-test and χ^2 -test, respectively; $\alpha=0.05$).

The time-response curves for the total lesion counts (Fig. 4) were similar to those of the non-inflamed lesions, since only a small number of papules and pustules were seen in the enrolled patients. Again no significant difference between the groups was noted (Mann-Whitney U-test; $\alpha=0.05$).

By subjective overall evaluation altogether 59% of

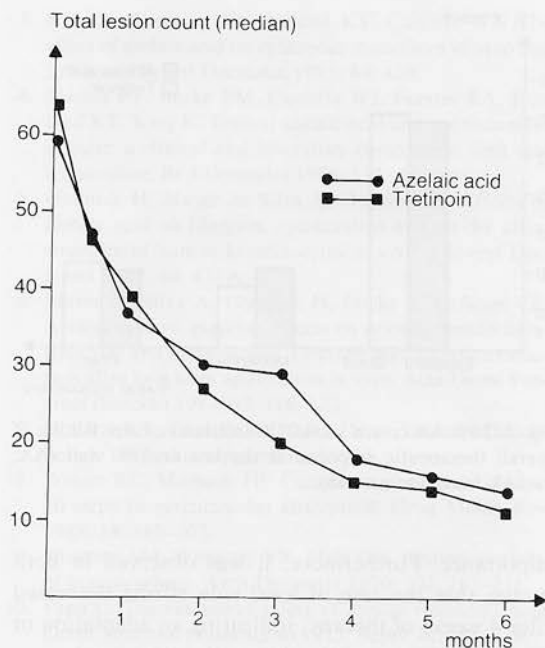


Fig. 4. 20% AA cream vs. 0.05% tretinoin cream: effect of therapy on the median number of the sum of lesions during the 6-month study period.

the patients in the AA group and 62% of those in the tretinoin group were rated good to excellent (Fig. 5). A significant difference between the groups was found at the second months' visit, though at none of the other control examinations. Of those patients who actually completed the full course of treatment with AA cream, 70% had good to excellent overall responses, 18% had a moderate overall response, while in the remaining patients the response was poor.

With regard to side effects, only local irritant reactions were encountered during the use of AA cream. No allergic reactions were seen.

In most cases the local side effects of AA cream were mild and transient and only of minor clinical

Table II. 20% AA cream vs. vehicle: number of patients with pronounced local side effects

	AA	Cream	Vehicle
Burning	4	(9.3%)	1 (2%)
Itching	2	(4.7%)	–
Scaling	1	(2.3%)	2 (4.7%)
Erythema	2	(4.7%)	1 (2%)

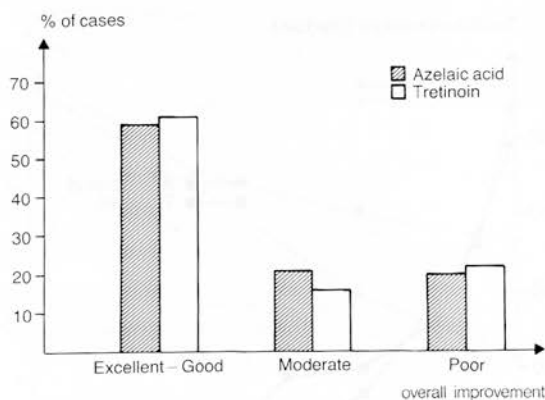


Fig. 5. 20% AA cream vs. 0.05% tretinoin cream: Rating of overall therapeutic response at the last control visit (AA: $n=143$, tretinoin: $n=146$).

importance. Furthermore, it was observed in both studies that the rate of local side effects decreased after 4 weeks of therapy, indicating an adaptation or hardening process of the skin to the AA cream.

The incidence rate of pronounced local side effects was low (Table II). However, burning sensations were found in a considerably higher rate in the AA group (9.3%) than in the vehicle group (2%). This may indicate a direct effect of the dicarboxylic acid. On the other hand, in the study of comedonal acne, marked burning was reported by 9.6% (14 cases) of the patients using tretinoin and in only 7.7% (11 cases) on AA treatment.

With respect to erythema and scaling, the rate of side effects was considerably higher in the tretinoin group than in the AA group. Thus a persistent erythema was noted in 27.4% of the patients receiving tretinoin and in 17.5% of the AA patients, while persistent scaling was reported in 28.8% and 16.8% of the cases, respectively. In the comparison of AA with tretinoin side effects were only classified as either transient or persistent. A comparison of these side effect rates with those from the vehicle-controlled study is thus difficult.

Local irritant reactions led to discontinuation in 6.3% of the AA patients (9 cases) and in 9.6% of the patients on tretinoin (14 cases).

DISCUSSION

Drug placebo effects and spontaneous improvement are well known phenomena in acne and must be taken into consideration in the evaluation of the therapeutic efficacy of any anti-acne preparation.

In our vehicle-controlled clinical study the 20% AA cream was significantly and substantially more effective than its vehicle in reducing the number of inflamed lesions and non-inflamed lesions. These findings are in accordance with results published by Cunliffe and co-workers (7) thus suggesting that azelaic acid is indeed an active agent in acne therapy.

As reflected by a 47% reduction in median inflamed lesion count, the vehicle itself displayed a surprisingly high therapeutic activity. This raises the question as to whether a vehicle should in general be regarded simply as a 'placebo'. Wester & Maibach have emphasized that a vehicle can change the integrity of the skin and thus influence absorption (8). It therefore appears conceivable that vehicle-induced alterations also may lead to changes in the resolution and/or new formation of acne lesions and thus mimic a therapeutic effect. While such a positive vehicle effect would by no means be a clinical disadvantage, it could possibly obscure the detection of significance in the difference between an active preparation and its vehicle.

In the study of comedonal acne, the 20% AA cream significantly and rapidly reduced the number of comedones, the median rate of reduction being approx. 40% after 1 month and 70% after 4 months. The rapid initial reduction of the non-inflamed lesions is not readily accounted for by the known antibacterial properties of the dicarboxylic acid (3), since by an indirect effect, i.e. the prevention of new formation of comedones, one would expect a reduction of comedone counts only after several months of treatment (9). Recent investigations (5, 6) suggest that azelaic acid, by affecting filaggrin expression, may interfere with the disordered keratinization in the infundibulum and thus exert a direct effect on the comedo. Although this mechanism differs essentially from the alterations in corneocyte adhesion induced by tretinoin, clinically both the time course and magnitude of response were very similar in the AA group and in the tretinoin group. The difference with respect to subjective overall judgement found after the second month, which might indicate a more rapid intermediate effect of tretinoin, should not be overestimated, since both trial preparations effected the major reduction in comedone counts, but after 4 months of treatment.

With regard to side effects it should be emphasized that no systemic adverse reactions, e.g. allergic sensitization, were observed after the use of AA cream. The irritant properties of tretinoin, e.g. causing excessive erythema and scaling, are well known. As out-

lined by Papa in a rank order of irritancy, the vehicle strongly influences the tolerance of tretinoin preparations (10). However, despite the fact that 0.05% tretinoin cream in this rank order is regarded as being of low irritancy, the incidence rate of erythema and scaling encountered in the tretinoin group was nevertheless still approximately twice as high as that found in the azelaic acid group.

In conclusion, the two controlled studies have shown that azelaic acid is a therapeutically active drug in acne and that a 20% AA cream over a period of 4–6 months affords the same therapeutic benefit in comedonal acne as does 0.05% tretinoin cream, yet causes fewer local side effects.

REFERENCES

- Mingrone G, Greco AV, Nazzaro-Porro M, Passi S. Toxicity of azelaic acid. *Drugs Exp Clin Res* 1983; 9: 447–455.
- Nazzaro-Porro M, Passi S, Balus L, Breathnach AS, Clayton R, Zina G. Beneficial effect of 15% azelaic acid cream on acne vulgaris. *Br J Dermatol* 1983; 109: 45–48.
- King K, Leeming JP, Holland KT, Cunliffe WJ. The effect of azelaic acid on cutaneous microflora in vivo and in vitro. *J Invest Dermatol* 1985; 84: 438.
- Bladon PT, Burke BM, Cunliffe WJ, Forster RA, Holland KT, King K. Topical azelaic acid and the treatment of acne: a clinical and laboratory comparison with oral tetracycline. *Br J Dermatol* 1986; 114: 493–499.
- Gollnick H, Mayer da Silva A, Orfanos LE. Effects of azelaic acid on filaggrin, cytokeratins and on the ultrastructure of human keratinocytes in vivo. *J Invest Dermatol* 1987; 89: 452A.
- Mayer da Silva A, Gollnick H, Imcke E, Orfanos CE. Azelaic acid vs. placebo: effects on normal human keratinocytes and melanocytes. Electron microscopic evaluation after long term application in vivo. *Acta Derm Venereol (Stockh)* 1987; 67: 116–122.
- Holland KT, Cunliffe WJ. *Acta Derm Venereol (Stockholm)*: 1989; this supplement: 31–34.
- Wester RC, Maibach HI. Cutaneous pharmacokinetics: 10 steps to percutaneous absorption. *Drug Metab Rev* 1983; 14: 169–205.
- Kligman AM, Wheatley VR, Mills OH. Comedogenicity of human sebum. *Arch Dermatol* 1970; 102: 267–275.
- Papa C. The cutaneous safety of topical tretinoin. *Acta Derm Venereol (Stockholm)* 1975; Suppl 74: 133–134.