

# Clinical and Laboratory Studies on Treatment with 20% Azelaic Acid Cream for Acne

W. J. CUNLIFFE and K. T. HOLLAND<sup>1</sup>

Department of Dermatology, Leeds General Infirmary and St. James University Hospital, Leeds, and <sup>1</sup>Department of Microbiology, Leeds University, Leeds, Yorkshire, England

**In a series of investigations using 20% azelaic acid cream as a therapy for acne, it was found that the treatment, compared with its placebo, significantly reduced inflamed lesions after 1 month and non-inflamed lesions after 2 months. No changes in sebum excretion rate occurred, but a significant reduction, 15.9 to 10.5%, of free fatty acids of skin surface lipid was detected after 1 month. The follicular Micrococcaceae density was significantly reduced after 1 month, and after 2 months there was a significant reduction in follicular Propionibacterium spp density. The final reductions were 2500 and 44 fold, respectively.**

Azelaic acid, a naturally occurring dicarboxylic acid, proved effective for acne treatment in an open study with 100 patients (1). In a later investigation on 23 patients, these results were confirmed, and a 224-fold and 30-fold reduction in skin surface Micrococcaceae and Propionibacterium spp, respectively, was noted (2). At present, it is not known how azelaic acid exerts its effect in the treatment of acne. Several factors have been considered of importance in the aetiology of acne: sebum excretion rate, free fatty acid content of the sebum, comedogenic factors, and follicular microflora. The present investigation was concerned with firstly, for the first time, comparing azelaic acid with placebo therapy for acne and, secondly, determining whether azelaic acid affects sebum excretion rate, skin surface lipid free fatty acid content and the follicular microfloral density.

## MATERIALS AND METHODS

All patients were untreated for at least 1 month before entering any of the investigations.

### *Clinical study*

Twenty matched pairs of patients were used in a controlled, double-blind trial of 20% azelaic acid cream and its base, applied twice daily over a period of 3 months, together with a wash 'Dermo mild'. Before starting treatment the 26 male and 14 female patients were counted for inflamed (I) and

non-inflamed lesions (N) and the acne grade (G) was assessed. A score (S) was computed according to the formula

$$S = N/2 + I/3 + G/30$$

S was used to rank the patients and, then, they were matched by the least sum of squares differences of S for the individuals. After matching, the patients were allocated to use either 20% azelaic acid cream, or its vehicle. Allocation was randomized (FORTRAN 77 RANDT program). All patients returned for clinical assessment at 1, 2 and 3 months during treatment. Also, side effects were assessed on a scale 0 (none) to 5 (severe) for scaling and erythema and no, mild, and severe for burning, stinging, and itching sensations. The results for the lesion counts, expressed as percentage change vis-à-vis the pre-treatment level, were analysed by the Wilcoxon Sum Rank Test.

### *Sebum excretion rate study*

Two separate investigations were carried out, 10 patients in each, acne grade 1-2, with treatment for 2 months using 20% azelaic acid cream twice daily. Sebum excretion rates were determined for each patient, before and after 1 and 2 months treatment (3). The results were expressed as  $\mu\text{g cm}^{-2} \text{min}^{-1}$  and were analysed by Student's *t*-test.

### *Skin surface free fatty acid study*

Ten patients, acne grades 1-2, were treated with 20% azelaic acid cream for 1 month, twice daily. Samples of skin surface lipid were taken pre-treatment and after 1 month treatment. These were assayed for content of free fatty acid (4). The results were expressed as percentage free fatty acid of the skin surface lipid, and were analysed by Student's *t*-test.

### *Microbiological study*

Nine patients, acne grade 0.6-3.0, entered the study and received 20% azelaic acid cream twice daily for 2 months. Samples from the forehead for microbiological analysis were taken by the cyanoacrylate glue follicular sampling method (5), and were processed for counting of Micrococcaceae and Propionibacterium spp. The results were expressed as  $\log_{10}$  CFU  $\text{cm}^{-2}$  skin. Only series of results from patients who had at least  $3.9 \log_{10}$  CFU  $\text{cm}^{-2}$  skin for either of the two bacterial groups at pre-treatment were used for analysis. Analysis of results was by the Wilcoxon Sum Rank Test.

## RESULTS

### *Clinical study*

The results for the percentage change in the number of lesions during treatment are shown in Fig. 1 for

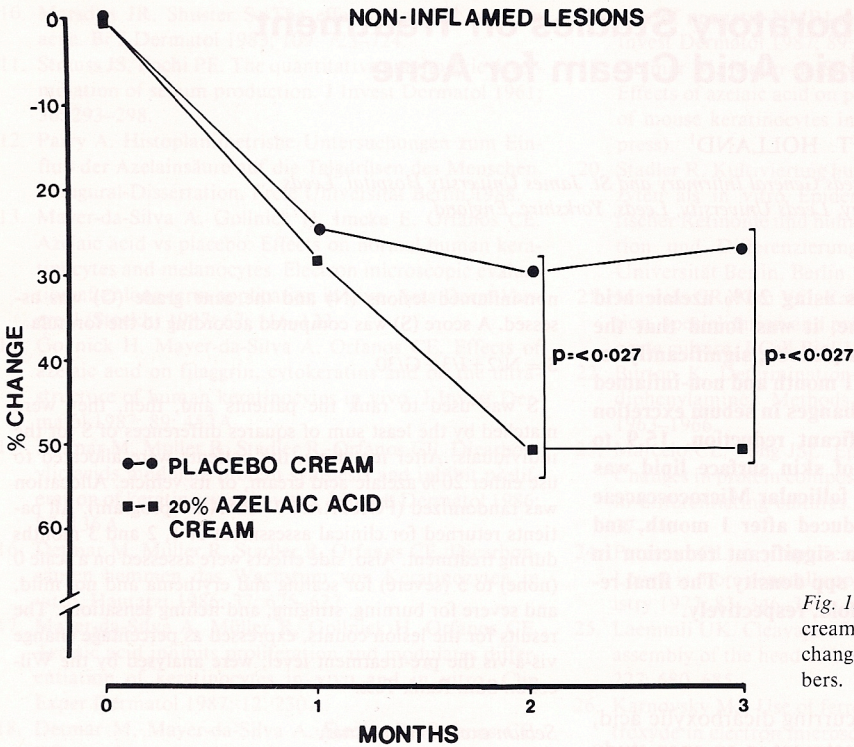


Fig. 1. The effect of 20% azelaic acid cream and its vehicle on percentage changes in non-inflamed lesion numbers.

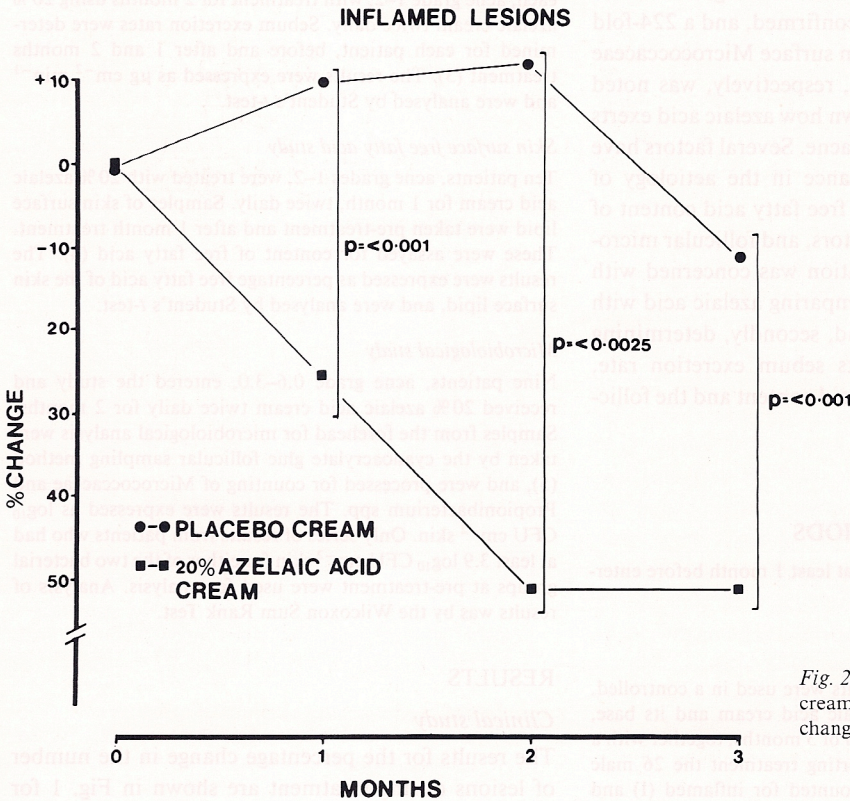


Fig. 2. The effect of 20% azelaic acid cream and its vehicle on percentage changes in inflamed lesion numbers.

Table I. Effect of 20% azelaic acid cream on mean sebum excretion rate of 10 patients in each of two independent investigations, A and B

Values expressed in  $\mu\text{g cm}^{-2} \text{min}^{-1} \pm \text{SD}$

	Investigation	
	A	B
Control	1.26 $\pm$ 0.15	0.89 $\pm$ 0.28
Month 1	1.14 $\pm$ 0.21	0.84 $\pm$ 0.57
Month 2	1.13 $\pm$ 0.17	0.92 $\pm$ 0.62

non-inflamed and Fig. 2 for inflamed lesions. After one month's treatment there was no significant difference in non-inflamed lesion reduction between patients using azelaic acid and those using placebo. However, after 2 and 3 months of treatment, azelaic acid showed a significant effect. Also, by the end of the study, 11 of the azelaic acid treated patients had a reduction of non-inflamed lesions of 50% or more, compared with only 4 using the placebo.

Similar results were obtained for inflamed lesions, except that the benefit of the azelaic acid treatment, vis-à-vis the placebo, was observed by one month, as well as by the second and third month of treatment. Ten azelaic acid treated patients had at least a 50% reduction in inflamed lesions by the end of the study, whilst only 1 patient using the placebo achieved the same level of improvement.

Side effects of treatments were transient, with scaling, erythema and burning noted in 5% of patients in both treatment groups. This frequency was observed in the placebo group for itching and stinging, but was twice this value for the azelaic acid treated patients.

#### Sebum excretion rate studies

The results for both independent investigations are given in Table I. No significant differences were found between pre-treatment rates and those during treatment.

#### Skin surface free fatty acid study

The mean percentage free fatty acid in skin surface lipid of 10 patients was 15.9 before treatment and was significantly reduced ( $p=0.01$ ) after 1 month of treatment, to 10.5%.

#### Microbiological study

The results are shown in Table II. After 1 and 2 months of treatment the follicular *Micrococcaceae*

were reduced significantly compared with the pre-treatment levels, and after 2 months of treatment the reduction was about 2500-fold. Compared with the pre-treatment levels, the follicular *Propionibacterium* spp densities were not reduced after 1 month of treatment, but were so after a further one month of treatment. This was a 44-fold reduction.

#### DISCUSSION

This clinical double-blind trial has demonstrated the efficacy of 20% azelaic acid cream, compared with its placebo cream base, for the treatment of mild to moderate acne. The treatment reduced both inflamed and non-inflamed lesions, and a significant reduction of inflamed lesions occurred before that of non-inflamed lesions. At present, this cannot be explained, as the mode of action of azelaic acid in acne treatment has not yet been determined. No changes in sebum excretion rate were observed—hence azelaic acid does not modify sebaceous gland activity. However, it is known that azelaic acid alters comedogenesis by affecting keratohyalin (6). This action may explain the reduction in non-inflamed lesions, and to some extent the reduction in inflamed lesions, since some inflamed lesions arise from non-inflamed types (7). However, since the reduction in inflamed lesions occurred before that of non-inflamed lesions, azelaic acid must have some other mechanism, apart from modifying comedogenesis.

These studies have confirmed that azelaic acid reduces the cutaneous bacterial flora, and has established that those bacteria located in the pilosebaceous

Table II. Effect of 20% azelaic acid cream on density of follicular bacteria

Time weeks	Micrococcaceae geometric mean
0	4.6933
4	1.8033
8	1.2850
Propionibacterium geometric mean	
0	5.6457
4	4.7029
8	4.0063

follicles are affected as well as those on the skin surface (2). These observations would explain the reduction in free fatty acids in skin surface lipids. The free fatty acids arise from triglycerides hydrolysed by lipases produced by the cutaneous flora (8). Therefore, reduction in the microflora would produce a reduction in the lipase levels and, consequently, free fatty acid amounts. This does not imply that free fatty acid reduction leads to inflammatory lesion regression.

It is likely that inflammatory acne is reduced during azelaic acid treatment, by either a mode of action directed to the cutaneous bacteria, or by an as yet unknown mechanism, or both.

REFERENCES

1. Nazzaro-Porro M, Passi S, Picardo M, Breathnach A, Clayton R, Zina G. Beneficial effect of 15% azelaic acid cream on acne vulgaris. *Br J Dermatol* 1983; 109: 45-48.

2. Bladon PT, Burke BM, Cunliffe WJ, Forster RA, Holland KT, King K. Topical azelaic acid and the treatment of acne: a clinical and laboratory comparison with oral tetracycline. *Br J Dermatol* 1986; 114: 493-499.

3. Lookingbill DP, Cunliffe WJ. A direct gravimetric technique for measuring sebum excretion rate. *Br J Dermatol* 1986; 114: 75-81.

4. Cunliffe WJ. Techniques in the investigation of acne. *Acta Dermatovener (Stockholm)* 1980; Suppl 89: 39-46.

5. Holland KT, Roberts CD, Cunliffe WJ, Williams M. A technique for sampling microorganisms from the pilosebaceous ducts. *J Appl Bacteriol* 1974; 37: 289-296.

6. Gollnick H, Mayer da Silva A, Orfanos CE. Effects of azelaic acid on filaggrin, cytokeratins and on the ultrastructure of human keratinocytes in vivo. *J Invest Dermatol* 1987; 89: 452A.

7. Kligman AM. An overview of acne. *J Invest Dermatol* 1974; 62: 268-287.

8. Marples RR, Downing DT, Kligman AM. Control of free fatty acids in human skin surface lipids by *Corynebacterium* acnes. *J Invest Dermatol* 1971; 56: 127-131.