

Alagille Syndrome

A Case Report

VIBHA NIGALE, S.S. TRASI, U.S. KHOPKAR, S. L. WADHWA and N. J. NADKARNI*

Department of Dermatology, Venereology and Leprology, B. Y. L. Nair Hospital and T. N. Medical College, Bombay, India

A 5-year-old physically and mentally retarded female child born of non-consanguineous parents, who had had disseminated skin lesions for 4½ years, is presented. She had persistent neonatal jaundice associ-

ated with clay-coloured stools and generalized pruritus which receded by the age of 2 years. Examination revealed characteristic facies, moderate hepatosplenomegaly, cardiac murmur and widespread smooth yellow papules and nodules on ears, trunk, bony prominences and palms. Ophthalmic examination revealed corneal opacities. Liver function tests and lipidogram were abnormal. A diagnosis of Watson-Alagille Syndrome was made on the basis of character-

*Former Lecturer, Dept. of Dermatology, T. N. Medical College.

istic facies, xanthomatosis and cholestatic jaundice.**Key words:** *Xanthomas; Intrahepatic cholestasis.*

(Accepted April 9, 1990.)

Acta Derm Venereol (Stockh) 1990; 90: 521-523.

V. Nigale, 502, SB1/54, Yashodham, Dindoshi, Goregaon (E), Bombay 400063, India.

Arterio-hepatic dysplasia, Watson-Alagille Syndrome is now recognised as a major cause of intrahepatic cholestasis in infancy (1). Affected individuals have a characteristic facies and variable number of other anomalies including peripheral or valvular pulmonic stenosis, bone involvement, hypogonadism and mental retardation.

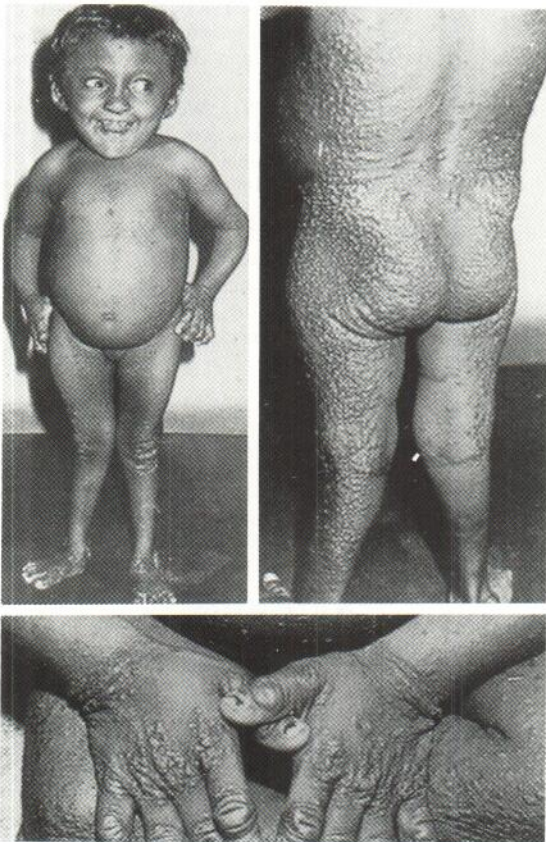


Fig. 1. Clinical picture showing stunted growth, generalized xanthomas and diagnostic triangular face with beaked nose, pointed chin and hypertelorism.

Fig. 2. Posterior view, showing multiple xanthomas.

Fig. 3. Xanthomatous lesions on knuckles.

CASE REPORT

A 5-year-old female child of healthy non-consanguineous parents was brought to our skin department with disseminated progressive skin lesions since the age of 6 months. She had neonatal jaundice which gradually increased in severity and was associated with clay-coloured stools in the initial phase. The jaundice receded by the age of 2 years but accompanying pruritus persisted. The cutaneous lesions started on knuckles and legs and progressed to involve the face and trunk.

On examination, the child had stunted growth with bowing of extremities and short phalanges. Her face was very characteristic. It was brachycephalic, triangular in shape with pointed chin, beaked nose and hypertelorism. She had moderate hepatosplenomegaly. There was mesosystolic murmur in parasternal area. The cutaneous lesions were smooth, yellow, non-tender papules and nodules on ear rims, retro-auricular areas, abdomen, back, buttocks, bony prominences and palms (Figs. 1-3). The ophthalmic examination revealed macular and nebular corneal opacities with pale optic disc.

H & E staining of skin biopsy showed foamy histiocytes and Sudan III stained the section deep red, indicating the presence of lipid. The radiological findings were generalized osteoporosis with bowing of long bones and short phalanges. The vertebral column was normal. The biochemical investigations revealed abnormal liver function tests and lipidogram. Liver scan did not show evidence of cirrhosis but liver biopsy was pathognomonic. It showed preserved lobular pattern but too few and inconspicuous portal tracts. A single sizable tract was visualized which showed mild to moderate fibrosis, minimal infiltrate and a few ductular cells without any well-formed bile ducts. Liver parenchyma was degenerated at places, indicating intrahepatic cholestasis. Thus the liver biopsy confirmed the clinical diagnosis of a rare syndrome, "arterio-hepatic dysplasia".

The child was recommended a fat-free diet with supplements of vitamin A and D. She was followed up for 3 years but her general condition deteriorated and she succumbed in 1986.

DISCUSSION

Arterio-hepatic dysplasia is a rare syndrome with multisystem involvement. The incidence of this syndrome is 1 : 100,000 live births, with male preponderance (2). It is genetically transmitted as an autosomal dominant trait with incomplete penetrance (1). The possibility of a gene for this syndrome on chromosome 20 was raised by Byrne et al. (3).

A new syndrome with pulmonary artery stenosis and neonatal liver disease was documented by Watson & Miller in 1973 (4). Unknown to them, Alagille et al. (5) had become aware of this combination of anomalies as early as 1956 with evidence of hepatic ductular hypoplasia. Watson & Miller reported a

series of 21 cases with congenital pulmonary stenosis with cardiovascular malformations, neonatal liver disease with obstructive jaundice resembling biliary atresia or hepatitis and various minor congenital anomalies including odd facies. However, xanthomas were reported in only one case (4).

Alagille reported his series in the French literature in 1969, subsequently in English in 1975. He has studied and followed up 30 cases over the period of 15 years. The details outlined by him are chronic cholestasis, characteristic facies, mesosystolic murmur, vertebral arch defects, physical and mental retardation with hypogonadism. He also stressed the rarity of xanthomas and their pathognomy when distributed on extensors, body creases and palms. He did not state the number of patients with xanthomatosis in his series (5).

Other features of the syndrome include, in the eye, posterior embryotoxon, retinal pigmentary changes and anterior chamber anomalies, butterfly vertebrae, ataxia and areflexia (3).

Our patient had a few interesting unusual fea-

tures, viz. macular and nebular corneal opacities and generalized osteoporosis, which have not been reported previously.

REFERENCES

1. Sherlock S. Intrahepatic cholestasis. In: Diseases of liver and biliary system, 7th edn. Bombay: Oxford University Press, 1986: 412.
2. Valencia-Mayoral P, Weber J, Cutz E, et al. Possible defect in the bile secretory apparatus in arterio-hepatic dysplasia (Alagille Syndrome). A review with observations on the ultrastructure of liver. *Hepatology* 1984; 4: 691-698.
3. McKusick VA. Mendelian Inheritance in Man. 8th edn. Baltimore, USA: Johns Hopkins University Press, 1988; No. 11845.
4. Watson GH, Miller V. Arterio-hepatic dysplasia: familial pulmonary artery stenosis with neonatal liver disease. *Arch Dis Child* 1973; 48: 459-466.
5. Alagille D, Odievre M, Gautrier M, et al. Hepatic ductular hypoplasia associated with characteristic facies, vertebral malformations, retarded physical, mental and sexual development and cardiac murmur. *J Paediatr* 1975; 86: 63-71.